National Comprehensive Cancer Network®

NCCN Clinical Practice Guidelines in Oncology (NCCN Guidelines®)

Hepatocellular Carcinoma

Version 2.2025 — October 22, 2025

NCCN.org

NCCN recognizes the importance of clinical trials and encourages participation when applicable and available. Trials should be designed to maximize inclusiveness and broad representative enrollment.

NCCN Guidelines for Patients® available at www.nccn.org/patients

Continue

Version 2.2025, 10/22/25 © 2025 National Comprehensive Cancer Network® (NCCN®), All rights reserved. NCCN Guidelines® and this illustration may not be reproduced in any form without the express written permission of NCCN.

PLEASE NOTE that use of this NCCN Content is governed by the End-User License Agreement, and you MAY NOT distribute this Content or use it with any artificial intelligence model or tool.
Printed by Galya Basol Kochav on 1/5/2026 10:54:24 AM. Copyright © 2026 National Comprehensive Cancer Network, Inc. All Rights Reserved.

***Al B. Benson, III, MD/Chair †**
Robert H. Lurie Comprehensive Cancer Center of Northwestern University

***Michael I. D'Angelica, MD/Vice-Chair ¶**
Memorial Sloan Kettering Cancer Center

Thomas Abrams, MD †
Dana-Farber/Brigham and Women's Cancer Center | Mass General Cancer Center

Aijaz Ahmed, MD ¤
Stanford Cancer Institute

Mehmet Akce, MD † ‡
O'Neal Comprehensive Cancer Center at UAB

Daniel A. Anaya, MD ¶
Moffitt Cancer Center

Robert Anders, MD, PhD ¤ ≠
Johns Hopkins Kimmel Cancer Center

Chandrakanth Are, MBBS, MBA ¶
Fred & Pamela Buffett Cancer Center

Lydia Aye, DO ¤ ξ
UC Davis Comprehensive Cancer Center

Melinda Bachini ¥
Cholangiocarcinoma Foundation

Marshall Baker, MD, MBA ¶
Huntsman Cancer Institute at the University of Utah

David Binder, MD §
University of Colorado Cancer Center

Daniel Brown, MD † ф
Vanderbilt-Ingram Cancer Center

Adam Burgoyne, MD, PhD †
UC San Diego Moores Cancer Center

Jason Castellanos, MD, MS ¶
Fox Chase Cancer Center

Saurin Chokshi, MD †
St. Jude Children's Research Hospital/The University of Tennessee Health Science Center

Jordan Cloyd, MD ¶
The Ohio State University Comprehensive Cancer Center - James Cancer Hospital and Solove Research Institute

Darren Cullinan, MD, MSCI ¶
Siteman Cancer Center at Barnes-Jewish Hospital and Washington University School of Medicine

Joseph Franses, MD, PhD †
The UChicago Medicine Comprehensive Cancer Center

Evan S. Glazer, MD, PhD ¶
St. Jude Children's Research Hospital/The University of Tennessee Health Science Center

William Harris, MD †
Fred Hutchinson Cancer Center

Renuka Iyer, MD Þ †
Roswell Park Comprehensive Cancer Center

Lawrence Jennings, MD, PhD ≠
Robert H. Lurie Comprehensive Cancer Center of Northwestern University

R. Kate Kelley, MD † ‡
UCSF Helen Diller Family Comprehensive Cancer Center

Sajid Khan, MD ¶
Yale Cancer Center/Smilow Cancer Hospital

Matthew Levine, MD, PhD ξ
Abramson Cancer Center at the University of Pennsylvania

Laleh Melstrom, MD, MS ¶
City of Hope National Medical Center

Manisha Palta, MD §
Duke Cancer Institute

Steven Raman, MD ф
UCLA Jonsson Comprehensive Cancer Center

Sean Ronnekleiv-Kelly, MD ¶
University of Wisconsin Carbone Cancer Center

Vaibhav Sahai, MBBS, MS †
University of Michigan Rogel Cancer Center

Stacey Stein, MD †
Yale Cancer Center/Smilow Cancer Hospital

Kevin Stephans, MD §
Case Comprehensive Cancer Center/ University Hospitals Seidman Cancer Center and Cleveland Clinic Taussig Cancer Institute

Kannan Thanikachalam, MD †
Roswell Park Comprehensive Cancer Center

Anita Turk, MD †
Indiana University Melvin and Bren Simon Comprehensive Cancer Center

Jean-Nicolas Vauthey, MD ¶
The University of Texas MD Anderson Cancer Center

Alan P. Venook, MD † ‡ Þ
UCSF Helen Diller Family Comprehensive Cancer Center

Motoyo Yano, MD, PhD ф
Mayo Clinic Comprehensive Cancer Center

Adam Yopp, MD ¶
UT Southwestern Simmons Comprehensive Cancer Center

Ken Zhao, MD ф
Memorial Sloan Kettering Cancer Center

NCCN
Cindy Hochstetler, PhD
Ryan Schonfeld, BA

ф Diagnostic/Interventional radiology
¤ Gastroenterology
‡ Hematology/Hematology oncology
Þ Internal medicine
† Medical oncology
≠ Pathology
¥ Patient advocacy
§ Radiotherapy/Radiation oncology
¶ Surgery/Surgical oncology
ξ Transplantation
* Discussion section writing committee

Continue

NCCN Guidelines Panel Disclosures

Version 2.2025, 10/22/25 © 2025 National Comprehensive Cancer Network® (NCCN®), All rights reserved. NCCN Guidelines® and this illustration may not be reproduced in any form without the express written permission of NCCN.

PLEASE NOTE that use of this NCCN Content is governed by the End-User License Agreement, and you MAY NOT distribute this Content or use it with any artificial intelligence model or tool.
Printed by Galya Basol Kochav on 1/5/2026 10:54:24 AM. Copyright © 2026 National Comprehensive Cancer Network, Inc. All Rights Reserved.

NCCN Guidelines Version 2.2025
Hepatocellular Carcinoma

NCCN Hepatocellular Carcinoma Panel Members
Summary of the Guidelines Updates

Hepatocellular Carcinoma (HCC)
- HCC Screening (HCC-1)
- Diagnosis of HCC (HCC-2)
- Clinical Presentation and Workup: HCC Confirmed (HCC-3)
- Potentially Resectable or Transplantable by Tumor Burden; and Operable by Performance Status or Comorbidity (HCC-4)
- Liver-confined, Unresectable, and Deemed Ineligible for Transplant (HCC-5)
- Extrahepatic/Metastatic Disease; and Deemed Ineligible for Resection, Transplant, or Locoregional Therapy (HCC-6)
- Principles of Imaging (HCC-A)
- Principles of Core Needle Biopsy (HCC-B)
- Principles of Mixed HCC-CCA (HCC-C)
- Principles of Pathology (HCC-D)
- Principles of Liver Functional Assessment (HCC-E)
- Principles of Resection and Transplant (HCC-F)
- Principles of Locoregional Therapy (HCC-G)
- Principles of Radiation Therapy (HCC-H)
- Principles of Systemic Therapy (HCC-I)
- Principles of Molecular Testing (HCC-J)
- AJCC Staging (ST-1)
- BCLC Staging (ST-2)

Abbreviations (ABBR-1)

Find an NCCN Member Institution: https://www.nccn.org/home/member-institutions.

NCCN Categories of Evidence and Consensus: All recommendations are category 2A unless otherwise indicated.

See NCCN Categories of Evidence and Consensus.

NCCN Categories of Preference: All recommendations are considered appropriate.

See NCCN Categories of Preference.

The NCCN Guidelines® are a statement of evidence and consensus of the authors regarding their views of currently accepted approaches to treatment. Any clinician seeking to apply or consult the NCCN Guidelines is expected to use independent medical judgment in the context of individual clinical circumstances to determine any patient's care or treatment. The National Comprehensive Cancer Network® (NCCN®) makes no representations or warranties of any kind regarding their content, use or application and disclaims any responsibility for their application or use in any way. The NCCN Guidelines are copyrighted by National Comprehensive Cancer Network®. All rights reserved. The NCCN Guidelines and the illustrations herein may not be reproduced in any form without the express written permission of NCCN. ©2025.

PLEASE NOTE that use of this NCCN Content is governed by the End-User License Agreement, and you MAY NOT distribute this Content or use it with any artificial intelligence model or tool.
Printed by Galya Basol Kochav on 1/5/2026 10:54:24 AM. Copyright © 2026 National Comprehensive Cancer Network, Inc. All Rights Reserved.

Updates in Version 2.2025 of the NCCN Guidelines for Hepatocellular Carcinoma from Version 1.2025 include:

MS-1
- The discussion was updated to reflect the changes in the algorithm.

Updates in Version 1.2025 of the NCCN Guidelines for Hepatocellular Carcinoma from Version 4.2024 include:

General
- Child-Pugh was changed to Child-Turcotte-Pugh throughout.
- Nonalcoholic fatty liver disease was changed to metabolic dysfunction-associated steatotic liver disease (MASLD) throughout.

HCC-1
- Column 1
  - Bullet 1, sub-bullet 3 revised: ~~Nonalcoholic~~ *Metabolic dysfunction associated* steatohepatitis.

HCC-2
- Imaging
  - Column revised: Abdominal multiphasic CT *(preferred)* or MRI *(preferred) or contrast-enhanced US.*

HCC-3
- Footnote t added: Multidisciplinary evaluation of HCC should include hepatologists, diagnostic and interventional radiologists, surgeons, medical oncologists, radiation oncologists, and pathologists with HCC expertise.
- Footnote removed: See NCCN Guidelines for Older Adult Oncology.

HCC-4
- Footnote revised: In patients being considered for surgery, patients with CTP Class A or highly selected patients with CTP Class B liver function, who fit UNOS criteria/extended criteria (www.unos.org) and are resectable could be considered for resection or transplant. ~~There is controversy over which initial strategy is preferable to treat such patients.~~ These patients should be evaluated by a multidisciplinary team *for individualized decision-making*.
- Footnote removed: Adjuvant therapy with atezolizumab + bevacizumab may be considered in patients at high risk for recurrence (defined as size >5 cm, >3 tumors, macrovascular invasion or microvessel invasion on histology, or grade 3/4 histology based on the trial) on a case by case basis. Interim analysis of the phase III study of adjuvant therapy with atezolizumab + bevacizumab for 12 months in patients at high risk for recurrence after resection or ablation showed a higher rate of recurrence-free survival at 12 months compared to active surveillance, though overall survival benefit has not been established. Qin S, et al. Lancet 2023;402:1835-1847. Atezolizumab and hyaluronidase-tqjs subcutaneous injection may be substituted for IV atezolizumab. Atezolizumab and hyaluronidase-tqjs has different dosing and administration instructions compared to atezolizumab for intravenous infusion. An FDA-approved biosimilar is an appropriate substitute for bevacizumab.

HCC-6
- Response assessment
  - Bullet 1 revised: Reconsider ~~resection, transplant,~~ locoregional therapy *and multidisciplinary review.*
- Footnote removed: Principles of Pathology (HCC-D).

HCC-A (1 of 3)
- Imaging Diagnosis of HCC
  - Bullet 1, 5th sentence revised: Major imaging features of HCC include *nonrim* arterial phase hyperenhancement, nonperipheral washout, enhancing capsule, and threshold growth.
  - Bullet 2, 1st sentence revised: Importantly, imaging criteria for parenchymal nodules apply only to patients at high risk for developing HCC: namely, those with cirrhosis *(with exceptions of patients with cirrhosis due to congenital hepatic fibrosis, vascular causes, or less than 18 years of age)*, CHB, or current or prior HCC.

Continued

Version 2.2025, 10/22/25 © 2025 National Comprehensive Cancer Network® (NCCN®), All rights reserved. NCCN Guidelines® and this illustration may not be reproduced in any form without the express written permission of NCCN.

PLEASE NOTE that use of this NCCN Content is governed by the End-User License Agreement, and you MAY NOT distribute this Content or use it with any artificial intelligence model or tool.
Printed by Galya Basol Kochav on 1/5/2026 10:54:24 AM. Copyright © 2026 National Comprehensive Cancer Network, Inc. All Rights Reserved.

Updates in Version 1.2025 of the NCCN Guidelines for Hepatocellular Carcinoma from Version 4.2024 include:

HCC-A (3 of 3)
- Reference 6 revised: ~~ACR. American College of Radiology (ACR) Liver Imaging Reporting and Data System (LI-RADS) v2017 2018 [cited 2018 May 28]. Available from: http://www.acr.org/Quality-Safety/Resources/LIRADS.~~ *American College of Radiology. Liver Imaging Reporting & Data System website. Available at: https://www.acr.org/Clinical-Resources/Clinical-Tools-and-Reference/Reporting-and-Data-Systems/LI-RADS. Accessed March 13, 2025.*

HCC-B
- Bullet 1, sub-bullet 1 revised: Lesion is highly suspicious for malignancy at multiphasic CT or MRI but does not meet imaging *features* ~~criteria~~ for HCC. *Multidisciplinary review at a center of expertise is recommended.*
- Bullet 1, sub-bullet 2 revised: Lesion meets imaging *features* ~~criteria~~ for HCC but:

HCC-C (1 of 2)
- Paragraph 3 revised: ~~Those identified as~~ *Patients with* HCC-CCA that ~~are~~ *is* limited ~~to Milan criteria~~ in size *based on center-specific criteria used* should be considered for evaluation in a transplant center. ~~but may need a research protocol or live donor approach to do so~~.

HCC-F
- Last bullet, last sentence revised: Minimally invasive approaches ~~in~~ *by* experienced *surgeons* ~~hands~~ have been proven to be safe and effective.
- Bullet removed: For appropriate patients, adjuvant therapy with atezolizumab + bevacizumab may be considered in patients at high risk for recurrence (defined as size >5 cm, >3 tumors, macrovascular invasion or microvessel invasion on histology, or grade 3/4 histology) on a case by case basis. Interim analysis of the phase III study of adjuvant therapy with atezolizumab + bevacizumab for 12 months in patients at high risk for recurrence after resection or ablation showed a higher rate of recurrence-free survival at 12 months compared to active surveillance, though overall survival benefit has not been established.
- Reference 2 added: Boubaddi M, Marichez A, Adam JP, et al. Comprehensive review of future liver remnant (FLR) assessment and hypertrophy techniques before major hepatectomy: how to assess and manage the FLR. Ann Surg Oncol 2024;31:9205-9220.
- Reference 3 added: Entezari P, Gabr A, Kennedy K, et al. Radiation lobectomy: An overview of concept and applications, technical considerations, outcomes. Semin Intervent Radiol 2021;38:419-424.
- Footnote removed: Atezolizumab and hyaluronidase-tqjs subcutaneous injection may be substituted for IV atezolizumab. Atezolizumab and hyaluronidase-tqjs has different dosing and administration instructions compared to atezolizumab for intravenous infusion.
- Footnote removed: An FDA-approved biosimilar is an appropriate substitute for bevacizumab.
- Reference removed: Brouquet A, Andreou A, Shindoh J, et al. Methods to improve resectability of hepatocellular carcinoma. Recent Results Cancer Res 2013;190:57-67.
- Reference removed: Qin S, Chen M, Cheng AL, et al. Atezolizumab plus bevacizumab versus active surveillance in patients with resected or ablated high-risk hepatocellular carcinoma (IMbrave050): a randomised, open-label, multicentre, phase 3 trial. Lancet 2023;402:1835-1847.

HCC-H (2 of 2)
- Reference 6 added: Dawson LA, Winter KA, Knox JJ, et al. NRG/RTOG 1112: Stereotactic body radiotherapy vs sorafenib alone in hepatocellular carcinoma: the NRG Oncology/RTOG 1112 phase 3 randomized clinical trial. JAMA Oncol 2025;11:136-144.

Continued

Version 2.2025, 10/22/25 © 2025 National Comprehensive Cancer Network® (NCCN®), All rights reserved. NCCN Guidelines® and this illustration may not be reproduced in any form without the express written permission of NCCN.

PLEASE NOTE that use of this NCCN Content is governed by the End-User License Agreement, and you MAY NOT distribute this Content or use it with any artificial intelligence model or tool.
Printed by Galya Basol Kochav on 1/5/2026 10:54:24 AM. Copyright © 2026 National Comprehensive Cancer Network, Inc. All Rights Reserved.

Updates in Version 1.2025 of the NCCN Guidelines for Hepatocellular Carcinoma from Version 4.2024 include:

HCC-I (1 of 2)
- First-Line Systemic Therapy
  - Other Recommended Regimens
    - Nivolumab + ipilimumab was added as a category 2A recommendation.
  - Useful in Certain Circumstances
    - "None" added.
    - Repotrectinib (category 2B) for *NTRK* gene-fusion positive tumors was removed.
- Subsequent-Line Systemic Therapy if Disease Progression
  - Options
    - Lenvatinib was removed.
    - Sorafenib was removed.
  - Other Recommended Regimens
    - Added: Consider Preferred and Other Recommended Regimens for First-Line Systemic Therapy above.
    - Nivolumab + ipilimumab was removed.
    - Pembrolizumab was removed.
  - Useful in Certain Circumstances
    - For *NTRK* gene-fusion positive tumors:
      - Entrectinib was added as a category 2A recommendation.
      - Larotrectinib was added as a category 2A recommendation.
      - Repotrectinib was added as a category 2A recommendation.
- Footnote a added: An FDA-approved biosimilar is an appropriate substitute for any recommended systemic biologic therapy in the NCCN Guidelines.
- Footnote h revised: *For patients who have not been previously treated with a checkpoint inhibitor when used as subsequent-line therapy because* there is a lack of data for subsequent use of single agent immunotherapy in patients who have previously been treated with a checkpoint inhibitor.
- Footnote i revised: For patients who have not been previously treated with *anti-CTLA4-based combinations when used as subsequent-line therapy* ~~a checkpoint inhibitor unless following atezolizumab + bevacizumab~~.
- Footnote k revised: Pembrolizumab is a recommended treatment option for patients with or without microsatellite instability-high (MSI-H) HCC. Pembrolizumab is FDA-approved for MSI-H tumors *in the subsequent-line setting*.
- Footnote l revised: *Regimens with first-line data are reasonable to consider for subsequent-line treatment, if not previously used.* There are no comparative data to define optimal treatment after first-line systemic therapy.
- Footnote p added: NTRK gene fusion-positive tumors are extremely rare in HCC.
- Footnote removed: An FDA-approved biosimilar is an appropriate substitute for bevacizumab.
- Footnote removed: For patients who have not been previously treated with a checkpoint inhibitor.
- Footnote removed: Larotrectinib and entrectinib are treatment options for patients with NTRK gene-fusion positive HCC. Repotrectinib (category 2B) is a treatment option for patients with NTRK gene-fusion positive HCC that has progressed on a prior NTRK-targeted treatment.

HCC-I (2 of 2)
- Reference 8 added: Galle PR, Decaens T, Kudo M, et al. Nivolumab (NIVO) plus ipilimumab (IPI) vs lenvatinib (LEN) or sorafenib (SOR) as first-line treatment for unresectable hepatocellular carcinoma (uHCC): First results from CheckMate 9DW [abstract]. J Clin Oncol 2024;24:Abstract LBA4008.

Version 2.2025, 10/22/25 © 2025 National Comprehensive Cancer Network® (NCCN®), All rights reserved. NCCN Guidelines® and this illustration may not be reproduced in any form without the express written permission of NCCN.

PLEASE NOTE that use of this NCCN Content is governed by the End-User License Agreement, and you MAY NOT distribute this Content or use it with any artificial intelligence model or tool.
Printed by Galya Basol Kochav on 1/5/2026 10:54:24 AM. Copyright © 2026 National Comprehensive Cancer Network, Inc. All Rights Reserved.

HEPATOCELLULAR CARCINOMA (HCC) SCREENING[a]

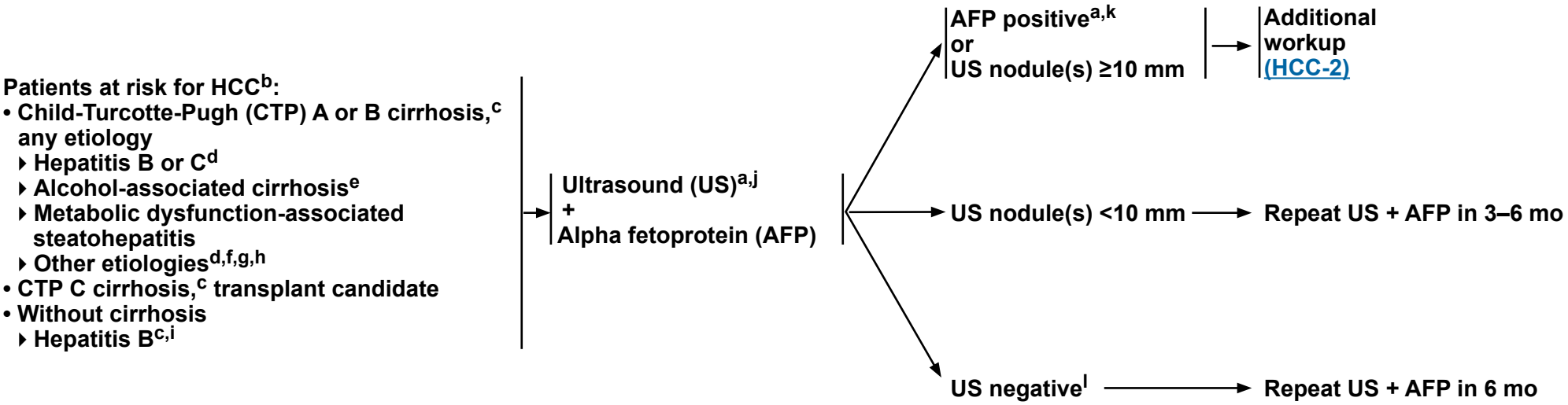

[a] Principles of Imaging (HCC-A).
[b] Adapted with permission from Singal AG, et al. Hepatology 2023;78:1922-1965.
[c] Patients with cirrhosis or chronic hepatitis B (CHB) viral infection should be enrolled in an HCC screening program (See Discussion).
[d] There is evidence suggesting improved outcomes for patients with HCC in the setting of metabolic dysfunction-associated steatotic liver disease (MASLD)/ hepatitis B virus (HBV)/ hepatitis C virus (HCV) cirrhosis when the MASLD/HBV/HCV is successfully treated. Referral to a hepatologist should be considered for the comprehensive care of these patients.
[e] Niazi SK, et al. J Natl Compr Canc Netw 2021;19:829-838.
[f] White DL, et al. Clin Gastroenterol Hepatol 2012;10:1342-1359.
[g] Beuers U, et al. Am J Gastroenterol 2015;110:1536-1538.
[h] Schiff ER, Maddrey WC, Reddy KR. Schiff's Diseases of the Liver, 12th ed. Wiley-Blackwell; 2017.
[i] Additional risk factors for these patients include platelet, age, and gender-HBV score ≥10; family history of HCC, man from endemic country >40 y, woman from endemic country age >50 y, and person from Africa at earlier age.
[j] Most clinical practice guidelines recommend US for HCC screening. US exams should be done by qualified sonographers or physicians. Liver dynamic CT or dynamic MRI may be performed as an alternative to US if US fails to detect nodules or if visualization is poor. Korean Liver Cancer Association (KLCA) and National Cancer Center (NCC) Korea. Clin Mol Hepatol 2022;28:583-705.
[k] Positive or rising AFP should prompt CT or MRI regardless of US results.
[l] US negative means no observation or only definitely benign observation(s).

Note: All recommendations are category 2A unless otherwise indicated.

Version 2.2025, 10/22/25 © 2025 National Comprehensive Cancer Network® (NCCN®), All rights reserved. NCCN Guidelines® and this illustration may not be reproduced in any form without the express written permission of NCCN.

PLEASE NOTE that use of this NCCN Content is governed by the End-User License Agreement, and you MAY NOT distribute this Content or use it with any artificial intelligence model or tool.
Printed by Galya Basol Kochav on 1/5/2026 10:54:24 AM. Copyright © 2026 National Comprehensive Cancer Network, Inc. All Rights Reserved.

DIAGNOSIS OF HCC[b]

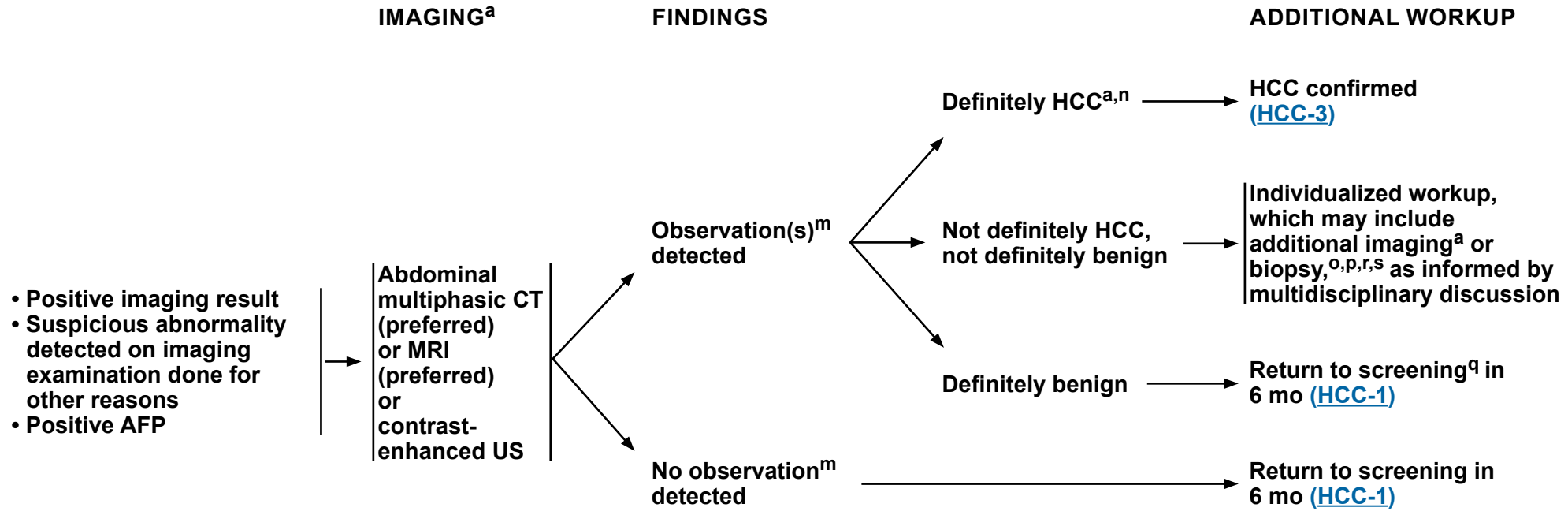

[a] Principles of Imaging (HCC-A).
[b] Adapted with permission from Singal AG, et al. Hepatology 2023;78:1922-1965.
[m] An observation is an area identified at imaging that is distinctive from background liver. It may be a mass or a pseudo lesion.
[n] Criteria for observations that are definitely HCC have been proposed by Liver Imaging Reporting and Data System (LI-RADS) and adopted by American Association for the Study of Liver Diseases (AASLD). These criteria apply only to patients at high risk for HCC. Organ Procurement and Transplantation Network (OPTN) has proposed imaging criteria for HCC applicable in candidates for liver transplant.
[o] Before biopsy, evaluate if patient is a resection or transplant candidate. If patient is a potential transplant candidate, consider referral to transplant center before biopsy.
[p] Principles of Core Needle Biopsy (HCC-B).
[q] If no observations are detected at diagnostic imaging despite positive surveillance tests, then return to surveillance in 6 months if the most reasonable explanation is that surveillance tests were false positives. Consider imaging with an alternative method ± AFP if there is reasonable suspicion that the diagnostic imaging test was false negative.
[r] Principles of Mixed HCC-CCA (HCC-C).
[s] Principles of Pathology (HCC-D).

Note: All recommendations are category 2A unless otherwise indicated.

Version 2.2025, 10/22/25 © 2025 National Comprehensive Cancer Network® (NCCN®), All rights reserved. NCCN Guidelines® and this illustration may not be reproduced in any form without the express written permission of NCCN.

PLEASE NOTE that use of this NCCN Content is governed by the End-User License Agreement, and you MAY NOT distribute this Content or use it with any artificial intelligence model or tool.
Printed by Galya Basol Kochav on 1/5/2026 10:54:24 AM. Copyright © 2026 National Comprehensive Cancer Network, Inc. All Rights Reserved.

CLINICAL PRESENTATION | **WORKUP**

HCC confirmed →

Multidisciplinary evaluation[t]
(assess liver reserve[u] and comorbidity) and staging:
- **History and physical examination**
- **Hepatitis panel[v]**
- **Bilirubin, transaminases, alkaline phosphatase**
- **Prothrombin time or international normalized ratio (INR), albumin, blood urea nitrogen, creatinine**
- **Complete blood count, platelets**
- **AFP**
- **Chest CT[a]**
- **Bone scan if clinically indicated[a]**
- **Abdomen/pelvis CT or MRI with contrast, if not previously done or needs updating[a]**
- **Consider referral to a hepatologist**

→ **Potentially resectable or transplantable by tumor burden; and operable by performance status or comorbidity (HCC-4)**

→ **Liver-confined, unresectable, and deemed ineligible for transplant (HCC-5)**

→ **Extrahepatic/metastatic disease; and deemed ineligible for resection, transplant, or locoregional therapy (HCC-6)**

[a] Principles of Imaging (HCC-A).
[t] Multidisciplinary evaluation of HCC should include hepatologists, diagnostic and interventional radiologists, surgeons, medical oncologists, radiation oncologists, and pathologists with HCC expertise.
[u] See Principles of Liver Functional Assessment (HCC-E) and assess portal hypertension (eg, varices, splenomegaly, thrombocytopenia).
[v] An appropriate hepatitis panel should preferably include:
- Hepatitis B surface antigen (HBsAg). If the HBsAg is positive, check hepatitis B e antigen, hepatitis B e antibody, and quantitative HBV DNA and refer to hepatologist.
- Hepatitis B surface antibody (for vaccine evaluation only).
- Hepatitis B core antibody (HBcAb) IgG. The HBcAb IgM should only be checked in cases of acute viral hepatitis. An isolated HBcAb IgG may still be chronic HBV and should prompt testing for a quantitative HBV DNA.
- Hepatitis C antibody. If positive, check quantitative HCV RNA and HCV genotype and refer to hepatologist.

Note: All recommendations are category 2A unless otherwise indicated.

Version 2.2025, 10/22/25 © 2025 National Comprehensive Cancer Network® (NCCN®), All rights reserved. NCCN Guidelines® and this illustration may not be reproduced in any form without the express written permission of NCCN.

PLEASE NOTE that use of this NCCN Content is governed by the End-User License Agreement, and you MAY NOT distribute this Content or use it with any artificial intelligence model or tool.
Printed by Galya Basol Kochav on 1/5/2026 10:54:24 AM. Copyright © 2026 National Comprehensive Cancer Network, Inc. All Rights Reserved.

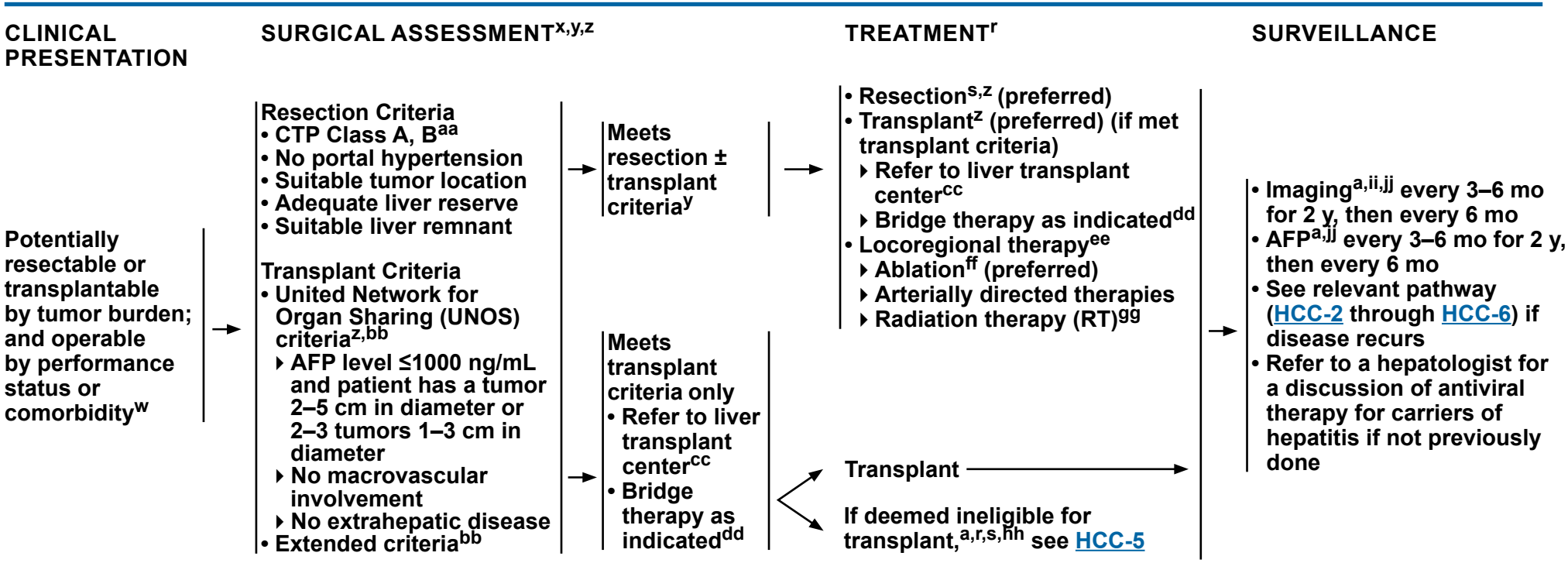

[a] Principles of Imaging (HCC-A).
[r] Principles of Mixed HCC-CCA (HCC-C).
[s] Principles of Pathology (HCC-D).
[w] Patients should be evaluated by a multidisciplinary team.
[x] Discussion of surgical treatment with patient and determination of whether patient is amenable to surgery.
[y] In patients being considered for surgery, patients with CTP Class A or highly selected patients with CTP Class B liver function, who fit UNOS criteria/extended criteria (www.unos.org) and are resectable could be considered for resection or transplant. These patients should be evaluated by a multidisciplinary team for individualized decision-making.
[z] Principles of Resection and Transplant (HCC-F).
[aa] In highly selected patients with CTP Class B liver function with limited resection.
[bb] Extended criteria/downstaging protocols are available through UNOS. See https://optn.transplant.hrsa.gov/media/1200/optn_policies.pdf#nameddest=Policy_09.
[cc] Mazzaferro V, et al. N Engl J Med 1996;334:693-700.
[dd] Many transplant centers consider bridge therapy for transplant candidates (See Discussion).
[ee] Principles of Locoregional Therapy (HCC-G).
[ff] In well-selected patients with small, properly located tumors, ablation should be considered as definitive treatment in the context of a multidisciplinary review.
[gg] Principles of Radiation Therapy (HCC-H).
[hh] Consider biopsy if imaging is not consistent or to confirm imaging diagnosis if it does not meet AASLD or LIRADS-5 criteria. See Principles of Core Needle Biopsy (HCC-B).
[ii] Multiphasic abdomen MRI or multiphase CT scans for liver assessment, CT chest, and CT/MRI pelvis.
[jj] Surveillance imaging and AFP should continue for at least 5 years; and thereafter screening is dependent on HCC risk factors.

Note: All recommendations are category 2A unless otherwise indicated.

For relapse, see Initial Workup (HCC-3)

Version 2.2025, 10/22/25 © 2025 National Comprehensive Cancer Network® (NCCN®), All rights reserved. NCCN Guidelines® and this illustration may not be reproduced in any form without the express written permission of NCCN.

PLEASE NOTE that use of this NCCN Content is governed by the End-User License Agreement, and you MAY NOT distribute this Content or use it with any artificial intelligence model or tool.
Printed by Galya Basol Kochav on 1/5/2026 10:54:24 AM. Copyright © 2026 National Comprehensive Cancer Network, Inc. All Rights Reserved.

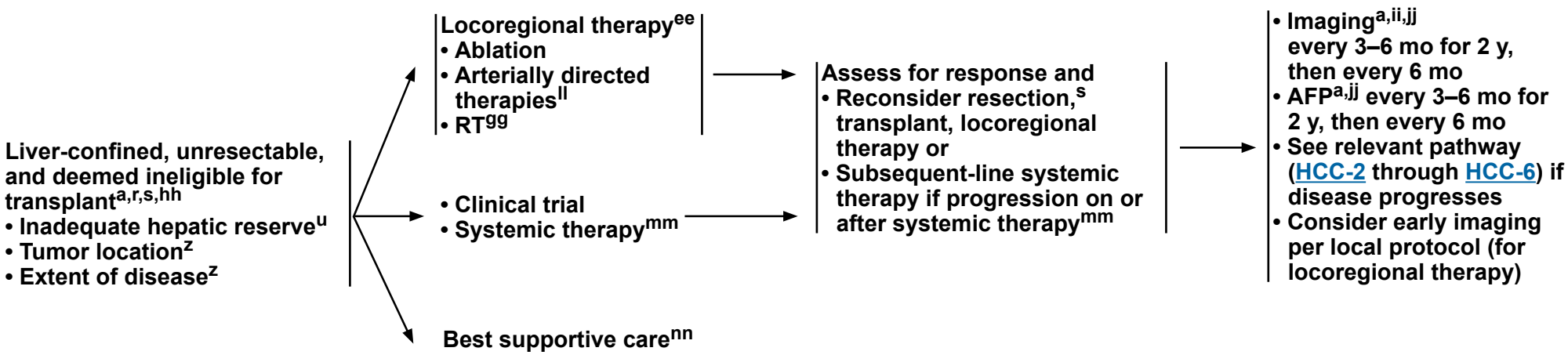

[a] Principles of Imaging (HCC-A).
[r] Principles of Mixed HCC-CCA (HCC-C).
[s] Principles of Pathology (HCC-D).
[u] See Principles of Liver Functional Assessment (HCC-E) and assess portal hypertension (eg, varices, splenomegaly, thrombocytopenia).
[z] Principles of Resection and Transplant (HCC-F).
[ee] Principles of Locoregional Therapy (HCC-G).
[gg] Principles of Radiation Therapy (HCC-H).
[hh] Consider biopsy if imaging is not consistent or to confirm imaging diagnosis if it does not meet AASLD or LIRADS-5 criteria. See Principles of Core Needle Biopsy (HCC-B).
[ii] Multiphasic abdomen MRI or multiphase CT scans for liver assessment, CT chest, and CT/MRI pelvis.
[jj] Surveillance imaging and AFP should continue for at least 5 years; and thereafter screening is dependent on HCC risk factors.
[kk] Order does not indicate preference. The choice of treatment modality may depend on extent/location of disease, hepatic reserve, and institutional capabilities.
[ll] Use of chemoembolization has also been supported by randomized controlled trials in selected populations over best supportive care.
[mm] Principles of Systemic Therapy (HCC-I).
[nn] See NCCN Guidelines for Palliative Care.

Note: All recommendations are category 2A unless otherwise indicated.

Version 2.2025, 10/22/25 © 2025 National Comprehensive Cancer Network® (NCCN®), All rights reserved. NCCN Guidelines® and this illustration may not be reproduced in any form without the express written permission of NCCN.

PLEASE NOTE that use of this NCCN Content is governed by the End-User License Agreement, and you MAY NOT distribute this Content or use it with any artificial intelligence model or tool.
Printed by Galya Basol Kochav on 1/5/2026 10:54:24 AM. Copyright © 2026 National Comprehensive Cancer Network, Inc. All Rights Reserved.

CLINICAL PRESENTATION | **TREATMENT[r,kk]** | **RESPONSE ASSESSMENT**

Extrahepatic/metastatic disease; and deemed ineligible for resection, transplant, or locoregional therapy

→ **Consider biopsy[p,r] (preferred) for histologic confirmation if not previously done**

→ **• Clinical trial**
• Systemic therapy[mm]

→ **Assess for response and**
• Reconsider locoregional therapy and multidisciplinary review
or
• Subsequent-line systemic therapy if progression on or after systemic therapy[mm]

→ **• Best supportive care[nn]**

[p] Principles of Core Needle Biopsy (HCC-B).
[r] Principles of Mixed HCC-CCA (HCC-C).
[kk] Order does not indicate preference. The choice of treatment modality may depend on extent/location of disease, hepatic reserve, and institutional capabilities.
[mm] Principles of Systemic Therapy (HCC-I).
[nn] See NCCN Guidelines for Palliative Care.

Note: All recommendations are category 2A unless otherwise indicated.

Version 2.2025, 10/22/25 © 2025 National Comprehensive Cancer Network® (NCCN®), All rights reserved. NCCN Guidelines® and this illustration may not be reproduced in any form without the express written permission of NCCN.

PLEASE NOTE that use of this NCCN Content is governed by the End-User License Agreement, and you MAY NOT distribute this Content or use it with any artificial intelligence model or tool.
Printed by Galya Basol Kochav on 1/5/2026 10:54:24 AM. Copyright © 2026 National Comprehensive Cancer Network, Inc. All Rights Reserved.

PRINCIPLES OF IMAGING

Screening and Surveillance

- Screening and surveillance for HCC is considered cost effective in patients with cirrhosis of any cause and patients with chronic hepatitis B (CHB) even in the absence of cirrhosis.[1,2] The recommended screening and surveillance imaging method is US, and the recommended interval is every 6 months.[1,2] Contrast-enhanced multiphase CT or MRI are more sensitive than US for HCC detection,[3] but they are more costly. They may be performed as an alternative to US if US fails to detect nodules or if visualization is poor (see below).[4] Serum biomarkers such as AFP may incrementally improve the performance of imaging-based screening and surveillance.
- Patients with viral hepatitis who have had a complete or sustained viral response should continue with screening despite that response.[5]

Imaging Diagnosis of HCC

- After a positive screening or surveillance test or after lesions are detected incidentally on routine imaging studies done for other reasons, multiphasic abdomen CT or MRI studies with contrast are recommended to establish the diagnosis and stage the tumor burden in the liver. Optimal imaging technique depends on the modality and contrast agent, as summarized by Liver Imaging Reporting and Data System (LI-RADS).[6] To standardize interpretation, the American Association for the Study of Liver Diseases (AASLD),[1] European Association for the Study of the Liver,[2] Organ Procurement and Transplantation Network (OPTN),[7] and LI-RADS[6,8] have adopted imaging criteria to diagnose HCC nodules greater than or equal to 10 mm. Criteria have not been proposed for nodules less than 10 mm as these are difficult to definitively characterize at imaging. Major imaging features of HCC include nonrim arterial phase hyperenhancement, nonperipheral washout, enhancing capsule, and threshold growth.[6,8] LI-RADS also provides imaging criteria to diagnose major vascular invasion.[6] Having criteria for vascular invasion is necessary because the tumor in the vein may not have the same imaging features as parenchymal tumors.
- Importantly, imaging criteria for parenchymal nodules apply only to patients at high risk for developing HCC: namely, those with cirrhosis (with exceptions of patients with cirrhosis due to congenital hepatic fibrosis, vascular causes, or less than 18 years of age), CHB, or current or prior HCC. In these patients, the prevalence of HCC is sufficiently high that lesions meeting imaging criteria for HCC have close to a 100% probability of being HCC. The criteria do not apply to the general population or, except for CHB, to patients with chronic liver disease that has not progressed to cirrhosis. The criteria are designed to have high specificity for HCC; thus, lesions meeting these criteria can be assumed to represent HCC and may be treated as such without confirmatory biopsy. As a corollary, the criteria have modest sensitivity; thus, many HCCs do not satisfy the required criteria and failure to meet the criteria does not exclude HCC.[6]
- Lesions that do not meet the imaging criteria described above for HCC require individualized workup, which may include additional imaging or biopsy as informed by multidisciplinary discussion and are outlined in the treatment algorithms.
- Quality of MRI is dependent on patient compliance.
- In patients with more advanced stages of disease appropriate for systemic therapy, biopsy[a] should be considered noting that noninvasive imaging criteria have been studied predominantly in earlier stages of disease. A multicenter national audit of 418 patients being evaluated for systemic therapy for HCC in the United Kingdom demonstrated that approximately 7% of patients with a radiographic diagnosis of HCC had an alternative diagnosis such as cholangiocarcinoma (CCA) or mixed HCC-CCA on histologic confirmation.[9]

Extrahepatic Staging

- Frequent sites of extrahepatic metastases from HCC include lungs, bone, and lymph nodes. Adrenal and peritoneal metastases also may occur. For this reason, chest CT, complete imaging of abdomen and pelvis with contrast-enhanced CT or MRI, and selective use of bone scan[10] when skeletal symptoms are present are recommended at initial diagnosis of HCC and for monitoring disease while on the transplant wait list or during or after treatment for response assessment. Chest CT may be performed with contrast if concurrently acquired with contrast-enhanced abdomen/pelvis CT. If MRI is performed, chest CT may be acquired without contrast.

[a] Principles of Core Needle Biopsy (HCC-B).

References on HCC-A 3 of 3

Note: All recommendations are category 2A unless otherwise indicated.

Continued

Version 2.2025, 10/22/25 © 2025 National Comprehensive Cancer Network® (NCCN®), All rights reserved. NCCN Guidelines® and this illustration may not be reproduced in any form without the express written permission of NCCN.

PLEASE NOTE that use of this NCCN Content is governed by the End-User License Agreement, and you MAY NOT distribute this Content or use it with any artificial intelligence model or tool.
Printed by Galya Basol Kochav on 1/5/2026 10:54:24 AM. Copyright © 2026 National Comprehensive Cancer Network, Inc. All Rights Reserved.

PRINCIPLES OF IMAGING

Imaging Diagnosis of iCCA and cHCC-CCA

Patients at risk for HCC due to cirrhosis, CHB, or other conditions are also at elevated risk for developing non-HCC primary hepatic malignancies such as intrahepatic CCA (iCCA) and combined HCC-CCA (cHCC-CCA). Although iCCAs and cHCC-CCAs tend to have malignant imaging features, the features are not sufficiently specific to permit noninvasive diagnosis.[8,11] Biopsy[a] or definitive resection usually is necessary to make a diagnosis.

Imaging Protocol for Response Assessment After Treatment

CT of the chest and multiphasic CT or MRI of the abdomen and pelvis are the preferred modalities as they reliably assess intranodular arterial vascularity, a key feature of residual or recurrent tumor.

Role of CEUS

Contrast-enhanced US (CEUS) is considered a problem-solving tool for use at select centers with the relevant expertise for characterization of indeterminate nodules. It is not suitable for whole-liver assessment, surveillance, or cancer staging.[12]

Role of FDG-PET

FDG-PET/CT has limited sensitivity but high specificity, and may be considered when there is an equivocal finding. When HCC is detected by CT or MRI and has increased metabolic activity on FDG-PET/CT, higher intralesional standardized uptake value is a marker of biologic aggressiveness and might predict less optimal response to locoregional therapies.[13]

[a] Principles of Core Needle Biopsy (HCC-B).

References on HCC-A 3 of 3

Note: All recommendations are category 2A unless otherwise indicated.

Version 2.2025, 10/22/25 © 2025 National Comprehensive Cancer Network® (NCCN®), All rights reserved. NCCN Guidelines® and this illustration may not be reproduced in any form without the express written permission of NCCN.

PLEASE NOTE that use of this NCCN Content is governed by the End-User License Agreement, and you MAY NOT distribute this Content or use it with any artificial intelligence model or tool.
Printed by Galya Basol Kochav on 1/5/2026 10:54:24 AM. Copyright © 2026 National Comprehensive Cancer Network, Inc. All Rights Reserved.

PRINCIPLES OF IMAGING
REFERENCES

[1] Singal AG, Llovet JM, Yarchoan M, et al. AASLD Practice Guidance on prevention, diagnosis, and treatment of hepatocellular carcinoma. Hepatology 2023;78:1922-1965.
[2] European Association for the Study of the Liver. EASL Clinical Practice Guidelines: Management of hepatocellular carcinoma. J Hepatol 2018;69:182-236.
[3] Colli A, Fraquelli M, Casazza G, et al. Accuracy of ultrasonography, spiral CT, magnetic resonance, and alpha-fetoprotein in diagnosing hepatocellular carcinoma: a systematic review. Am J Gastroenterol 2006;101:513-523.
[4] Korean Liver Cancer Association (KLCA) and National Cancer Center (NCC) Korea. 2022 KLCA-NCC Korea practice guidelines for the management of hepatocellular carcinoma. Clin Mol Hepatol 2022;28:583-705.
[5] Ioannou GN. HCC surveillance after SVR in patients with F3/F4 fibrosis. J Hepatol 2021;74:458-465.
[6] American College of Radiology. Liver Imaging Reporting & Data System website. Available at: https://www.acr.org/Clinical-Resources/Clinical-Tools-and-Reference/Reporting-and-Data-Systems/LI-RADS. Accessed March 13, 2025.
[7] Pomfret EA, Washburn K, Wald C, et al. Report of a national conference on liver allocation in patients with hepatocellular carcinoma in the United States. Liver Transpl 2010;16:262-278.
[8] Fowler KJ, Potretzke TA, Hope TA, et al. LI-RADS M (LR-M): definite or probable malignancy, not specific for hepatocellular carcinoma. Abdom Radiol (NY) 2018; 43:149-157.
[9] Childs A, Zakeri N, Ma YT, et al. Biopsy for advanced hepatocellular carcinoma: Results of a multicentre UK audit. Br J Cancer 2021;125:1350-1355.
[10] Harding JJ, Abu-Zeinah G, Chour JF, et al. Frequency, morbidity, and mortality of bone metastases in advanced hepatocellular carcinoma. J Natl Compr Canc Netw 2018;16:50-58.
[11] Choi JY, Lee JM, Sirlin CB. CT and MR imaging diagnosis and staging of hepatocellular carcinoma: part II. Extracellular agents, hepatobiliary agents, and ancillary imaging features. Radiology 2014;273:30-50.
[12] Dietrich CF, Nolsøe CP, Barr RG, et al. Guidelines and good clinical practice recommendations for contrast enhanced ultrasound (CEUS) in the liver - update 2020: WFUMB in cooperation with EFSUMB, AFSUMB, AIUM, and FLAUS. Ultrasound Med Biol 2020;46:2579-2604.
[13] Sun DW, An L, Wei F, et al. Prognostic significance of parameters from pretreatment (18)F-FDG PET in hepatocellular carcinoma: a meta-analysis. Abdom Radiol (NY) 2016;41:33-41.

Note: All recommendations are category 2A unless otherwise indicated.

Version 2.2025, 10/22/25 © 2025 National Comprehensive Cancer Network® (NCCN®), All rights reserved. NCCN Guidelines® and this illustration may not be reproduced in any form without the express written permission of NCCN.

PLEASE NOTE that use of this NCCN Content is governed by the End-User License Agreement, and you MAY NOT distribute this Content or use it with any artificial intelligence model or tool.
Printed by Galya Basol Kochav on 1/5/2026 10:54:24 AM. Copyright © 2026 National Comprehensive Cancer Network, Inc. All Rights Reserved.

PRINCIPLES OF CORE NEEDLE BIOPSY[a]

Indicators for consideration of core needle biopsy may include:

- **Initial core needle biopsy[b]**
  - **Lesion is highly suspicious for malignancy at multiphasic CT or MRI but does not meet imaging features[c] for HCC. Multidisciplinary review at a center of expertise is recommended.**
  - **Lesion meets imaging features[c] for HCC but:**
    - ◊ **Patient is not considered at high risk for HCC development (ie, does not have cirrhosis, CHB, or current or prior HCC).**
    - ◊ **Patient has cardiac cirrhosis, congenital hepatic fibrosis, or cirrhosis due to a vascular disorder such as Budd-Chiari syndrome, hereditary hemorrhagic telangiectasia, or nodular regenerative hyperplasia.[d]**
    - ◊ **Patient has elevated CA 19-9 or carcinoembryonic antigen with suspicion of iCCA or cHCC-CCA.**
  - **Confirmation of metastatic disease could change clinical decision-making including enrollment in clinical trials.**
  - **Surgical resection without core needle biopsy should be considered with multidisciplinary review.**
- **If core needle biopsy is considered, obtain prior to ablation.**

- **Repeat core needle biopsy**
  - **Non-diagnostic core needle biopsy**
  - **Prior core needle biopsy discordant with imaging, biomarkers, or other factors**

[a] Principles of Pathology (HCC-D).
[b] Principles of Molecular Testing (HCC-H).
[c] Imaging criteria for HCC have been proposed by LI-RADS and adopted by AASLD. These criteria apply only to patients at high risk for HCC. OPTN has proposed imaging criteria for HCC applicable in liver transplant candidates. See Principles of Imaging (HCC-A).
[d] These conditions are associated with formation of nonmalignant nodules that may resemble HCC at imaging.

Note: All recommendations are category 2A unless otherwise indicated.

Version 2.2025, 10/22/25 © 2025 National Comprehensive Cancer Network® (NCCN®), All rights reserved. NCCN Guidelines® and this illustration may not be reproduced in any form without the express written permission of NCCN.

PLEASE NOTE that use of this NCCN Content is governed by the End-User License Agreement, and you MAY NOT distribute this Content or use it with any artificial intelligence model or tool.
Printed by Galya Basol Kochav on 1/5/2026 10:54:24 AM. Copyright © 2026 National Comprehensive Cancer Network, Inc. All Rights Reserved.

PRINCIPLES OF MIXED HCC-CCA

An estimated 1% to 10% of patients with primary liver tumors are found to have a combination of both HCC and CCA histologies on pathologic review.[1-4] In some cases, tumors may contain separate foci of both HCC and CCA histology in discrete areas of a tumor, while in other cases a tumor may be biphenotypic with expression of immunohistochemical markers associated independently with HCC and CCA but co-expressed on the same cells. Next-generation sequencing of mixed HCC-CCA suggests a higher prevalence of genomic aberrations more commonly associated with HCC than CCA (such as presence of *TP53* and *TERT* promoter mutations), particularly in patients with underlying hepatitis C virus infection, but interpretation of these results is limited by small sample sizes.[3,5]

Liver resection is considered the standard treatment for resectable mixed HCC-CCA.[6] Though prospective data are lacking, liver-directed local therapies may be appropriate for patients with a limited extent of unresectable hepatic disease, similar to management algorithms for HCC and iCCA (see HCC-6 and NCCN Guidelines for Biliary Tract Cancers).

Patients with HCC-CCA that is limited in size based on center-specific criteria used should be considered for evaluation in a transplant center.

In patients with metastatic or locally-advanced recurrence after a prior resection or local therapies for mixed HCC-CCA, a repeat biopsy[a] should be considered to ascertain the dominant histology at recurrence. If the biopsy at recurrence suggests an isolated recurrence of either the HCC or CCA component, the Panel would consider a systemic therapy option appropriate for that histologic component.

Tumor molecular profiling should be considered in all patients with advanced stages of mixed HCC-CCA tumors to identify potential targetable aberrations that may be associated with CCA (see NCCN Guidelines for Biliary Tract Cancers).

For patients with histologic evidence of mixed HCC-CCA at advanced stages requiring systemic therapy, there are limited prospective data to guide the choice of regimen. A retrospective series of 101 patients with mixed HCC-CCA treated with systemic therapy demonstrated similar overall response rates for patients treated with chemotherapy versus non-chemotherapy–based systemic therapies; there was a trend towards longer median overall survival in patients treated with chemotherapy (15.5 vs. 5.3 months; $P = .052$).[7] Based upon these data as well as the potential for activity of component parts in both histologies, a regimen of gemcitabine plus cisplatin chemotherapy combined with either durvalumab or pembrolizumab immunotherapy is an appropriate choice for first-line therapy, noting that these combinations include agents with anti-tumor activity in both CCA[8-10] and HCC histologies.[11-14] At progression, molecularly-targeted therapies should be considered if the tumor harbors a targetable aberration. In the absence of a targetable aberration, regimens with demonstrated activity in both HCC and CCA are reasonable options, including the combination of nivolumab plus ipilimumab[15,16] or regorafenib.[17,18] A repeat biopsy[a] at tumor progression may be warranted to reassess dominant histology of a progressing lesion, especially if there are discordant areas of response and progression and if the patient remains a candidate for further systemic therapy.

[a] Principles of Pathology (HCC-D).

References on HCC-C 2 of 2

Note: All recommendations are category 2A unless otherwise indicated.

Version 2.2025, 10/22/25 © 2025 National Comprehensive Cancer Network® (NCCN®), All rights reserved. NCCN Guidelines® and this illustration may not be reproduced in any form without the express written permission of NCCN.

PLEASE NOTE that use of this NCCN Content is governed by the End-User License Agreement, and you MAY NOT distribute this Content or use it with any artificial intelligence model or tool.
Printed by Galya Basol Kochav on 1/5/2026 10:54:24 AM. Copyright © 2026 National Comprehensive Cancer Network, Inc. All Rights Reserved.

PRINCIPLES OF MIXED HCC-CCA
REFERENCES

[1] Childs A, Zakeri N, Ma YT, et al. Biopsy for advanced hepatocellular carcinoma: Results of a multicentre UK audit. Br J Cancer 2021;125:1350-1355.
[2] Teufel A, Rodriguez I, Winzler C, et al. Clinical characterization of HCC/CCA mixed cancers in a population-based cohort. J Gastrointestin Liver Dis 2023;32:190-196.
[3] Raevskaya O, Appelman H, Razumilava N. A contemporary approach to diagnosis and treatment of combined hepatocellular-cholangiocarcinoma. Curr Hepatol Rep 2020;19:478-485.
[4] Tang Y, Wang L, Teng F, et al. The clinical characteristics and prognostic factors of combined hepatocellular carcinoma and cholangiocarcinoma, hepatocellular carcinoma and intrahepatic cholangiocarcinoma after surgical resection: A propensity score matching analysis. Int J Med Sci 2021;18:187-198.
[5] Joseph NM, Tsokos CG, Umetsu SE, et al. Genomic profiling of combined hepatocellular-cholangiocarcinoma reveals similar genetics to hepatocellular carcinoma. J Pathol 2019;248:164-178.
[6] Claasen MPAW, Ivanics T, Beumer BR, et al. An international multicentre evaluation of treatment strategies for combined hepatocellular-cholangiocarcinoma. JHEP Rep 2023;5:100745.
[7] Pomej K, Balcar L, Shmanko K, et al. Clinical characteristics and outcome of patients with combined hepatocellular-cholangiocarcinoma-a European multicenter cohort. ESMO Open 2023;8:100783.
[8] Kelley RK, Ueno M, Yoo C, et al. Pembrolizumab in combination with gemcitabine and cisplatin compared with gemcitabine and cisplatin alone for patients with advanced biliary tract cancer (KEYNOTE-966): a randomised, double-blind, placebo-controlled, phase 3 trial. Lancet 2023;401:1853-1865
[9] Oh DY, He AR, Qin S, et al. Durvalumab plus gemcitabine and cisplatin in advanced biliary tract cancer. NEJM Evid 2022;1:EVIDoa2200015.
[10] Valle J, Wasan H, Palmer DH, et al. Cisplatin plus gemcitabine versus gemcitabine for biliary tract cancer. N Engl J Med 2010;362:1273-1281.
[11] Abou-Alfa GK, Lau G, Kudo M, et al. Tremelimumab plus durvalumab in unresectable hepatocellular carcinoma. NEJM Evid 2022;1:EVIDoa2100070.
[12] Finn RS, Ryoo BY, Merle P, et al. Pembrolizumab as second-line therapy in patients with advanced hepatocellular carcinoma in KEYNOTE-240: A randomized, double-blind, phase III trial. J Clin Oncol 2020;38:193-202.
[13] Qin S, Chen Z, Fang W, et al. Pembrolizumab versus placebo as second-line therapy in patients from Asia with advanced hepatocellular carcinoma: A randomized, double-blind, phase III trial. J Clin Oncol 2023;41:1434-1443.
[14] Zhu AX, Finn RS, Edeline J, et al. Pembrolizumab in patients with advanced hepatocellular carcinoma previously treated with sorafenib (KEYNOTE-224): A non-randomised, open-label phase 2 trial. Lancet Oncol 2018;19:940-952.
[15] Yau T, Kang YK, Kim TY, et al. Efficacy and safety of nivolumab plus ipilimumab in patients with advanced hepatocellular carcinoma previously treated with sorafenib: The checkmate 040 randomized clinical trial. JAMA Oncol 2020;6:e204564.
[16] Klein O, Kee D, Nagrial A, et al. Evaluation of combination nivolumab and ipilimumab immunotherapy in patients with advanced biliary tract cancers: Subgroup analysis of a phase 2 nonrandomized clinical trial. JAMA Oncol 2020;6:1405-1409.
[17] Bruix J, Qin S, Merle P, et al. Regorafenib for patients with hepatocellular carcinoma who progressed on sorafenib treatment (RESORCE): A randomised, double-blind, placebo-controlled, phase 3 trial. Lancet 2017;389:56-66.
[18] Sun W, Patel A, Normolle D, et al. A phase 2 trial of regorafenib as a single agent in patients with chemotherapy-refractory, advanced, and metastatic biliary tract adenocarcinoma. Cancer 2019;125:902-909.

Note: All recommendations are category 2A unless otherwise indicated.

Version 2.2025, 10/22/25 © 2025 National Comprehensive Cancer Network® (NCCN®), All rights reserved. NCCN Guidelines® and this illustration may not be reproduced in any form without the express written permission of NCCN.

PLEASE NOTE that use of this NCCN Content is governed by the End-User License Agreement, and you MAY NOT distribute this Content or use it with any artificial intelligence model or tool.
Printed by Galya Basol Kochav on 1/5/2026 10:54:24 AM. Copyright © 2026 National Comprehensive Cancer Network, Inc. All Rights Reserved.

PRINCIPLES OF PATHOLOGY[a,1-3]

Hepatocellular Carcinoma Appropriate for Biopsy

Histologic confirmation of primary hepatic malignancy

- **Reported parameters**
  - **Establish hepatocellular differentiation by histology and if appropriate supported by immunohistochemical and in-situ hybridization studies. The presence of small vessel invasion, undifferentiated/poor differentiation and non-hepatocellular components such as cholangiocyte differentiation (possible combined hepatocellular cholangiocarcinoma).**

Hepatocellular Carcinoma Appropriate for Resection

Establish hepatocellular differentiation and possible histologic subtypes.

Staging for diagnosis and prognosis of primary hepatic malignancy

- **Pathologic staging**
  - **The following parameters should be reported for cancer with histopathologic type[b]: HCC or fibrolamellar carcinoma variant of HCC**
    - ◊ **Tumor (T)**
    - ◊ **Number, size, and location of tumor(s) (T stage)**
    - ◊ **Number of regional lymph nodes[c] evaluated and infiltrated with malignancy (N stage)**
    - ◊ **Metastatic disease (M stage)**
    - ◊ **Histologic differentiation**
    - ◊ **Large vessel[d] or microscopic vascular invasion**
    - ◊ **Perineural invasion**
    - ◊ **Hilar and resection margin status**

Hepatocellular Carcinoma Appropriate for Resection (continued)

- ◊ **Any tumor involving a major branch of the portal vein or hepatic vein, or direct invasion of adjacent organs other than the gallbladder or with perforation of visceral peritoneum**
- ◊ **Blocks containing malignant tissue and non-malignant tissue ideal for further testing**

If adequate sample available

- **Histopathologic types of HCC**
  - **Steatohepatitic**
  - **Clear cell**
  - **Macrotrabecular**
  - **Scirrhous**
  - **Chromophobe**
  - **Fibrolamellar carcinoma/Fibrolamellar HCC**
  - **Neutrophil-rich**
  - **Lymphocyte-rich**

- **Background liver disease and staging of fibrosis**
  - **Indicate the presence or absence of chronic liver disease (viral hepatitis, MASLD, metabolic disorder, etc) either from the clinical history or histopathologic changes.**
  - **Establish the degree of fibrosis that can be reported by description or using a scoring system such as Batts-Ludwig, modified Ishak or METAVIR. The presence, absence, or degree (complete vs. incomplete) of cirrhosis should be clearly stated.**

Footnotes

[a] Principles of Liver Functional Assessment (HCC-E).
[b] Cancers not staged in this section: Intrahepatic cholangiocarcinoma and combined hepatocellular-cholangiocarcinoma are staged according to intrahepatic cholangiocarcinoma.
[c] Regional nodes are those associated with the hepatic artery and portal vein at the hilum and the hepatoduodenal ligament, inferior phrenic, and caval lymph nodes.
[d] Large vessels are defined as the right or left branches of the main portal vein, which excludes the sectoral and segmental branches; one or more of the three hepatic veins (right, middle, or left); or the main branches of the hepatic artery (right or left hepatic artery).

References

[1] Batts KP, Ludwig J. Chronic hepatitis. An update on terminology and reporting. Am J Surg Path 1995;19:1409-1417.
[2] Ishak K, Baptista A, Bianchi L, et al. Histological grading and staging of chronic hepatitis. J Hepatol 1995;22:696-699.
[3] Bedossa P. Intraobserver and interobserver variations in liver biopsy interpretation in patients with chronic hepatitis C. Hepatology 1994;20:15-20.

Note: All recommendations are category 2A unless otherwise indicated.

Version 2.2025, 10/22/25 © 2025 National Comprehensive Cancer Network® (NCCN®), All rights reserved. NCCN Guidelines® and this illustration may not be reproduced in any form without the express written permission of NCCN.

PLEASE NOTE that use of this NCCN Content is governed by the End-User License Agreement, and you MAY NOT distribute this Content or use it with any artificial intelligence model or tool.
Printed by Galya Basol Kochav on 1/5/2026 10:54:24 AM. Copyright © 2026 National Comprehensive Cancer Network, Inc. All Rights Reserved.

PRINCIPLES OF LIVER FUNCTIONAL ASSESSMENT

- **General assessment of liver function should include a thorough history and physical examination as well as serum laboratory tests.**
- **Assessment should include evaluation for clinically significant portal hypertension, which may be manifested by ascites, esophagogastric varices, splenomegaly, splenorenal shunts, recanalization of the umbilical vein, or thrombocytopenia. Portal hypertension can be confirmed by measuring the hepatic vein pressure gradient. In addition, hepatic synthetic function (albumin and coagulation studies) and total bilirubin should also be evaluated.**
- **The CTP Score classification is the most common tool to assess liver function. It provides a general estimate of the liver function by classifying patients with cirrhosis as having compensated (Class A) or decompensated (Classes B and C) cirrhosis based upon blood tests and extent of ascites and encephalopathy, if any.**
- **Model for End-Stage Liver Disease (MELD) is a numerical scale ranging from 6 (well compensated without evidence of hepatic decompensation = CTP Class A) to 40 (severe hepatic decompensation with poor prognosis = CTP Class C) to risk stratify patients in the setting of cirrhosis. Originally devised to risk stratify patients undergoing transjugular intrahepatic portosystemic shunt, it has since been adopted by UNOS to rank patients on the liver transplantation waiting list for donor allocation.**
- **Another alternative to the CTP score is the Albumin-Bilirubin (ALBI) grade, which may help stratify patients with relatively stable cirrhosis.**
- **Noninvasive tools such as ultrasound-based or magnetic resonance-based elastography as well as histologic evaluation of non-tumor liver can be used to determine presence and extent of inflammation/hepatitis, steatosis, and fibrosis/cirrhosis.**
- **Most systemic therapies for HCC have been studied in patients with CTP A liver cirrhosis. Treatment in patients with greater degrees of liver dysfunction requires individualized decision-making including review of any dose modification guidelines for hepatic dysfunction in package insert for specific agents, selection of alternate agents with evidence for safety in hepatic dysfunction, and close monitoring for toxicity. Use of these agents in the CTP B population is largely extrapolated from data from patients with CTP A liver disease and retrospective/real world data demonstrating diminished efficacy but no new safety signals.[1-4] Prospective clinical trials are necessary to further clarify dose, safety, and survival benefit of systemic therapies in such patients. Patients with CTP C liver disease or progressive hepatic decompensation to end-stage liver failure should only be offered systemic therapy in select circumstances or clinical trials given the unclear survival benefit in this setting, and may require transition to best supportive/palliative care.[5]**

[1] D'Alessio A, Fulgenzi CAM, Nishida N, et al. Preliminary evidence of safety and tolerability of atezolizumab plus bevacizumab in patients with hepatocellular carcinoma and Child-Pugh A and B cirrhosis: A real-world study. Hepatology 2022;76:1000-1012.
[2] Kudo M, Matilla A, Santoro A, et al. Checkmate 040 cohort 5: A phase I/II study of nivolumab in patients with advanced hepatocellular carcinoma and Child-Pugh B cirrhosis. J Hepatol 2021;75:600-609.
[3] Matilla A, Sangro B, El-Khoureiry A, et al. Checkmate 040 cohort 5: Long-term efficacy and safety of nivolumab in patients with Child-Pugh B advanced hepatocellular carcinoma: Associations between baseline biomarker analyses and outcomes [abstract]. J Hepatol 2021:75:Abstract OS-295.
[4] Kambhampati S, Bauer KE, Bracci PM, et al. Nivolumab in patients with advanced hepatocellular carcinoma and Child-Pugh class B cirrhosis: safety and clinical outcomes in a retrospective case series. Cancer 2019;125:3234-3241.
[5] Reig M, Forner A, Rimola J, et al. BCLC strategy for prognosis prediction and treatment recommendation: The 2022 update. J Hepatol 2022;76:681-693.

Note: All recommendations are category 2A unless otherwise indicated.

Version 2.2025, 10/22/25 © 2025 National Comprehensive Cancer Network® (NCCN®), All rights reserved. NCCN Guidelines® and this illustration may not be reproduced in any form without the express written permission of NCCN.

PLEASE NOTE that use of this NCCN Content is governed by the End-User License Agreement, and you MAY NOT distribute this Content or use it with any artificial intelligence model or tool.
Printed by Galya Basol Kochav on 1/5/2026 10:54:24 AM. Copyright © 2026 National Comprehensive Cancer Network, Inc. All Rights Reserved.

PRINCIPLES OF LIVER FUNCTIONAL ASSESSMENT

CTP SCORE[6]

Clinical and Biochemical Parameters	Scores (Points) for Increasing Abnormality		
	1	2	3
Encephalopathy (grade)[7]	None	1–2	3–4
Ascites	Absent	Slight	Moderate
Albumin (g/dL)	>3.5	2.8–3.5	<2.8
Prothrombin time[8]			
Seconds over control	<4	4–6	>6
INR	<1.7	1.7–2.3	>2.3
Bilirubin (mg/dL)	<2	2–3	>3
• For primary biliary cirrhosis	<4	4–10	>10

Class A = 5–6 points; Class B = 7–9 points; Class C = 10–15 points.

Class A: Good operative risk
Class B: Moderate operative risk
Class C: Poor operative risk

MELD SCORE[9]

MELD = 1.33 (if female) + [4.56 x $\log_e$(bilirubin)] + [0.82 x (137-sodium)] – [0.24 x (137-sodium) x $\log_e$(bilirubin)] + [9.09 x $\log_e$(INR)] + [11.14 x $\log_e$(creatinine)] + [1.85 x (3.5-albumin)] – [1.83 x (3.5-albumin) x $\log_e$(creatinine)] + 6

ALBI GRADE[10,11]

ALBI-score
[$\log_{10}$ bilirubin (µmol/L) x 0.66 + [albumin (g/L x -0.085]
ALBI grade is defined by the resulting score:
Grade 1 ≤ -2.60
Grade 2 > -2.60 to ≤ -1.39
Grade 3 > -1.39

[6] Adapted with permission from John Wiley & Sons Ltd on behalf of the BJSS Ltd. Pugh R, Murray-Lyon I, Dawson J, et al: Transection of the oesophagus for bleeding oesophageal varices. Br J of Surg 1973;60:646-649. ©British Journal of Surgery Society Ltd.
[7] Trey C, Burns DG, Saunders SJ. Treatment of hepatic coma by exchange blood transfusion. N Engl J Med 1966;274:473-481.
[8] Van Rijn JL, Schmidt NA, Rutten WP. Correction of instrument- and reagent-based differences in determination of the International Normalized Ratio (INR) for monitoring anticoagulant therapy. Clin Chem 1989;35:840-843.
[9] Adapted with permission from Organ Procurement and Transplantation Network. Briefing to the OPTN board of directors on improving liver allocation: MELD, PELD, status 1A, status 1B. Accessed February 5, 2024.
[10] Reproduced from: O'Rourke JM, Sagar VM, Shat T et al. Carcinogenesis on the background of liver fibrosis: Implications for the management of hepatocellular cancer. World J Gastroenterol 2018;24:4436-4447. Published by Baishideng Publishing Group Inc. All rights reserved.
[11] Johnson PJ, Berhane S, Kagebayashi C, et al. Assessment of liver function in patients with hepatocellular carcinoma: A new evidence-based approach-The ALBI grade. J Clin Oncol 2015;33:550-558.

Note: All recommendations are category 2A unless otherwise indicated.

Version 2.2025, 10/22/25 © 2025 National Comprehensive Cancer Network® (NCCN®), All rights reserved. NCCN Guidelines® and this illustration may not be reproduced in any form without the express written permission of NCCN.

PLEASE NOTE that use of this NCCN Content is governed by the End-User License Agreement, and you MAY NOT distribute this Content or use it with any artificial intelligence model or tool.
Printed by Galya Basol Kochav on 1/5/2026 10:54:24 AM. Copyright © 2026 National Comprehensive Cancer Network, Inc. All Rights Reserved.

PRINCIPLES OF RESECTION AND TRANSPLANT

- **Patients must be medically fit for a major operation.**
- **All patients should be evaluated for possible transplant candidacy with multidisciplinary review.**
- **Hepatic resection is indicated as a potentially curative option in the following circumstances:**
  - **Adequate liver function (generally CTP Class A without portal hypertension, but small series show feasibility of limited resections in patients with mild portal hypertension)[1]**
  - **Solitary mass without major vascular invasion**
  - **Adequate future liver remnant (at least 20% without cirrhosis and at least 30%–40% with CTP Class A cirrhosis, adequate vascular and biliary inflow/outflow)**
- **Hepatic resection is controversial in the following circumstances, but can be considered:**
  - **Limited and resectable multifocal disease**
  - **Major vascular invasion**
- **For patients with chronic liver disease being considered for major resection, preoperative portal vein embolization should be considered.[2,3]**
- **Select patients with initially unresectable disease that responds to therapy can be considered for surgery. Consultation with a medical oncologist, interventional radiologist, and a multidisciplinary team is recommended to determine the timing of surgery after systemic therapy.**
- **Patients meeting the UNOS criteria ([AFP level ≤1000 ng/mL and single lesion ≥2 cm and ≤5 cm, or 2 or 3 lesions ≥1 cm and ≤3 cm] www.unos.org) should be considered for transplantation (cadaveric or living donation).**
- **The MELD score is used by UNOS to assess the severity of liver disease and prioritize the allocation of the liver transplants.[4,5] MELD score can be determined using the MELD calculator: https://optn.transplant.hrsa.gov/resources/allocation-calculators/meld-calculator/. There are patients whose tumor characteristics are marginally outside of the UNOS guidelines who should be considered for transplant.[4] Furthermore, there are patients who are downstaged to within criteria that can also be considered for transplantation.[6] See Principles of Liver Functional Assessment (HCC-E).**
- **Patients with CTP Class A liver function, who fit UNOS criteria and are resectable, could be considered for resection or transplant. There is controversy over which initial strategy is preferable to treat such patients. These patients should be evaluated by a multidisciplinary team.**
- **Based on retrospective analyses, patients who are older may benefit from liver resection or transplantation for HCC, but they need to be carefully selected, as overall survival is lower than for patients who are younger.[7] Minimally invasive approaches by experienced surgeons have been proven to be safe and effective.**

[1] Santambrogio R, Kluger MD, Costa M, et al. Hepatic resection for hepatocellular carcinoma in patients with Child-Pugh's A cirrhosis: Is clinical evidence of portal hypertension a contraindication? HPB (Oxford) 2013;15:78-84.
[2] Boubaddi M, Marichez A, Adam JP, et al. Comprehensive review of future liver remnant (FLR) assessment and hypertrophy techniques before major hepatectomy: how to assess and manage the FLR. Ann Surg Oncol 2024;31:9205-9220.
[3] Entezari P, Gabr A, Kennedy K, et al. Radiation lobectomy: An overview of concept and applications, technical considerations, outcomes. Semin Intervent Radiol 2021;38:419-424.
[4] Heimbach JK. Evolution of liver transplant selection criteria and U.S. allocation policy for patients with hepatocellular carcinoma. Semin Liver Dis 2020;40:358-364.
[5] Kamath PS, Wiesner RH, Malinchoc M, et al. A model to predict survival in patients with end-stage liver disease. Hepatology 2001:33:464-470.
[6] Rudnick SR, Russo MW. Liver transplantation beyond or downstaging within the Milan criteria for hepatocellular carcinoma. Expert Rev Gastroenterol Hepatol 2018;12:265-275.
[7] Faber W, Stockmann M, Schirmer C, et al. Significant impact of patient age on outcome after liver resection for HCC cirrhosis. Eur J Surg Oncol 2014;40:208-213.

Note: All recommendations are category 2A unless otherwise indicated.

Version 2.2025, 10/22/25 © 2025 National Comprehensive Cancer Network® (NCCN®), All rights reserved. NCCN Guidelines® and this illustration may not be reproduced in any form without the express written permission of NCCN.

PLEASE NOTE that use of this NCCN Content is governed by the End-User License Agreement, and you MAY NOT distribute this Content or use it with any artificial intelligence model or tool.
Printed by Galya Basol Kochav on 1/5/2026 10:54:24 AM. Copyright © 2026 National Comprehensive Cancer Network, Inc. All Rights Reserved.

PRINCIPLES OF LOCOREGIONAL THERAPY

I. General Principles

- All patients with HCC should be evaluated for potential curative therapies (resection, transplantation, and for small lesions, ablative strategies). Locoregional therapy should be considered in patients who are not candidates for surgical curative treatments, or as a part of a strategy to bridge patients for other curative therapies. These are broadly categorized into ablation, arterially directed therapies, and radiotherapy. Multidisciplinary review is recommended.

II. Treatment Information

A. Ablation (microwave/radiofrequency, surgical, or percutaneous ethanol injection):

- All tumors should be amenable to ablation such that the tumor and, in the case of thermal ablation, a margin of normal tissue is treated. A margin is not expected following percutaneous ethanol injection.
- Tumors should be in a location accessible for percutaneous/laparoscopic/open approaches for ablation.
- Caution should be exercised when ablating lesions near major vessels, major bile ducts, diaphragm, and other intra-abdominal organs.
- Ablation alone may be curative in treating tumors ≤3 cm. In well-selected patients with small properly located tumors, ablation should be considered as definitive treatment in the context of a multidisciplinary review. Lesions 3 to 5 cm may be treated to prolong survival using arterially directed therapies, or with combination of an arterially directed therapy and ablation as long as tumor location is accessible for ablation.[1-3]
- Unresectable/inoperable lesions >5 cm should be considered for treatment using arterially directed therapy, systemic therapy, or RT.[4-6]

B. Arterially Directed Therapies:

- All tumors irrespective of location may be amenable to arterially directed therapies provided that the arterial blood supply to the tumor may be isolated without excessive non-target treatment.
- Arterially directed therapies include bland transarterial embolization (TAE),[4,5,7,8] chemoembolization (transarterial chemoembolization [TACE][9] and TACE with drug-eluting beads [DEB-TACE]),[4,10] and radioembolization (RE) with yttrium-90 (Y-90) microspheres.[11,12]
- All arterially directed therapies are relatively contraindicated in patients with bilirubin > 3 mg/dL unless segmental treatment can be performed.[13] RE with Y-90 microspheres has an increased risk of radiation-induced liver disease in patients with bilirubin > 2 mg/dL.[12]
  - With RE, delivery of 205 Gy or more to the tumor may be associated with increased overall survival.[14]
  - A dose of >400 Gy to 25% of the liver or less in patients with CTP A liver function is recommended.[15,16] For anatomically limited disease, radiation segmentectomy with Y-90 or ablative dose stereotactic body radiation therapy (SBRT) should be considered.[17-19]
- Arterially directed therapies in highly selected patients have been shown to be safe in the presence of limited tumor invasion of the portal vein.
  - Randomized controlled trials have shown that Y-90 is not superior to sorafenib for treating advanced HCC. RE may be appropriate in some patients with advanced HCC,[20,21] specifically patients with segmental or lobar portal vein, rather than main portal vein thrombosis.[22]
- Systemic therapy may be appropriate following arterially directed therapies in patients with adequate liver function once bilirubin returns to baseline if there is evidence of residual/recurrent tumor not amenable to additional local therapies.

References on HCC-G 2 of 2

Note: All recommendations are category 2A unless otherwise indicated.

Version 2.2025, 10/22/25 © 2025 National Comprehensive Cancer Network® (NCCN®), All rights reserved. NCCN Guidelines® and this illustration may not be reproduced in any form without the express written permission of NCCN.

PLEASE NOTE that use of this NCCN Content is governed by the End-User License Agreement, and you MAY NOT distribute this Content or use it with any artificial intelligence model or tool.
Printed by Galya Basol Kochav on 1/5/2026 10:54:24 AM. Copyright © 2026 National Comprehensive Cancer Network, Inc. All Rights Reserved.

PRINCIPLES OF LOCOREGIONAL THERAPY
REFERENCES

[1] Chen MS, Li JQ, Zheng Y, et al. A prospective randomized trial comparing percutaneous local ablative therapy and partial hepatectomy for small hepatocellular carcinoma. Ann Surg 2006;243:321-328.
[2] Feng K, Yan J, Li X, et al. A randomized controlled trial of radiofrequency ablation and surgical resection in the treatment of small hepatocellular carcinoma. J Hepatol 2012;57:794-802.
[3] Peng ZW, Zhang YJ, Liang HH, et al. Recurrent hepatocellular carcinoma treated with sequential transcatheter arterial chemoembolization and RF ablation versus RF ablation alone: a prospective randomized trial. Radiology 2012;262:689-700.
[4] Malagari K, Pomoni M, Kelekis A, et al. Prospective randomized comparison of chemoembolization with doxorubicin-eluting beads and bland embolization with BeadBlock for hepatocellular carcinoma. Cardiovasc Intervent Radiol 2010;33:541-551.
[5] Maluccio M, Covey AM, Gandhi R, et al. Comparison of survival rates after bland arterial embolization and ablation versus surgical resection for treating solitary hepatocellular carcinoma up to 7 cm. J Vasc Interv Radiol 2005;16:955-961.
[6] Yamakado K, Nakatsuka A, Takaki H, et al. Early-stage hepatocellular carcinoma: radiofrequency ablation combined with chemoembolization versus hepatectomy. Radiology 2008;247:260-266.
[7] Brown KT, Do RT, Gonen M, et al. Randomized trial of hepatic artery embolization for hepatocellular carcinoma using doxorubicin-eluting microspheres compared with embolization with microspheres alone. J Clin Oncol 2016;34:2046-2053.
[8] Maluccio MA, Covey AM, Porat LB, et al. Transcatheter arterial embolization with only particles for the treatment of unresectable hepatocellular carcinoma. J Vasc Interv Radiol 2008;19:862-869.
[9] Llovet JM, Real MI, Montana X, et al. Arterial embolisation or chemoembolisation versus symptomatic treatment in patients with unresectable hepatocellular carcinoma: a randomised controlled trial. Lancet 2002;359:1734-1739.
[10] Lammer J, Malagari K, Vogl T, et al. Prospective randomized study of doxorubicin-eluting-bead embolization in the treatment of hepatocellular carcinoma: results of the PRECISION V study. Cardiovasc Intervent Radiol 2010;33:41-52.
[11] Kulik LM, Carr BI, Mulcahy MF, et al. Safety and efficacy of 90Y radiotherapy for hepatocellular carcinoma with and without portal vein thrombosis. Hepatology 2008;47:71-81.
[12] Salem R, Lewandowski RJ, Mulcahy MF, et al. Radioembolization for hepatocellular carcinoma using Yttrium-90 microspheres: a comprehensive report of long-term outcomes. Gastroenterology 2010;138:52-64.
[13] Ramsey DE, Kernagis LY, Soulen MC, Geschwind J-FH. Chemoembolization of hepatocellular carcinoma. J Vasc Interv Radiol 2002;13:211-221.
[14] Garin E, Tselikas L, Guiu B, et al; DOSISPHERE-01 Study Group. Personalised versus standard dosimetry approach of selective internal radiation therapy in patients with locally advanced hepatocellular carcinoma (DOSISPHERE-01): a randomised, multicentre, open-label phase 2 trial. Lancet Gastroenterol Hepatol 2021;6:17-29.
[15] Gabr A, Riaz A, Johnson GE, et al. Correlation of Y90-absorbed radiation dose to pathological necrosis in hepatocellular carcinoma: confirmatory multicenter analysis in 45 explants. Eur J Nucl Med Mol Imaging 2021;48:580-583.
[16] De la Garza-Ramos C, Overfield CJ, Montazeri SA, et al. Biochemical safety of ablative yttrium-90 radioembolization for hepatocellular carcinoma as a function of percent liver treated. J Hepatocell Carcinoma 2021;8:861-870.
[17] Serhal M, Dadrass F, Kim E, Lewandowski RJ. Radiation segmentectomy for hepatocellular carcinoma. Curr Oncol 2024;31:617-628.
[18] Kim E, Sher A, Abboud G, et al. Radiation segmentectomy for curative intent of unresectable very early to early stage hepatocellular carcinoma (RASER): a single-centre, single-arm study. Lancet Gastroenterol Hepatol 2022;7:843-850.
[19] Lewandowski RJ, Gabr A, Abouchaleh N, et al. Radiation segmentectomy: Potential curative therapy for early hepatocellular carcinoma. Radiology 2018;287:1050-1058.
[20] Vilgrain V, Pereira H, Assenat E, et al. Efficacy and safety of selective internal radiotherapy with yttrium-90 resin microspheres compared with sorafenib in locally advanced and inoperable hepatocellular carcinoma (SARAH): an open-label randomised controlled phase 3 trial. Lancet Oncol 2017;18:1624-1636.
[21] Chow PKH, Gandhi M, Tan SB, et al. SIRveNIB: Selective Internal Radiation Therapy Versus Sorafenib in Asia-Pacific Patients With Hepatocellular Carcinoma. J Clin Oncol 2018;36:1913-1921.
[22] Ricke J, Klümpen HJ, Amthauer H, et al. Impact of combined selective internal radiation therapy and sorafenib on survival in advanced hepatocellular carcinoma. J Hepatol 2019;71:1164-1174.

Note: All recommendations are category 2A unless otherwise indicated.

Version 2.2025, 10/22/25 © 2025 National Comprehensive Cancer Network® (NCCN®), All rights reserved. NCCN Guidelines® and this illustration may not be reproduced in any form without the express written permission of NCCN.

PLEASE NOTE that use of this NCCN Content is governed by the End-User License Agreement, and you MAY NOT distribute this Content or use it with any artificial intelligence model or tool.
Printed by Galya Basol Kochav on 1/5/2026 10:54:24 AM. Copyright © 2026 National Comprehensive Cancer Network, Inc. All Rights Reserved.

PRINCIPLES OF RADIATION THERAPY

- **Treatment Modalities[1]:**
  - **RT is a treatment option for patients with unresectable disease, or for those who are medically inoperable due to comorbidity.**
  - **All tumors irrespective of the location may be amenable to RT (3D conformal RT, intensity-modulated RT [IMRT], or SBRT). Image-guided RT is strongly recommended when using RT, IMRT, and SBRT to improve treatment accuracy and reduce treatment-related toxicity.**
  - **Hypofractionation with photons[2] or protons[2,3] is an acceptable option for intrahepatic tumors, although treatment at centers with experience is recommended.**
  - **SBRT is an advanced technique of hypofractionated RT with photons that delivers large ablative doses of radiation.**
  - **There is growing evidence for the usefulness of SBRT in the management of HCC.[4,5] SBRT can be considered as an alternative to ablation/embolization techniques or when these therapies have failed or are contraindicated.[6]**
  - **SBRT (typically 3–5 fractions) is often used for patients with 1 to 3 tumors. SBRT could be considered for larger lesions or more extensive disease, if there is sufficient uninvolved liver and liver radiation tolerance can be respected. There should be no extrahepatic disease or it should be minimal and addressed in a comprehensive management plan. The majority of data on radiation for HCC liver tumors arises from patients with CTP A liver disease; safety data are limited for patients with CTP B or poorer liver function. Those with CTP B cirrhosis can be safely treated, but they may require dose modifications and strict dose constraint adherence.[7] The safety of liver radiation for HCC in patients with CTP C cirrhosis has not been established, as there are not likely to be clinical trials available for these patients.[8,9]**
  - **Proton beam therapy may be appropriate in specific situations.[10,11]**
  - **Palliative RT is appropriate for symptom control and/or prevention of complications from metastatic HCC lesions, such as bone or brain, and extensive liver tumor burden.[12]**

- **RT dosing,[1] depending on the ability to meet normal organ constraints and underlying liver function:**
  - **RT: SBRT or hypofractionation preferred**
    - ◊ **SBRT: Doses ranging between 40–60 Gy (in 3–5 fractions; BED10 > 100 Gy) is preferred if dose constraints can be met.[1]**
    - ◊ **Hypofractionation[2]**
      - **– 37.5–72 Gy in 10–15 fractions**
    - ◊ **Conventional fractionation[13,14]:**
      - **– 50–66 Gy in 25–33 fractions**

References on HCC-H 2 of 2

Note: All recommendations are category 2A unless otherwise indicated.

Version 2.2025, 10/22/25 © 2025 National Comprehensive Cancer Network® (NCCN®), All rights reserved. NCCN Guidelines® and this illustration may not be reproduced in any form without the express written permission of NCCN.

PLEASE NOTE that use of this NCCN Content is governed by the End-User License Agreement, and you MAY NOT distribute this Content or use it with any artificial intelligence model or tool.
Printed by Galya Basol Kochav on 1/5/2026 10:54:24 AM. Copyright © 2026 National Comprehensive Cancer Network, Inc. All Rights Reserved.

PRINCIPLES OF RADIATION THERAPY
REFERENCES

[1] Apisarnthanarax S, Barry A, Cao M, et al. External beam radiation therapy for primary liver cancers: An ASTRO Clinical Practice Guideline. Pract Radiat Oncol 2022;12:28-51.
[2] Hong TS, Wo JY, Yeap BY, et al. Multi-institutional phase II study of high-dose hypofractionated proton beam therapy in patients with localized, unresectable hepatocellular carcinoma and intrahepatic cholangiocarcinoma. J Clin Oncol 2016;34:460-468.
[3] Bush DA, Smith JC, Slater JD, et al. Randomized clinical trial comparing proton beam radiation therapy with transarterial chemoembolization for hepatocellular carcinoma: results of an interim analysis. Int J Radiat Oncol Biol Phys 2016;95:477-482.
[4] Hoffe SE, Finkelstein SE, Russell MS, Shridhar R. Nonsurgical options for hepatocellular carcinoma: evolving role of external beam radiotherapy. Cancer Control 2010;17:100-110.
[5] Wahl DR, Stenmark MH, Tao Y, et al. Outcomes after stereotactic body radiotherapy or radiofrequency ablation for hepatocellular carcinoma. J Clin Oncol 2016;34:452-459.
[6] Dawson LA, Winter KA, Knox JJ, et al. NRG/RTOG 1112: Stereotactic body radiotherapy vs sorafenib alone in hepatocellular carcinoma: the NRG Oncology/RTOG 1112 phase 3 randomized clinical trial. JAMA Oncol 2025;11:136-144.
[7] Cardenes HR, Price TR, Perkins SM, et al. Phase I feasibility trial of stereotactic body radiation therapy for primary hepatocellular carcinoma. Clin Transl Oncol 2010;12:218-225.
[8] Andolino DL, Johnson CS, Maluccio M, et al. Stereotactic body radiotherapy for primary hepatocellular carcinoma. Int J Radiat Oncol Biol Phys 2011;81:e447-453.
[9] Bujold A, Massey CA, Kim JJ, et al. Sequential phase I and II trials of stereotactic body radiotherapy for locally advanced hepatocellular carcinoma. J Clin Oncol 2013;31:1631-1639.
[10] Proton beam therapy model policy. American Society for Radiation Oncology 2023. Available at: https://www.astro.org/ASTRO/media/ASTRO/Daily%20Practice/PDFs/ASTROPBTModelPolicy.pdf. Accessed February 27, 2024.
[11] Qi W, Fu S, Zhang Q, et al. Charged particle therapy versus photon therapy for patients with hepatocellular carcinoma: A systematic review and meta-analysis. Radiother Oncol 2015;114:289-295.
[12] Soliman H, Ringash J, Jiang H, et al. Phase II trial of palliative radiotherapy for hepatocellular carcinoma and liver metastases. J Clin Oncol 2013;31:3980-3986.
[13] Seong J, Lee IJ, Shim SJ, et al. A multicenter retrospective cohort study of practice patterns and clinical outcome on radiotherapy for hepatocellular carcinoma in Korea. Liver Int 2009;29:147-152.
[14] Ben-Josef E, Lawrence TS. Radiotherapy for unresectable hepatic malignancies. Semin Radiat Oncol 2005;15:273-278.

Note: All recommendations are category 2A unless otherwise indicated.

Version 2.2025, 10/22/25 © 2025 National Comprehensive Cancer Network® (NCCN®), All rights reserved. NCCN Guidelines® and this illustration may not be reproduced in any form without the express written permission of NCCN.

PLEASE NOTE that use of this NCCN Content is governed by the End-User License Agreement, and you MAY NOT distribute this Content or use it with any artificial intelligence model or tool.
Printed by Galya Basol Kochav on 1/5/2026 10:54:24 AM. Copyright © 2026 National Comprehensive Cancer Network, Inc. All Rights Reserved.

PRINCIPLES OF SYSTEMIC THERAPY[a-d]

First-Line Systemic Therapy

Preferred Regimens

- Atezolizumab[e] + bevacizumab (category 1)[f,g,h,1]
- Tremelimumab-actl + durvalumab (category 1)[f,i,2]

Other Recommended Regimens

- Durvalumab (category 1)[f,h,2]
- Lenvatinib (category 1)[3,4]
- Sorafenib (category 1)[5,6]
- Tislelizumab-jsgr (category 1)[f,h,7]
- Nivolumab + ipilimumab[f,i,j,8-11]
- Pembrolizumab (category 2B)[f,h,k,12-15]

Useful in Certain Circumstances

- None

Subsequent-Line Systemic Therapy if Disease Progression[l,m]

Options

- Cabozantinib (category 1)[16]
- Regorafenib (category 1)[17]

Other Recommended Regimens

- Consider Preferred and Other Recommended Regimens for First-Line Systemic Therapy above

Useful in Certain Circumstances

- Ramucirumab (AFP ≥400 ng/mL) (category 1)[18]
- Nivolumab[f,h,n,19-22]
- For MSI-H/dMMR tumors
  - Dostarlimab-gxly (category 2B)[f,h,o,23]
- For *RET* gene fusion-positive tumors:
  - Selpercatinib (category 2B)[24]
- For *NTRK* gene fusion-positive tumors[p]:
  - Entrectinib[25]
  - Larotrectinib[26]
  - Repotrectinib[27]

[a] An FDA-approved biosimilar is an appropriate substitute for any recommended systemic biologic therapy in the NCCN Guidelines.
[b] Order does not indicate preference.
[c] See Principles of Liver Functional Assessment (HCC-E) and assess portal hypertension (eg, varices, splenomegaly, thrombocytopenia).
[d] Caution: Therapies listed may have limited safety data available for CTP Class B or C liver function. Use with extreme caution in patients with elevated bilirubin levels. Consult the prescribing information for individual agents.
[e] Atezolizumab and hyaluronidase-tqjs subcutaneous injection may be substituted for IV atezolizumab. Atezolizumab and hyaluronidase-tqjs has different dosing and administration instructions compared to atezolizumab for intravenous infusion.
[f] See NCCN Guidelines for Management of Immunotherapy-Related Toxicities.
[g] Patients on atezolizumab + bevacizumab should have adequate endoscopic evaluation and management for esophageal varices within approximately 6 months prior to treatment or according to institutional practice and based on the assessment of bleeding risk.
[h] For patients who have not been previously treated with a checkpoint inhibitor when used as subsequent-line therapy because there is a lack of data for subsequent use of single agent immunotherapy in patients who have previously been treated with a checkpoint inhibitor.
[i] For patients who have not been previously treated with anti-CTLA4-based combinations when used as subsequent-line therapy.
[j] Nivolumab and hyaluronidase-nvhy is not approved for concurrent use with IV ipilimumab; however, for nivolumab monotherapy, nivolumab and hyaluronidase-nvhy subcutaneous injection may be substituted for IV nivolumab. Nivolumab and hyaluronidase-nvhy has different dosing and administration instructions compared to IV nivolumab.
[k] Pembrolizumab is a recommended treatment option for patients with or without microsatellite instability-high (MSI-H) HCC. Pembrolizumab is FDA-approved for MSI-H tumors in the subsequent-line setting.
[l] Regimens with first-line data are reasonable to consider for subsequent-line treatment, if not previously used. There are no comparative data to define optimal treatment after first-line systemic therapy.
[m] Principles of Molecular Testing (HCC-J).
[n] Nivolumab and hyaluronidase-nvhy subcutaneous injection may be substituted for IV nivolumab. Nivolumab and hyaluronidase-nvhy has different dosing and administration instructions compared to IV nivolumab.
[o] Dostarlimab-gxly is a recommended treatment option for patients with MSI-H/mismatch repair deficient (dMMR) recurrent or advanced tumors that have progressed on or following prior treatment and who have no satisfactory alternative treatment options.
[p] *NTRK* gene fusion-positive tumors are extremely rare in HCC.

Note: All recommendations are category 2A unless otherwise indicated.

References on HCC-I 2 of 2

Version 2.2025, 10/22/25 © 2025 National Comprehensive Cancer Network® (NCCN®), All rights reserved. NCCN Guidelines® and this illustration may not be reproduced in any form without the express written permission of NCCN.

PLEASE NOTE that use of this NCCN Content is governed by the End-User License Agreement, and you MAY NOT distribute this Content or use it with any artificial intelligence model or tool.
Printed by Galya Basol Kochav on 1/5/2026 10:54:24 AM. Copyright © 2026 National Comprehensive Cancer Network, Inc. All Rights Reserved.

PRINCIPLES OF SYSTEMIC THERAPY
REFERENCES

[1] Cheng AL, Qin S, Ikeda M, et al. Updated efficacy and safety data from IMbrave150: Atezolizumab plus bevacizumab vs. sorafenib for unresectable hepatocellular carcinoma. J Hepatol 2022;76:862-873.
[2] Abou-Alfa GK, Lau G, Kudo M, et al. Tremelimumab plus durvalumab in unresectable hepatocellular carcinoma. NEJM Evid 2022;1:EVIDoa2100070.
[3] Kudo M, Finn RS, Qin S, et al. Lenvatinib versus sorafenib in first-line treatment of patients with unresectable hepatocellular carcinoma: a randomised phase 3 non-inferiority trial. Lancet 2018;391:1163-1173.
[4] Alsina A, Kudo M, Vogel A, et al. Effects of subsequent systemic anticancer medication following first-line lenvatinib: A post hoc responder analysis from the phase 3 REFLECT study in unresectable hepatocellular carcinoma. Liver Cancer 2020;9:93-104.
[5] Llovet JM, Ricci S, Mazzaferro V, et al. Sorafenib in advanced hepatocellular carcinoma. N Engl J Med 2008;359:378-390.
[6] Cheng AL, Kang YK, Chen Z, et al. Efficacy and safety of sorafenib in patients in the Asia-Pacific region with advanced hepatocellular carcinoma: a phase III randomised, double-blind, placebo-controlled trial. Lancet Oncol 2009;10:25-34.
[7] Qin S, Kudo M, Meyer T, et al. Tislelizumab vs sorafenib as first-Line treatment for unresectable hepatocellular carcinoma: A phase 3 randomized clinical trial. JAMA Oncol 2023;9:1651-1659.
[8] Galle PR, Decaens T, Kudo M, et al. Nivolumab (NIVO) plus ipilimumab (IPI) vs lenvatinib (LEN) or sorafenib (SOR) as first-line treatment for unresectable hepatocellular carcinoma (uHCC): First results from CheckMate 9DW [abstract]. J Clin Oncol 2024;24:Abstract LBA4008.
[9] Yau T, Kang YK, Kim TY, et al. Efficacy and safety of nivolumab plus ipilimumab in patients with advanced hepatocellular carcinoma previously treated with sorafenib: The CheckMate 040 randomized clinical trial. JAMA Oncol 2020;6:e204564.
[10] Alden SL, Lim M, Kao C, et al. Salvage ipilimumab plus nivolumab after anti-PD-1/PD-L1 therapy in advanced hepatocellular carcinoma. Cancer Res Commun 2023;3:1312-1317.
[11] Roessler D, Öcal O, Philipp AB, et al. Ipilimumab and nivolumab in advanced hepatocellular carcinoma after failure of prior immune checkpoint inhibitor-based combination therapies: A multicenter retrospective study. J Cancer Res Clin Oncol 2023;149:3065-3073.
[12] Verset G, Borbath I, Karwal M, et al. Pembrolizumab monotherapy for previously untreated advanced hepatocellular carcinoma: Data from the open-label, phase II KEYNOTE-224 trial. Clin Cancer Res 2022;28:2547-2554.
[13] Zhu AX, Finn RS, Edeline J, et al. Pembrolizumab in patients with advanced hepatocellular carcinoma previously treated with sorafenib (KEYNOTE-224): a non-randomised, open-label phase 2 trial. Lancet Oncol 2018;19:940-952.
[14] Finn RS, Ryoo BY, Merle P, et al. Pembrolizumab as second-line therapy in patients with advanced hepatocellular carcinoma in KEYNOTE-240: A randomized, double-blind, phase III trial. J Clin Oncol 2020; 38:193-202.
[15] Qin S, Chen Z, Fang W, et al. Pembrolizumab versus placebo as second-line therapy in patients from Asia with advanced hepatocellular carcinoma: A randomized, double-blind, phase III trial. J Clin Oncol 2023;41:1434-1443.
[16] Abou-Alfa GK, Meyer T, Cheng AL, et al. Cabozantinib in patients with advanced and progressing hepatocellular carcinoma. N Engl J Med 2018;379:54-63.
[17] Bruix J, Qin S, Merle P, et al. Regorafenib for patients with hepatocellular carcinoma who progressed on sorafenib treatment (RESORCE): a randomized, double-blind, placebo-controlled, phase 3 trial. Lancet 2017;389:56-66.
[18] Zhu AX, Kang YK, Yen CJ, et al. Ramucirumab after sorafenib in patients with advanced hepatocellular carcinoma and increased α-fetoprotein concentrations (REACH-2): A randomised, double-blind, placebo-controlled, phase 3 trial. Lancet Oncol 2019;20:282-296.
[19] El-Khoueiry AB, Sangro B, Yau T, et al. Nivolumab in patients with advanced hepatocellular carcinoma (CheckMate 040): an open-label, non-comparative, phase 1/2 dose escalation and expansion trial. Lancet 2017;389:2492-2502.
[20] Kudo M, Matilla A, Santoro A, et al. Checkmate 040 cohort 5: A phase I/II study of nivolumab in patients with advanced hepatocellular carcinoma and Child-Pugh B cirrhosis. J Hepatol 2021;75:600-609.
[21] Matilla A, Sangro B, El-Khoureiry A, et al. Checkmate 040 cohort 5: Long-term efficacy and safety of nivolumab in patients with Child-Pugh B advanced hepatocellular carcinoma: Associations between baseline biomarker analyses and outcomes [abstract]. J Hepatol 2021;75:Abstract OS-295.
[22] Kambhampati S, Bauer KE, Bracci PM, et al. Nivolumab in patients with advanced hepatocellular carcinoma and Child-Pugh class B cirrhosis: safety and clinical outcomes in a retrospective case series. Cancer 2019;125:3234-3241.
[23] André T, Berton D, Curigliano G, et al. Antitumor activity and safety of dostarlimab monotherapy in patients with mismatch repair deficient solid tumors. JAMA Netw Open 2023;6:e2341165.
[24] Subbiah V, Wolf J, Konda B, et al. Tumour-agnostic efficacy and safety of selpercatinib in patients with RET fusion-positive solid tumours other than lung or thyroid tumours (LIBRETTO-001): A phase 1/2, open-label, basket trial. Lancet Oncol 2022;23:1261-1273.
[25] Doebele RC, Drilon A, Paz-Ares L, et al. Entrectinib in patients with advanced or metastatic NTRK fusion-positive solid tumours: Integrated analysis of three phase 1-2 trials Lancet Oncol 2020;21:271-282.
[26] Drilon A, Laetsch TW, Kummar S, et al. Efficacy of larotrectinib in TRK fusion-positive cancers in adults and children N Engl J Med 2018;378:731-739.
[27] Solomon BJ, Drilon A, Lin JJ, et al. Repotrectinib in patients with NTRK fusion-positive advanced solid tumors, including non-small cell lung cancer: Update from the phase 1/2 TRIDENT-1 trial [abstract]. Ann Oncol 2023;34:Abstract 1372P.

Note: All recommendations are category 2A unless otherwise indicated.

Version 2.2025, 10/22/25 © 2025 National Comprehensive Cancer Network® (NCCN®), All rights reserved. NCCN Guidelines® and this illustration may not be reproduced in any form without the express written permission of NCCN.

PLEASE NOTE that use of this NCCN Content is governed by the End-User License Agreement, and you MAY NOT distribute this Content or use it with any artificial intelligence model or tool.
Printed by Galya Basol Kochav on 1/5/2026 10:54:24 AM. Copyright © 2026 National Comprehensive Cancer Network, Inc. All Rights Reserved.

PRINCIPLES OF MOLECULAR TESTING

- **Hepatocellular carcinomas are associated with a range of molecular alterations, including activation of oncogenic signaling pathways, such as *Wnt-TGFβ, PI3K-AKT-mTOR, RAS-MAPK, MET, IGF,* and *Wnt-β-catenin; TP53* and *TERT* promotor mutations are also common.[1] To date, however, there are no treatments with differential benefit for specific molecularly defined subgroups of HCC.**

- **Molecular profiling in HCC: There is no established indication for routine molecular profiling in HCC, but it should be considered on a case-by-case basis. Clinical trials of molecular profiling and/or targeted therapies are encouraged in this population. Tumor molecular testing may be warranted in patients with atypical histology, cHCC-CCA histology, unusual clinical presentations, or for clinical trial enrollment.**

- **Germline testing in hepatobiliary cancers: Evidence remains insufficient for definitive recommendations regarding specific criteria to guide genetic risk assessment in hepatobiliary cancers or for universal germline testing in these tumors.**

Immunotherapy Biomarkers (MSI-H/dMMR/TMB-H, PD-L1)

Recommendation:
- **There is no established role for microsatellite instability (MSI), mismatch repair (MMR), tumor mutational burden (TMB), or programmed death ligand 1 (PD-L1) testing in HCC at this time. Immune checkpoint inhibition has shown clinical benefit leading to regulatory approvals in patients with HCC without selection for MSI, MMR, TMB, or PD-L1 status.[2-5]**

[1] Llovet JM, Kelley RK, Villanueva A, et al. Hepatocellular carcinoma. Nat Rev Dis Primers 2021;7:6.
[2] El-Khoueiry AB, Sangro B, Yau T, et al. Nivolumab in patients with advanced hepatocellular carcinoma (CheckMate 040): an open-label, non-comparative, phase 1/2 dose escalation and expansion trial. Lancet 2017;389:2492-2502.
[3] Zhu AX, Finn RS, Edeline J, et al. Pembrolizumab in patients with advanced hepatocellular carcinoma previously treated with sorafenib (KEYNOTE-224): a non-randomised, open-label phase 2 trial. Lancet Oncol 2018;19:940-952.
[4] Cheng AL, Qin S, Ikeda M, et al. Updated efficacy and safety data from IMbrave150: Atezolizumab plus bevacizumab vs. sorafenib for unresectable hepatocellular carcinoma. J Hepatol 2022;76:862-873.
[5] Finn RS, Ryoo BY, Merle P, et al. Pembrolizumab as second-line therapy in patients with advanced hepatocellular carcinoma in KEYNOTE-240: A randomized, double-blind, phase III trial. J Clin Oncol 2020;38:193-202.

Note: All recommendations are category 2A unless otherwise indicated.

Version 2.2025, 10/22/25 © 2025 National Comprehensive Cancer Network® (NCCN®), All rights reserved. NCCN Guidelines® and this illustration may not be reproduced in any form without the express written permission of NCCN.

PLEASE NOTE that use of this NCCN Content is governed by the End-User License Agreement, and you MAY NOT distribute this Content or use it with any artificial intelligence model or tool.
Printed by Galya Basol Kochav on 1/5/2026 10:54:24 AM. Copyright © 2026 National Comprehensive Cancer Network, Inc. All Rights Reserved.

American Joint Committee on Cancer (AJCC)
TNM Staging for Hepatocellular Cancer (8th ed., 2017)

Table 1. **Definitions for T, N, M**

T	Primary Tumor
TX	Primary tumor cannot be assessed
T0	No evidence of primary tumor
T1	Solitary tumor ≤2 cm, or >2 cm without vascular invasion
T1a	Solitary tumor ≤2 cm
T1b	Solitary tumor >2 cm without vascular invasion
T2	Solitary tumor >2 cm with vascular invasion, or multiple tumors, none >5 cm
T3	Multiple tumors, at least one of which is >5 cm
T4	Single tumor or multiple tumors of any size involving a major branch of the portal vein or hepatic vein, or tumor(s) with direct invasion of adjacent organs other than the gallbladder or with perforation of visceral peritoneum

N	Regional Lymph Nodes
NX	Regional lymph nodes cannot be assessed
N0	No regional lymph node metastasis
N1	Regional lymph node metastasis

M	Distant Metastasis
M0	No distant metastasis
M1	Distant metastasis

Table 2. **AJCC Prognostic Groups**

	T	N	M
Stage IA	T1a	N0	M0
Stage IB	T1b	N0	M0
Stage II	T2	N0	M0
Stage IIIA	T3	N0	M0
Stage IIIB	T4	N0	M0
Stage IVA	Any T	N1	M0
Stage IVB	Any T	Any N	M1

Histologic Grade (G)

GX	Grade cannot be accessed
G1	Well differentiated
G2	Moderately differentiated
G3	Poorly differentiated
G4	Undifferentiated

Fibrosis Score (F)

The fibrosis score as defined by Ishak is recommended because of its prognostic value in overall survival. This scoring system uses a 0-6 scale.

F0	Fibrosis score 0-4 (none to moderate fibrosis)
F1	Fibrosis score 5-6 (severe fibrosis or cirrhosis)

Used with permission of the American College of Surgeons, Chicago, Illinois. The original source for this information is the AJCC Cancer Staging Manual, Eighth Edition (2017) published by Springer International Publishing.

Continued

Version 2.2025, 10/22/25 © 2025 National Comprehensive Cancer Network® (NCCN®), All rights reserved. NCCN Guidelines® and this illustration may not be reproduced in any form without the express written permission of NCCN.

PLEASE NOTE that use of this NCCN Content is governed by the End-User License Agreement, and you MAY NOT distribute this Content or use it with any artificial intelligence model or tool.
Printed by Galya Basol Kochav on 1/5/2026 10:54:24 AM. Copyright © 2026 National Comprehensive Cancer Network, Inc. All Rights Reserved.

Barcelona Clinic Liver Cancer (BCLC) Staging System (2022)[1]

Table 1. **Definitions for Prognostic Groups**

Stage	Definition
Very early stage (0)	• Single ≤2 cm • Preserved liver function,[a] PS 0
Early stage (A)	• Single, or ≤3 nodules each ≤3 cm • Preserved liver function,[a] PS 0
Intermediate stage (B)	• Multinodular • Preserved liver function,[a] PS 0
Advanced stage (C)	• Portal invasion and/or extrahepatic spread • Preserved liver function, PS 1-2
Terminal stage (D)	• Any tumor burden • End stage liver function, PS 3-4

[a] Except for those with tumor burden acceptable for transplant.

[1] Adapted with permission from Reig M, Forner A, Rimola J, et al. BCLC strategy for prognosis prediction and treatment recommendation: The 2022 update. J Hepatol 2022;76:681-693.

Version 2.2025, 10/22/25 © 2025 National Comprehensive Cancer Network® (NCCN®), All rights reserved. NCCN Guidelines® and this illustration may not be reproduced in any form without the express written permission of NCCN.

PLEASE NOTE that use of this NCCN Content is governed by the End-User License Agreement, and you MAY NOT distribute this Content or use it with any artificial intelligence model or tool.
Printed by Galya Basol Kochav on 1/5/2026 10:54:24 AM. Copyright © 2026 National Comprehensive Cancer Network, Inc. All Rights Reserved.

ABBREVIATIONS

AASLD	American Association for the Study of Liver Diseases
ALBI	Albumin-Bilirubin
AFP	alpha fetoprotein
CCA	cholangiocarcinoma
CEUS	contrast-enhanced ultrasound
CHB	chronic hepatitis B
cHCC-CCA	combined hepatocellular carcinoma-cholangiocarcinoma
CTP	Child-Turcotte-Pugh
DEB	drug-eluting beads
dMMR	mismatch repair deficient
HBcAb	hepatitis B core antibody
HBsAg	hepatitis B surface antigen
HBV	hepatitis B virus
HCC	hepatocellular carcinoma
HCV	hepatitis C virus
iCCA	intrahepatic cholangiocarcinoma
IMRT	intensity-modulated radiation therapy
INR	international normalized ratio
LI-RADS	Liver Imaging Reporting and Data System
MASLD	metabolic dysfunction-associated steatotic liver disease
MELD	Model for End-Stage Liver Disease
MMR	mismatch repair
MSI	microsatellite instability
MSI-H	microsatellite instability-high
OPTN	Organ Procurement and Transplantation Network
PD-L1	programmed death ligand 1
RE	radioembolization
SBRT	stereotactic body radiation therapy
TACE	transarterial chemoembolization
TAE	transarterial embolization
TMB	tumor mutational burden
TMB-H	tumor mutational burden-high
UNOS	United Network for Organ Sharing

Version 2.2025, 10/22/25 © 2025 National Comprehensive Cancer Network® (NCCN®), All rights reserved. NCCN Guidelines® and this illustration may not be reproduced in any form without the express written permission of NCCN.

PLEASE NOTE that use of this NCCN Content is governed by the End-User License Agreement, and you MAY NOT distribute this Content or use it with any artificial intelligence model or tool.
Printed by Galya Basol Kochav on 1/5/2026 10:54:24 AM. Copyright © 2026 National Comprehensive Cancer Network, Inc. All Rights Reserved.

NCCN Categories of Evidence and Consensus	
Category 1	Based upon high-level evidence (≥1 randomized phase 3 trials or high-quality, robust meta-analyses), there is uniform NCCN consensus (≥85% support of the Panel) that the intervention is appropriate.
Category 2A	Based upon lower-level evidence, there is uniform NCCN consensus (≥85% support of the Panel) that the intervention is appropriate.
Category 2B	Based upon lower-level evidence, there is NCCN consensus (≥50%, but <85% support of the Panel) that the intervention is appropriate.
Category 3	Based upon any level of evidence, there is major NCCN disagreement that the intervention is appropriate.

All recommendations are category 2A unless otherwise indicated.

NCCN Categories of Preference	
Preferred intervention	Interventions that are based on superior efficacy, safety, and evidence; and, when appropriate, affordability.
Other recommended intervention	Other interventions that may be somewhat less efficacious, more toxic, or based on less mature data; or significantly less affordable for similar outcomes.
Useful in certain circumstances	Other interventions that may be used for selected patient populations (defined with recommendation).

All recommendations are considered appropriate.

PLEASE NOTE that use of this NCCN Content is governed by the End-User License Agreement, and you MAY NOT distribute this Content or use it with any artificial intelligence model or tool.
Printed by Galya Basol Kochav on 1/5/2026 10:54:24 AM. Copyright © 2026 National Comprehensive Cancer Network, Inc. All Rights Reserved.

Discussion

This discussion corresponds to the NCCN Guidelines for Hepatocellular Carcinoma. Last updated: October 22, 2025.

Table of Contents

Overview **MS-2**
Guidelines Update Methodology **MS-2**
Literature Search Criteria **MS-2**
Sensitive/Inclusive Language Usage **MS-2**
Risk Factors and Epidemiology **MS-2**
Screening for HCC **MS-5**
Diagnosis **MS-6**
Imaging MS-6
Serum Biomarkers MS-8
Core Needle Biopsy MS-8
Management of Mixed HCC-CCA **MS-10**
Initial Workup **MS-10**
Assessment of Liver Function MS-11
Pathology and Staging **MS-12**
Pathology MS-12
Staging MS-12
Treatment Options **MS-14**
Surgery MS-14
Liver Transplantation MS-18
Locoregional Therapies MS-21
Systemic Therapy MS-32
Management of Resectable Disease MS-41
Surveillance MS-42
Management of Advanced Disease MS-42
Summary **MS-43**
References **MS-44**

Version 2.2025 © 2025 National Comprehensive Cancer Network© (NCCN©), All rights reserved. NCCN Guidelines® and this illustration may not be reproduced in any form without the express written permission of NCCN.

PLEASE NOTE that use of this NCCN Content is governed by the End-User License Agreement, and you MAY NOT distribute this Content or use it with any artificial intelligence model or tool.
Printed by Galya Basol Kochav on 1/5/2026 10:54:24 AM. Copyright © 2026 National Comprehensive Cancer Network, Inc. All Rights Reserved.

Overview

Hepatocellular carcinoma (HCC) is a primary cancer of the liver. In 2025 it was estimated that 42,240 people in the United States would be diagnosed with liver cancer and intrahepatic bile duct cancer.[1] Approximately 30,090 deaths from liver and intrahepatic bile duct cancer were anticipated.

The NCCN Clinical Practice Guidelines in Oncology (NCCN Guidelines®) for Hepatocellular Carcinoma are the work of the members of the NCCN Hepatocellular Carcinoma Guidelines Panel. By definition, the NCCN Guidelines® cannot incorporate all possible clinical variations and are not intended to replace good clinical judgment or individualization of treatments. Although not explicitly stated at every decision point of the guidelines, participation in prospective clinical trials is encouraged for the treatment of patients with HCC.

Guidelines Update Methodology

The complete details of the Development and Update of the NCCN Guidelines are available at www.NCCN.org.

Literature Search Criteria

Prior to the update of the NCCN Guidelines for Hepatocellular Carcinoma, an electronic search of the PubMed database was performed to obtain key literature in HCC published since the previous Guidelines update, using the following search terms: “hepatocellular carcinoma” OR “liver cancer.” The PubMed database was chosen because it remains the most widely used resource for medical literature and indexes peer-reviewed biomedical literature.[2]

The search results were narrowed by selecting studies in humans published in English. Results were confined to the following article types: Clinical Trial, Phase II; Clinical Trial, Phase III; Clinical Trial, Phase IV; Practice Guideline; Guideline; Randomized Controlled Trials; Meta-Analysis; Systematic Reviews; and Validation Studies. The data from key PubMed articles and articles from additional sources deemed as relevant to these Guidelines as discussed by the Panel during the Guidelines update have been included in this version of the Discussion section. Recommendations for which high-level evidence is lacking are based on the Panel’s review of lower-level evidence and expert opinion.

Sensitive/Inclusive Language Usage

NCCN Guidelines strive to use language that advances the goals of equity, inclusion, and representation.[3] NCCN Guidelines endeavor to use language that is person-first; not stigmatizing; anti-racist, anti-classist, anti-misogynist, anti-ageist, anti-ableist, and anti-weight biased; and inclusive of individuals of all sexual orientations and gender identities. NCCN Guidelines incorporate non-gendered language, instead focusing on organ-specific recommendations. This language is both more accurate and more inclusive and can help fully address the needs of individuals of all sexual orientations and gender identities. NCCN Guidelines will continue to use the terms men, women, female, and male when citing statistics, recommendations, or data from organizations or sources that do not use inclusive terms. Most studies do not report how sex and gender data are collected and use these terms interchangeably or inconsistently. If sources do not differentiate gender from sex assigned at birth or organs present, the information is presumed to predominantly represent cisgender individuals. NCCN encourages researchers to collect more specific data in future studies and organizations to use more inclusive and accurate language in their future analyses.

Risk Factors and Epidemiology

While the incidence and mortality rates for liver and intrahepatic bile duct cancers were previously increasing, an analysis with data from 1975 to 2022 demonstrated that these appear to have stabilized in recent years in men but have gone up in women by approximately 2% annually.[1] Incidence

Version 2.2025 © 2025 National Comprehensive Cancer Network© (NCCN©), All rights reserved. NCCN Guidelines® and this illustration may not be reproduced in any form without the express written permission of NCCN.

PLEASE NOTE that use of this NCCN Content is governed by the End-User License Agreement, and you MAY NOT distribute this Content or use it with any artificial intelligence model or tool.
Printed by Galya Basol Kochav on 1/5/2026 10:54:24 AM. Copyright © 2026 National Comprehensive Cancer Network, Inc. All Rights Reserved.

(2017–2021) and mortality (2018–2022) were highest in individuals of American Indian/Alaska Native descent. One study reported that alcohol-related liver disease and metabolic dysfunction-associated steatotic liver disease (MASLD) were major contributors to the rise in cases of primary liver disease in the United States from 2000 to 2021.[4] Forecast analyses predict that HCC rates will be highest in Black individuals and Hispanic individuals over the next 15 years.[5] These analyses also predict increasing incidence rates in those born between 1950 and 1959, due to high rates of hepatitis C viral infection in this age group.

The major risk factors for the development of HCC are cirrhosis and chronic liver disease, regardless of etiology.[6,7] Specific risk factors for patients with Child-Turcotte-Pugh (CTP) Class A or B cirrhosis, regardless of etiology, include hepatitis B or C, alcohol-associated cirrhosis, metabolic dysfunction-associated steatohepatitis (MASH), and other etiologies.[8] Other patients at risk for HCC include those with CTP Class C cirrhosis who are transplant candidates and those without cirrhosis with hepatitis B. Additional risk factors for patients without cirrhosis with hepatitis B include platelet count, age, and gender-hepatitis B virus (HBV) score ≥10; family history of HCC; being a man from an endemic country who is >40 years; being a woman from endemic country who is >50 years; and being a person from Africa who is at an earlier age. A retrospective analysis of patients at liver transplantation centers in the United States found that nearly 50% and about 15% of patients were infected with HBV or HCV, respectively, with approximately 5% of patients having markers of both hepatitis B and hepatitis C infection.[9] Seropositivity for hepatitis B e antigen (HBeAg) and hepatitis B surface antigen (HBsAg) is associated with an increased risk for HCC in patients with chronic hepatitis B viral infection.[10,11] Data from large population-based studies have also identified high serum HBV DNA and HCV RNA viral load as independent risk factors for developing HCC in patients with chronic infection.[12-15]

The incidence of HCC is increasing in the United States, particularly in the population infected with HCV. The annual incidence rate of HCC among patients with HCV with CTP A/B cirrhosis has been estimated to be ≥1%.[8] However, HCV often goes undetected, making these calculations difficult to interpret. Although it has been reported that the number of cases of hepatitis C infection diagnosed per year in the United States is declining, it is likely that the observed increase in the number of cases of HCV-related HCC is associated with the often prolonged period between viral infection and the manifestation of HCC.[16,17] There is strong evidence that direct-acting antivirals (DAAs) improve sustained virologic response in patients with HCV,[18,19] which in turn may eventually decrease incidence of HCC.[20,21]

Globally, HBV is the leading cause of HCC incidence and mortality.[22] Approximately 1.5 million people in the United States are chronically infected with HBV.[23,24] Results from a prospective controlled study showed the annual incidence of HCC to be 0.5% in carriers of the virus without liver cirrhosis and 2.5% in those with known cirrhosis,[25] although studies have shown wide variation in the risk of HCC among individuals with chronic hepatitis B infection.[26] A meta-analysis including 68 studies with 27,854 patients with untreated HBV showed an annual HCC incidence of 0.88 per 100 person-years (95% CI, 0.76–0.99), with higher incidence per 100 person-years for patients with cirrhosis (3.16; 95% CI, 2.58–3.74).[26] An analysis of 634 patients with HBV showed that long-term antiviral therapy was associated with reduced risk of HCC in patients without cirrhosis (standardized incidence ratio, 0.40; 95% CI, 0.20–0.80).[27] Analyses from universal HBV vaccination programs in Alaska and Taiwan showed that vaccination is associated with decreased HCC incidence in children and young adults.[28-30] Since universal HBV vaccination programs were implemented relatively recently, the potential efficacy of these programs in adults will likely not be seen for at least 10 to 20 years. Hepatitis D is linked to hepatitis B and patients with hepatitis D virus infection have a greater risk of developing HCC compared to those with HBV infection only.[31]

Version 2.2025 © 2025 National Comprehensive Cancer Network© (NCCN©), All rights reserved. NCCN Guidelines® and this illustration may not be reproduced in any form without the express written permission of NCCN.

PLEASE NOTE that use of this NCCN Content is governed by the End-User License Agreement, and you MAY NOT distribute this Content or use it with any artificial intelligence model or tool.
Printed by Galya Basol Kochav on 1/5/2026 10:54:24 AM. Copyright © 2026 National Comprehensive Cancer Network, Inc. All Rights Reserved.

Non-viral causes associated with an increased risk for HCC include cirrhosis from any cause (eg, alcohol-associated cirrhosis); inherited errors of metabolism (relatively rare), such as hereditary hemochromatosis, porphyria cutanea tarda, and alpha-1 antitrypsin deficiency; Wilson's disease; and stage IV primary biliary cirrhosis.[32-34]

Alcoholic cirrhosis is a well-known risk factor for HCC,[8] although many of the studies evaluating the incidence rate of HCC in individuals with alcohol-induced cirrhosis have been confounded by the presence of other risk factors such as viral hepatitis infection, which can interact synergistically in the pathogenesis of HCC.[35,36] It has been estimated that 60% to 80% of persons with HCC have underlying cirrhosis, possibly approaching 90% in the United States.[37] Importantly, certain populations infected with HBV may have an increased risk for HCC even in the absence of cirrhosis, and the annual incidence of HCC in individuals with inactive HBV and without cirrhosis is <0.3%.[34] Some risk factors for the development of HCC in HBV carriers without evidence of liver cirrhosis include active viral replication, high HBV DNA levels, and a family history of HCC.[34,38] The presence of liver cirrhosis is usually considered to be a prerequisite for development of HCC in individuals with inherited metabolic diseases of the liver or liver disease with an autoimmune etiology.[39-41] Although the mechanism of HCC development differs according to the underlying disease, HCC typically occurs in the setting of a histologically abnormal liver. Hence, the presence of chronic liver disease represents a risk for development of HCC.[32] However, HCC may also develop in patients with normal livers and no known risk factors.[42,43]

Metabolic disorders (ie, obesity, diabetes, impaired glucose metabolism, metabolic syndrome, MASLD) are associated with increased risk of HCC.[44-49] Using a predictive model, Le et al reported an anticipated increase from 33.7% in 2020 to 41.4% by 2050 in the prevalence of MASLD.[50] Similarly, the anticipated increase in MASH would be from 5.8% to 7.9% by 2050. It is anticipated that sequelae of MASLD, such as MASH (a spectrum of conditions characterized by histologic findings of hepatic steatosis with inflammation in individuals who consume little or no alcohol) will replace hepatitis as the most common underlying cause of HCC.[51-53] Estimations of the prevalence of MASH in the United States are in the range of 3% to 5%, indicating that this sizable subpopulation is at risk for cirrhosis and development of HCC.[54] In one study, 12.8% of 195 patients with cirrhosis secondary to MASH developed HCC at a median follow-up of 3.2 years, with an annual incidence rate of HCC of 2.6%.[55] Available epidemiologic evidence supports an association between MASLD or MASH and an increased HCC risk predominantly in individuals with cirrhosis.[46,56] However, several studies suggest that HCC may be somewhat less likely to develop in the setting of MASH-associated cirrhosis compared with cirrhosis due to hepatitis C infection.[57,58] The American Gastroenterological Association clinical practice update recommends that screening for HCC in patients with cirrhosis due to MASLD be considered.[59] HCC screening should also be considered in patients with MASLD with noninvasive markers that provide evidence of advanced liver fibrosis or cirrhosis.

Fibrolamellar HCC (FLHCC) is a variant of HCC that makes up a very small fraction of all HCCs. Patients with FLHCC tend to be younger and have a generally better prognosis than those with HCC,[60-62] though recurrences following resection are common.[61] FLHCC also is rarely, if ever, associated with hepatitis, cirrhosis, or elevated alpha-fetoprotein (AFP) levels.[61,63] Though cross-sectional imaging results may be strongly suggestive of FLHCC, histologic confirmation is needed as FLHCC can be mistaken for focal nodular hyperplasia on imaging.[64,65] However, unlike HCC, FLHCC tends to spread to and recur in lymph nodes.[66] A molecular target to identify FLHCC, the DNAJB1-PRKACA chimera, has been found,[67] which accurately identifies FLHCC in 79% to 100% of patients.[67-70] Complete resection is the only potentially curative option.[64] An unplanned analysis from a phase II study investigating the efficacy of everolimus, combined

Version 2.2025 © 2025 National Comprehensive Cancer Network© (NCCN©), All rights reserved. NCCN Guidelines® and this illustration may not be reproduced in any form without the express written permission of NCCN.

leuprolide and letrozole, or the combination of all three drugs revealed that the primary endpoint of a 6-month progression-free survival (PFS) was not met.[71] Given its rarity, the Panel does not provide treatment recommendations for FLHCC in these guidelines.

Screening for HCC

The purpose of a cancer screening test is to identify the presence of a specific cancer in an asymptomatic individual in a situation where early detection has the potential to favorably impact patient outcome. The Panel supports the recommendation by the AASLD that HCC screening in patients with risk factors for HCC should consist of a program including standardized screening tests, recall procedures, and quality control procedures in place.[72] The AASLD and European Association for the Study of the Liver (EASL)-European Organisation for Research and Treatment of Cancer (EORTC) recommend that ultrasound (US) and AFP screening in patients who are at risk be done every 6 months.[8,73]

Support for enrolling individuals at high risk for HCC in a screening program comes from a large randomized controlled trial (RCT) in China of 18,816 males and females with hepatitis B infection or a history of chronic hepatitis, defined as patients with abnormalities on serum liver tests lasting for ≥6 months. In this study, screening with serum AFP testing and liver US every 6 months was shown to result in a 37% reduction in HCC mortality, despite the fact that <60% of individuals in the screening arm completed the screening program.[74]

HCC screening should be carried out in at-risk populations regardless of age. In a prospective observational study of 638 patients with HCC in Singapore carried out over a 9-year period, patients ≤40 years were more likely than patients who are older to harbor hepatitis B infection and to have more advanced disease at diagnosis.[75] Although survival did not differ in the two groups overall, a significant survival benefit was observed for younger patients when the subgroup of patients with early-stage disease was considered.

AFP and liver US are the most widely used methods of screening for HCC.[76] A review of serum protein biomarkers for early detection of HCC showed that an AFP cut-off value of 100 ng/mL was associated with high specificity (99%) but low sensitivity (31%).[77] In a screening study involving a large population of patients in China infected with HBV or those with chronic hepatitis, and using an AFP cut-off of >20 ng/mL, the detection rate, false-positive rate, and positive predictive value with AFP alone were 69%, 5.0%, and 3.3%; with US alone were 84%, 2.9%, and 6.6%; and with the combination of AFP and US were 92%, 7.5%, and 3.0%.[78] These results demonstrate that US combined with AFP is a better modality for HCC screening than AFP testing alone. A study of 333 patients with HCC and HBV/HCV determined that patients with HCC diagnosed after surveillance with US and AFP had significantly longer overall survival (OS) and disease-free survival (DFS), compared to patients who had no surveillance prior to diagnosis.[79] Nevertheless, since US is highly operator dependent, the addition of AFP may increase the likelihood of detecting HCC in a screening setting. However, AFP is frequently normal in patients with early-stage disease and its utility as a screening biomarker is limited.[80-82] A meta-analysis including 32 studies with 13,367 patients with cirrhosis who were screened for HCC showed that US with AFP improves sensitivity for detection of HCC, compared to US alone (97% vs. 78%, respectively; relative risk [RR], 0.88; 95% CI, 0.83–0.93).[83] Due to the low cost and ease of use, AFP may have utility for enhancing detection of HCC when used in combination with US for screening individuals at risk for HCC. A progressive elevation rate of ≥7 ng/mL per month may be more useful as a diagnostic tool for HCC, relative to use of a fixed cut point such as 200 ng/mL.[84]

Version 2.2025 © 2025 National Comprehensive Cancer Network© (NCCN©), All rights reserved. NCCN Guidelines® and this illustration may not be reproduced in any form without the express written permission of NCCN.

PLEASE NOTE that use of this NCCN Content is governed by the End-User License Agreement, and you MAY NOT distribute this Content or use it with any artificial intelligence model or tool.
Printed by Galya Basol Kochav on 1/5/2026 10:54:24 AM. Copyright © 2026 National Comprehensive Cancer Network, Inc. All Rights Reserved.

In these guidelines, the populations considered to be "at risk" for HCC and likely to benefit from participation in an HCC screening program include patients with CTP Class A or B liver cirrhosis induced by viral (hepatitis B and C) as well as non-viral causes of cirrhosis (ie, alcohol-associated cirrhosis, MASH, other etiologies), patients with CTP Class C cirrhosis who are transplant candidates, and hepatitis B carriers without cirrhosis.[8] Other less common causes of cirrhosis include Wilson's disease, primary sclerosing cholangitis, drug-induced liver disease, chronic right-sided heart failure, autoimmune hepatitis, primary biliary cholangitis, hemochromatosis, alpha-1 antitrypsin deficiency, and Budd-Chiari syndrome.[85]

The Panel recommends screening with US and AFP testing (every 6 months) for patients with established risk factors for HCC. Additional imaging (abdominal multiphasic CT [preferred] or MRI [preferred] or contrast-enhanced US) is recommended in the setting of a rising serum AFP or following identification of a liver mass nodule ≥10 mm on US, based on AASLD and Liver Imaging Reporting and Data System (LI-RADS) guidelines.[8,86] Imaging is useful if the liver cannot be adequately visualized with US. It is also reasonable to screen patients with cross-sectional imaging (CT or MRI), and this may be commonly used, though not well-studied in the United States. Cost and availability limit the widespread use of screening using cross-sectional imaging. Liver masses <10 mm are difficult to definitively characterize through imaging. If nodules of this size are found, then US and AFP testing should be repeated in 3 to 6 months. Patients with viral hepatitis who have had a complete or sustained viral response should continue with screening despite that response.[87]

Diagnosis

Localized HCC is asymptomatic for much of its natural history. Nonspecific symptoms associated with more advanced HCC can include jaundice, anorexia, weight loss, malaise, and upper abdominal pain. Physical signs of HCC can include hepatomegaly and ascites.[52] Paraneoplastic syndromes, although rare, also can occur and include hypercholesterolemia, erythrocytosis, hypercalcemia, and hypoglycemia.[88]

Combined HCC-cholangiocarcinoma (cHCC-CCA) is a rare hepatobiliary tumor type. Resection for those with early-stage disease is the only potentially curative option.[89-91] Diagnosis of cHCC-CCA through imaging is difficult since imaging characteristics consist of varying features of both HCC and CCA.[89,90,92] Therefore, misdiagnosis may occur.[90,93] Further, though AFP levels may be elevated in patients with cHCC-CCA, levels tend to not differ significantly from that of patients with HCC.[94] cHCC-CCA may also be characterized by elevated serum CA 19-9, similar to intrahepatic CCA.[92,95] If cHCC-CCA is suspected, thorough pathology review is recommended. Biopsy and sequencing can help in disease management if there are actionable mutations. It should be noted that needle biopsies will not necessarily show both elements of the malignancy. Multidisciplinary management is required.

Imaging

HCC lesions are radiologically characterized by arterial hypervascularity and "wash out" on portal venous phases, since they derive most of their blood supply from the hepatic artery. This is unlike the surrounding liver, which receives its blood supply from both the portal vein and hepatic artery.[96] Diagnostic HCC imaging involves the use of multiphasic liver protocol CT with multiphasic (eg, precontrast, arterial phase, portal venous phase, delayed) intravenous contrast-enhanced MRI.[8,72] The classic imaging profile associated with an HCC lesion is characterized by intense arterial uptake or enhancement followed by contrast washout or hypointensity in the delayed nonperipheral venous phase.[8,86,97-101] LI-RADS also considers enhancing capsule appearance and threshold growth compared to previous imaging as part of diagnosis using CT or MRI imaging.[86] The LI-RADS criteria are applicable only to those with cirrhosis

Version 2.2025 © 2025 National Comprehensive Cancer Network© (NCCN©), All rights reserved. NCCN Guidelines® and this illustration may not be reproduced in any form without the express written permission of NCCN.

and a biopsy may be necessary in patients without any history of liver disease.

Though contrast-enhanced US (CEUS) may be used at centers of expertise as a problem-solving tool for characterization of indeterminate nodules; it is not recommended by the Panel for whole-liver assessment, surveillance, or staging.[102] A meta-analysis including 241 studies showed that CT and MRI are more sensitive than US without contrast for detection of HCC.[103] Another meta-analysis that included only studies of patients with cirrhosis or chronic hepatitis (N = 30) also showed that US is less sensitive than CT and MRI (60%, 68%, and 81%, respectively) for diagnosis of HCC, though it is the most specific (97%, 93%, and 85%, respectively).[104] A meta-analysis including 22 studies with 1721 patients with HCC showed that PET/CT may be useful for predicting prognosis (ie, OS and DFS; $P < .001$),[105] but it is associated with low sensitivity for HCC detection.[106,107]

Multiple meta-analyses have shown that MRI is more sensitive for HCC diagnosis than CT.[103,108,109] However, one meta-analysis including 19 comprehensive comparisons did not find a statistically significant difference in specificity or in the positive likelihood ratio.[109] When comparing imaging modalities, it is important to keep in mind the quality of the images being compared, which likely differ between studies.

Contrast-enhanced MRI for detection of lesions ≤2 cm has acceptable sensitivity (78%) and excellent specificity (92%) when criteria are applied in appropriate clinical context in patients with known liver disease.[110] The results of a prospective study evaluating the accuracy of CEUS and dynamic contrast-enhanced MRI for the diagnosis of liver nodules ≤2 cm observed on screening US demonstrated that the diagnosis of HCC can be established without biopsy confirmation if both imaging studies are conclusive.[99] Comparing MRI to CEUS, the sensitivity was 61.7% versus 51.7%, the specificity was 96.6% versus 93.1%, the positive predictive value was 97.4% versus 93.9%, and the negative predictive value was 54.9% versus 50.9%.[99] However, as noted earlier, CEUS is not commonly utilized in the United States. Other investigators have suggested that a finding of classical arterial enhancement using a single imaging technique is sufficient to diagnose HCC in patients with cirrhosis and liver nodules between 1 and 2 cm detected during surveillance, thereby reducing the need for a biopsy.[111] In the updated AASLD guidelines, the algorithms for liver nodules between 1 and 2 cm have been changed to reflect these considerations. LI-RADS also offers some guidance regarding the use of CEUS for the diagnosis of HCC.[112]

The NCCN Guidelines' recommendations for diagnostic imaging in the setting of high clinical suspicion for HCC (eg, following identification of a liver nodule on US or in the setting of a rising serum AFP level) apply only to patients with known risk factors for HCC and are adapted from the AASLD guidelines.[8] For these patients, as well as patients with an incidental liver mass or nodule found on US or on another imaging exam, the guidelines recommend evaluation using multiphasic abdominal contrast-enhanced CT or MRI to determine the enhancement characteristics, extent and number of lesions, vascular anatomy, and extrahepatic disease. Gadolinium contrast is preferred for MRI as hepatobiliary agents such as gadolinium ethoxybenzyl diethylenetriamine pentaacetic acid that require more subspecialized experience to interpret hepatobiliary phase imaging are not currently included in AASLD or LI-RADS interpretation.[113-116] The quality of MRI is dependent on patient adherence, since some patients may be unable to hold their breath. If no mass is detected using multiphasic contrast-enhanced imaging, or if the observed lesion is definitely benign, then the patients should return to a screening program (ie, US and AFP in 6 months). If there is suspicion that the diagnostic imaging test yielded a false negative result, then a different imaging method with or without AFP may be considered. If the observation is inconclusive (ie, not definitely HCC but not definitely benign), then multidisciplinary discussion and individualized workup may be pursued,

Version 2.2025 © 2025 National Comprehensive Cancer Network© (NCCN©), All rights reserved. NCCN Guidelines® and this illustration may not be reproduced in any form without the express written permission of NCCN.

PLEASE NOTE that use of this NCCN Content is governed by the End-User License Agreement, and you MAY NOT distribute this Content or use it with any artificial intelligence model or tool.
Printed by Galya Basol Kochav on 1/5/2026 10:54:24 AM. Copyright © 2026 National Comprehensive Cancer Network, Inc. All Rights Reserved.

including additional imaging or biopsy. Multidisciplinary team management has been associated with improved outcomes in HCC, including higher rates of treatment, higher rates of curative treatments in early stages, and prolonged survival in advanced disease.[117-120]

Serum Biomarkers

Although serum AFP has long been used as a marker for HCC, it is not a sensitive or specific diagnostic test for HCC. Serum AFP levels >400 ng/mL are observed only in a small percentage of patients with HCC. In a series of 1158 patients with HCC, only 18% of patients had values >400 ng/mL and 46% of patients had normal serum AFP levels <20 ng/mL.[121] In patients with chronic liver disease, an elevated AFP could be more indicative of HCC in patients who are not infected.[122] Furthermore, AFP can also be elevated in pregnancy, in other cancers such as lymphoma and germ cell tumors, and rarely in intrahepatic CCA and some metastases from colon cancer.[123] AFP testing can be useful in conjunction with other test results to guide the management of disease in patients for whom a diagnosis of HCC is suspected. An elevated AFP level in conjunction with imaging results showing the presence of a growing liver mass has been shown to have a high positive predictive value for HCC in two retrospective analyses involving small numbers of patients.[124,125] However, the diagnostic accuracy of an absolute AFP cutoff value has not been validated in this setting, and such values may vary by institution and patient population.

Since the level of serum AFP may be elevated in those with certain nonmalignant conditions such as chronic HBV[126] or HCV or be within normal limits in ≤30% of patients with HCC,[127] the Panel considers an imaging finding of classic enhancement to be more definitive in the diagnostic setting compared to AFP alone. Additional imaging studies (CT or MRI) are recommended for patients with a rising serum AFP level in the absence of a liver mass. If no liver mass is detected following measurement of an elevated AFP level, the patient should be followed with AFP testing and liver imaging. Further, assessment of AFP levels may be helpful in monitoring treatment response as appropriate (see *Surveillance* below).

Other serum biomarkers being studied in this setting include des-gamma-carboxy prothrombin (DCP), also known as protein induced by vitamin K absence or antagonist-II (PIVKA-II), and lens culinaris agglutinin-reactive AFP (AFP-L3), an isoform of AFP.[37,128,129] Although AFP was found to be more sensitive than DCP or AFP-L3 in detecting early-stage and very-early-stage HCC in a retrospective case-control study, none of these biomarkers was considered optimal in this setting.[130] A case-control study involving patients with hepatitis C enrolled in the large, randomized HALT-C trial who developed HCC showed that a combination of AFP and DCP is superior to either biomarker alone as a complementary assay to screening.[81]

The GALAD model, which accounts for gender, age, AFP-L3, AFP, and des-carboxy-prothrombin, is a serum biomarker model used to assess the risk of HCC in patients with chronic liver disease.[131] In validation studies, the GALAD model identified HCC in patients with chronic liver disease or MASH with a high degree of accuracy.[132-134] The GALADUS score, which combines the GALAD score and US, was found to improve the performance of the GALAD score.[133] A novel multitarget blood test may be a promising technology for HCC screening.[135-137] However, there is no demonstrated benefit over other tests.

Core Needle Biopsy

A diagnosis of HCC can often be made noninvasively by imaging in patients with established risk factors for HCC with diagnostic imaging findings on multiphase imaging as described above. However, there are a few clinical scenarios in which an initial core needle biopsy of a suspected HCC may be considered. First, a core needle biopsy may be considered

Version 2.2025 © 2025 National Comprehensive Cancer Network© (NCCN©), All rights reserved. NCCN Guidelines® and this illustration may not be reproduced in any form without the express written permission of NCCN.

PLEASE NOTE that use of this NCCN Content is governed by the End-User License Agreement, and you MAY NOT distribute this Content or use it with any artificial intelligence model or tool.
Printed by Galya Basol Kochav on 1/5/2026 10:54:24 AM. Copyright © 2026 National Comprehensive Cancer Network, Inc. All Rights Reserved.

when a lesion is suspicious for malignancy, but multiphasic CT or MRI results do not meet imaging features for HCC.[8,73,80,100,138] AASLD describes the limitations of biopsy in this scenario, specifically the cost, emotional distress for the patient, risk of complications, and potential sampling error for small lesions.[72] Second, a core needle biopsy may be done in patients who are not considered high risk for developing HCC (ie, patients who do not have cirrhosis, chronic HBV, or a previous history of HCC). Third, a core needle biopsy may be indicated in patients with conditions associated with formation of nonmalignant nodules that may be confused with HCC during imaging. These conditions include cardiac cirrhosis, congenital hepatic fibrosis, or cirrhosis due to a vascular disorder such as Budd-Chiari syndrome, hereditary hemorrhagic telangiectasia, or nodular regenerative hyperplasia.[139] Finally, a core needle biopsy may be considered in patients with elevated CA 19-9 or carcinoembryonic antigen, in order to rule out intrahepatic CCA or mixed HCC-CCA[140,141] or for confirmation of metastatic disease, as this could change clinical decision-making including enrollment in clinical trials.

In patients with extrahepatic/metastatic disease deemed ineligible for resection, transplant, or locoregional therapy, biopsy should be considered and is preferred. Noninvasive imaging criteria have been studied predominantly in earlier stages of disease. A multicenter national audit of 418 patients in the United Kingdom being evaluated for systemic therapy for HCC demonstrated that approximately 7% of patients with a radiographic diagnosis of HCC had an alternative diagnosis such as CCA or mixed HCC-CCA on histologic confirmation.[142] If core needle biopsy is considered, it should be obtained prior to ablation when possible. If transplant or resection is a consideration, patients should be referred to a transplant center and/or hepatic surgeon before biopsy since biopsy may not be necessary in certain patients with resectable malignant-appearing masses. A repeat core needle biopsy may be considered for non-diagnostic purposes and if a prior core needle biopsy was discordant with imaging, biomarkers, or other factors.

Both core needle biopsy and fine-needle aspiration biopsy (FNAB) have advantages and disadvantages. FNAB may be associated with a lower complication rate when sampling deeply situated lesions or those located near major blood vessels. In addition, the ability to rapidly stain and examine cytologic samples can provide for immediate determinations of whether a sufficient sample has been obtained, as well as the possibility of an upfront tentative diagnosis.[143] However, FNAB is highly dependent on the skill of the cytopathologist,[144] and there are reports of high false-negative rates[99,145] as well as the less common possibility of false-positive findings with this procedure.[146] Although a core needle biopsy is a more invasive procedure, it has the advantage of providing pathologic information on both cytology and tissue architecture. Furthermore, additional histologic and immunohistochemical tests can be performed on the paraffin wax-embedded sample.[80,143,145] However, some evidence indicates that a core needle biopsy does not provide an accurate determination of tumor grade.[147] Core needle biopsy is also better for next-generation sequencing (NGS), as NGS needs sufficient tissue and FNAB can have a limited number of tumor cells.

Nevertheless, the use of biopsy to diagnose HCC is limited by sampling error, particularly when lesions are <1 cm.[37] Patients with a nondiagnostic biopsy result should be followed closely, and subsequent additional imaging and/or biopsy is recommended if a change in nodule size is observed. The guidelines emphasize that a growing mass with a negative biopsy does not rule out HCC. Continual monitoring with a multidisciplinary review including surgeons is recommended since definitive resection may be considered.

Version 2.2025 © 2025 National Comprehensive Cancer Network© (NCCN©), All rights reserved. NCCN Guidelines® and this illustration may not be reproduced in any form without the express written permission of NCCN.

PLEASE NOTE that use of this NCCN Content is governed by the End-User License Agreement, and you MAY NOT distribute this Content or use it with any artificial intelligence model or tool.
Printed by Galya Basol Kochav on 1/5/2026 10:54:24 AM. Copyright © 2026 National Comprehensive Cancer Network, Inc. All Rights Reserved.

Management of Mixed HCC-CCA

An estimated 1% to 10% of patients with primary liver tumors are found to have a combination of both HCC and CCA histologies on pathologic review.[142,148-150] Tumor molecular profiling should be considered in all patients with advanced stages of disease to identify potential targeted aberrations, which are associated with CCA.[151] Liver resection is considered the standard treatment for resectable disease. Due to the relative rarity of this disease, prospective data are lacking; however, liver-directed local therapies may be appropriate for patients with a limited extent of unresectable hepatic disease, similar to management algorithms for HCC (see HCC-6 in the algorithm) and intrahepatic CCA (see the NCCN Guidelines for Biliary Tract Cancers, available at www.NCCN.org). Patients with HCC-CCA that is limited in size based on center-specific criteria used should be considered for evaluation in a transplant center. In patients with metastatic or locally advanced recurrence after a prior resection or local therapies, a repeat biopsy should be considered to ascertain the dominant histology at recurrence. If biopsy results at recurrence suggest an isolated recurrence of either the HCC or CCA component, the Panel considers a systemic therapy option appropriate for that histologic component. There are limited prospective data to guide treatment decisions for advanced disease and certain treatment paradigms for either HCC or CCA, described in this section, can be applied.

A retrospective study of patients with mixed HCC-CCA treated with palliative systemic therapy demonstrated similar overall response rates (ORRs) with chemotherapy versus non-chemotherapy-based systemic therapies.[152] There was a trend towards longer median OS in patients treated with chemotherapy (15.5 vs. 5.3 months; $P = .052$). Based upon this study and the potential for activity of component parts in both histologies, gemcitabine plus cisplatin combined with either durvalumab or pembrolizumab is an appropriate choice for first-line therapy. The Panel notes that these combinations include agents with anti-tumor activity in both CCA[153-155] and HCC histologies.[156-159] Upon disease progression, molecularly targeted therapies should be considered if the tumor harbors a targetable aberration (see the NCCN Guidelines for Biliary Tract Cancers, available at www.NCCN.org). In the absence of a targetable aberration, regimens with demonstrated activity in both HCC and CCA are reasonable options, including nivolumab plus ipilimumab[160,161] or regorafenib.[162,163]

Initial Workup

The foundation of initial workup for patients with suspected HCC is a multidisciplinary evaluation including careful review of medical history to identify any potential chronic liver diseases, investigations of the etiologic origin of liver disease, a hepatitis panel for detection of hepatitis B and/or C viral infection (ie, HBsAg, hepatitis B surface antibody, hepatitis B core antibody [HBcAb], HBcAb immunoglobulin M [IgM] [recommended only in patients with acute viral hepatitis], and HCV antibodies), an assessment of the presence of comorbidity, imaging studies to detect the presence of metastatic disease, and an evaluation of hepatic function, including a determination of whether portal hypertension is present. The guidelines recommend confirmation of viral load in patients who test positive for HBsAg, HBcAb IgG (since an isolated HBcAb IgG may still indicate chronic HBV infection), and HCV antibodies. If viral load is positive, patients should be evaluated by a hepatologist for consideration of antiviral therapy.[38,164]

Common sites of HCC metastasis include the lung, adrenal glands, peritoneum, and bone.[165,166] Hence, routine chest CT is recommended since lung metastases are typically asymptomatic. Bone scan and/or additional bone imaging may be considered as clinically indicated if suspicious bone pain is present or cross-sectional imaging raises the possibility of bone metastases.[167] Multiphasic contrast-enhanced CT or MRI of the abdomen, CT of the chest, and CT/MRI of the pelvis are also used in the evaluation of the HCC tumor burden to detect the presence of metastatic disease, nodal disease, and vascular invasion; to assess

Version 2.2025 © 2025 National Comprehensive Cancer Network© (NCCN©), All rights reserved. NCCN Guidelines® and this illustration may not be reproduced in any form without the express written permission of NCCN.

PLEASE NOTE that use of this NCCN Content is governed by the End-User License Agreement, and you MAY NOT distribute this Content or use it with any artificial intelligence model or tool.
Printed by Galya Basol Kochav on 1/5/2026 10:54:24 AM. Copyright © 2026 National Comprehensive Cancer Network, Inc. All Rights Reserved.

whether evidence of portal hypertension is present; to provide an estimate of the size and location of HCC and the extent of chronic liver disease; and, in the case of patients being considered for resection, to provide an estimate of the future liver remnant (FLR).[98] Enlarged lymph nodes are commonly seen in patients with viral hepatitis, primary biliary cirrhosis, and other underlying liver disorders that predispose patients to HCC.[168] Detection of nodal disease by cross-sectional imaging is non-specific and can be challenging in patients with hepatitis or chronic liver diseases.

Assessment of Liver Function

An initial assessment of hepatic function involves liver function testing including measurement of serum levels of bilirubin, aspartate aminotransferase (AST), alanine transaminase (ALT), alkaline phosphatase (ALP), measurement of prothrombin time (PT) expressed as international normalized ratio (INR), albumin, and platelet count (surrogate for portal hypertension). Other recommended tests include complete blood count (CBC), blood urea nitrogen (BUN), and creatinine to assess kidney function; creatinine is also an established prognostic marker in patients with liver disease.[169] Further assessment of hepatic functional reserve prior to hepatic resection in patients with cirrhosis may be performed with different tools such as US and MRI elastography (which may provide and quantify the degree of cirrhosis-related fibrosis), non-focal liver biopsy, and transjugular liver biopsy with pressure measurements. There are emerging data for the use of functional MRI assessment.[170-174]

The Child-Turcotte Pugh (CTP) classification has been traditionally used for the assessment of hepatic functional reserve in patients with cirrhosis.[175,176] The CTP score incorporates laboratory measurements (ie, serum albumin, bilirubin, PT) as well as more subjective clinical assessments of encephalopathy and ascites. It provides a general estimate of the liver function by classifying patients as having compensated (class A) or decompensated (classes B and C) cirrhosis. Advantages of the CTP score include ease of performance (ie, can be done at the bedside) and the inclusion of clinical parameters.

An important additional assessment of liver function not included in the CTP score is an evaluation of signs of clinically significant portal hypertension (ie, esophagogastric varices, splenomegaly, splenorenal shunts and recanalization of the umbilical vein, thrombocytopenia). Evidence of portal hypertension may be evident on CT/MRI.[98 175-178] Esophageal varices may be evaluated using esophagogastroduodenoscopy or contrast-enhanced cross-sectional imaging.

Model for End-Stage Liver Disease (MELD) is another system for the evaluation of hepatic reserve. MELD is a numerical scale ranging from 6 (less ill) to 40 (gravely ill) for individuals ≥12 years. It is derived using three laboratory values (serum bilirubin, creatinine, and INR) and was originally devised to provide an assessment of mortality for patients undergoing transjugular intrahepatic portosystemic shunts.[179,180] The MELD score has since been adopted by the United Network for Organ Sharing (UNOS; www.unos.org) to stratify patients on the liver transplantation waiting list according to their risk of death within 3 months.[181] The MELD score has sometimes been used in place of the CTP score to assess prognosis in patients with cirrhosis. Advantages of the MELD score include the inclusion of a measurement of renal function and an objective scoring system based on widely available laboratory tests, although clinical assessments of ascites and encephalopathy are not included. It is currently unclear whether the MELD score is superior to the CTP score as a predictor of survival in patients with liver cirrhosis. The MELD score has not been validated as a predictor of survival in patients with cirrhosis who are not on a liver transplantation waiting list.[182] While the MELD model is used to stratify organ access for transplantation, it also favors patients with renal dysfunction. Serum creatinine, an important component of the MELD score,

Version 2.2025 © 2025 National Comprehensive Cancer Network© (NCCN©), All rights reserved. NCCN Guidelines® and this illustration may not be reproduced in any form without the express written permission of NCCN.

PLEASE NOTE that use of this NCCN Content is governed by the End-User License Agreement, and you MAY NOT distribute this Content or use it with any artificial intelligence model or tool.
Printed by Galya Basol Kochav on 1/5/2026 10:54:24 AM. Copyright © 2026 National Comprehensive Cancer Network, Inc. All Rights Reserved.

can be an unreliable marker of renal dysfunction, especially in patients with cirrhosis.[183]

Albumin and bilirubin are objectively measured, while ascites and encephalopathy, other scoring parameters used to calculate the CTP score, are subjective. Therefore, another alternative to the CTP score is the Albumin-Bilirubin (ALBI) grade,[184] a model proposed by Johnson et al that takes into account only serum bilirubin and albumin levels.[185] It has been shown to be especially helpful in predicting the survival outcome of patients with stable decompensated cirrhosis.[186] An analysis of almost 6000 patients from Europe, the United States, Japan, and China showed that the ALBI grade, which stratifies patients into three risk categories, performs as well as the CTP score.[185] Further, patients scored as CTP grade A were categorized into either ALBI grade 1 or 2.

The indocyanine green (ICG) clearance test is extensively used in Asia for the assessment of liver function prior to hepatic resection in patients with cirrhosis.[187,188] The Japanese evidence-based clinical guidelines for HCC recommend the ICG retention rate at 15 minutes (ICGR-15) after intravenous injection for the assessment of liver function prior to surgery.[189] However, this test is not widely used in Western countries.

Pathology and Staging

Pathology

Three gross morphologic types of HCC have been identified: nodular, massive, and diffuse. Nodular HCC is often associated with cirrhosis and is characterized by well-circumscribed nodules. The massive type of HCC, usually associated with a non-cirrhotic liver, occupies a large area with or without satellite nodules in the surrounding liver. The less common diffuse type is characterized by diffuse hepatic involvement with many small indistinct tumor nodules throughout the liver. See the *Principles of Pathology* in the algorithm.

Staging

Clinical staging systems for patients with cancer can provide a more accurate prognostic assessment before and after a particular treatment intervention, and they may be used to guide treatment decision-making including enrollment in clinical trials. Therefore, staging can have a critical impact on treatment outcome by facilitating appropriate patient selection for specific therapeutic interventions, and by providing risk stratification information following treatment. The key factors affecting prognosis in patients with HCC are the clinical stage, growth rate of the tumor, the general health of the patient, the liver function of the patient, and the treatments administered.[190] Many staging systems for patients with HCC have been devised.[191,192] Each of the staging systems includes variables that evaluate one or more of the factors listed above. For example, the CTP[193] and MELD scores[179] can be considered to be staging systems that evaluate aspects of liver function.

The AJCC staging system provides information on the pathologic characteristics of resected specimens only,[194] whereas the Okuda system incorporates aspects of liver function and tumor characteristics.[195] The French classification (GRETCH) system incorporates the Karnofsky performance score as well as measurements of liver function and serum AFP.[196] Several staging systems include all parameters from other staging systems as well as additional parameters. For example, the Chinese University Prognostic Index (CUPI) system[197] and the Japanese Integrated Staging (JIS)[198] scores incorporate the tumor, node, metastasis (TNM) staging system, and the Cancer of the Liver Italian Program (CLIP),[199] Barcelona Clinic Liver Cancer (BCLC),[200] SLiDe (stage, liver damage, DCP),[201] and JIS systems include the CTP score (with modified versions of CLIP and JIS substituting the MELD score for the CTP score).[202-204] In addition, the BCLC system also incorporates the Okuda system, as well as other tumor characteristics, measurements of liver function, and patient performance status.[205]

Version 2.2025 © 2025 National Comprehensive Cancer Network© (NCCN©), All rights reserved. NCCN Guidelines® and this illustration may not be reproduced in any form without the express written permission of NCCN.

PLEASE NOTE that use of this NCCN Content is governed by the End-User License Agreement, and you MAY NOT distribute this Content or use it with any artificial intelligence model or tool.
Printed by Galya Basol Kochav on 1/5/2026 10:54:24 AM. Copyright © 2026 National Comprehensive Cancer Network, Inc. All Rights Reserved.

Although some of these systems have been found to be applicable for all stages of HCC (eg, BCLC),[37,205,206] limitations of all of these systems have been identified. For example, the AJCC staging system has limited usefulness since most patients with HCC do not undergo surgery. An analysis from the SEER database (1998–2013) questioned the AJCC definition of T2 disease (solitary tumor >2 cm with vascular invasion; multiple tumors <5 cm).[207] Specifically, survival was significantly different for patients with solitary tumors >2 cm than multifocal tumors <5 cm ($P < .001$), and, for patients with multifocal tumors <5 cm, survival was significantly associated with vascular invasion ($P < .001$). A number of studies have shown that particular staging systems perform well for specific patient populations likely related to differing etiologies. Furthermore, staging systems may be used to direct treatment and/or to predict survival outcomes following a particular type of therapeutic intervention. For example, the AJCC staging system has been shown to accurately predict survival for patients who underwent orthotopic liver transplantation.[208] The CLIP, CUPI, and GRETCH staging systems have been shown to perform well in predicting survival in patients with advanced disease.[209]

The CLIP system has been specifically identified as being useful for staging patients who underwent transarterial chemoembolization (TACE) and those treated in a palliative setting.[210,211] The utility of the BCLC staging system with respect to stratifying patients with HCC according to the natural history of the disease has been demonstrated in a meta-analysis of untreated patients with HCC enrolled in RCTs.[212] In addition, an advantage of the BCLC system is that it attempts to stratify patients into treatment groups, although the type of treatment is not included as a staging variable.[192] Furthermore, the BCLC staging system was shown to be very useful for predicting outcome in patients following liver transplantation or radiofrequency ablation (RFA).[213,214] In a multicenter cohort study of 1328 patients with HCC eligible for liver transplantation, survival benefit for liver transplantation was seen in patients with advanced liver cirrhosis and in those with intermediate tumors (BCLC stage D and stages B–C, respectively), regardless of the number and size of the lesions, provided there was no macroscopic vascular invasion and extrahepatic disease. However, treatment recommendations may vary.

A staging system based on a nomogram of particular clinicopathologic variables, including patient age, tumor size and margin status, postoperative blood loss, the presence of satellite lesions and vascular invasion, and serum AFP level, that was developed has been shown to perform well in predicting postoperative outcome for patients undergoing liver resection for HCC.[215] Another nomogram reported that total bilirubin, albumin, gamma-glutamyl transpeptidase, prothrombin time, clinically significant portal hypertension, and major resection were independent predictors of severe liver dysfunction or failure following liver surgery.[216] In addition, another study showed tumor size >2 cm, multifocal tumors, and vascular invasion to be independent predictors of poor survival in patients with early HCC following liver resection or liver transplantation.[217] This staging system has been retrospectively validated in a population of patients with early HCC.[218]

Due to the unique characteristics of HCC that vary with geographic region and etiology, many of the existing staging systems are specific to the region (and by extension etiology) in which they are developed and there is no universally accepted staging system that could be used across all institutions in different countries. The BCLC and the Hong Kong Liver Cancer staging systems are amongst the most widely used. Although no particular staging system (with the exception of the CTP score and TNM staging system) is currently used in these guidelines, following an initial workup, patients are stratified into one of the following three categories:

- Potentially resectable or transplantable by tumor burden; and operable by performance status or comorbidity

Version 2.2025 © 2025 National Comprehensive Cancer Network© (NCCN©), All rights reserved. NCCN Guidelines® and this illustration may not be reproduced in any form without the express written permission of NCCN.

PLEASE NOTE that use of this NCCN Content is governed by the End-User License Agreement, and you MAY NOT distribute this Content or use it with any artificial intelligence model or tool.
Printed by Galya Basol Kochav on 1/5/2026 10:54:24 AM. Copyright © 2026 National Comprehensive Cancer Network, Inc. All Rights Reserved.

- Liver-confined, unresectable disease, and deemed ineligible for transplant
- Extrahepatic/metastatic disease; and deemed ineligible for resection, transplant, or locoregional therapy

Treatment Options

All patients with HCC should be carefully evaluated by an experienced multidisciplinary team for the many available treatment options. It is important to reiterate that the management of HCC is complicated by the presence of underlying liver disease. Furthermore, different etiologies of HCC and their effects on the host liver may impact treatment response and outcome. These complexities make treatment decisions in patients with HCC challenging and are the reason for multidisciplinary care with the involvement of hepatologists, diagnostic and interventional radiologists, surgeons, medical oncologists, radiation oncologists, and pathologists with HCC expertise, thereby requiring careful coordination of care.[37] Given the comorbidities associated with this disease, patients need careful consideration of treatment choice given the risk of potential toxicities from treatment and potential benefits.

Surgery

Partial hepatectomy is a potentially curative therapy for patients with a solitary tumor of any size with no evidence of gross vascular invasion.[219] Partial hepatectomy for well-selected patients with HCC can now be performed with low operative morbidity and mortality (≤5%).[220,221] Results of large retrospective studies have shown 5-year survival rates of >50% for patients undergoing liver resection for HCC,[221-223] and some studies suggest that for selected patients with preserved liver function and early-stage HCC, liver resection is associated with a 5-year survival rate of approximately 70%.[223-225] However, recurrence rates at 5 years following liver resection, including recurrence due to metastases or new primary tumors, have been reported to exceed 70%.[205,222] Select patients with initially unresectable disease that respond to therapy can be considered for surgery. Consultation with a medical oncologist, interventional radiologist, and a multidisciplinary team is recommended to determine the timing of surgery after systemic therapy. Minimally invasive approaches by experienced surgeons have been proven to be safe and effective.[226]

Since liver resection for patients with HCC includes removal of functional liver parenchyma in the setting of underlying liver disease, careful patient selection, based on patient characteristics as well as characteristics of the liver and the tumor(s), is essential. Assessments of patient performance status must be considered; the presence of comorbidity has been shown to be an independent predictor of perioperative mortality.[227] Likewise, estimates of overall liver function and the size and function of the putative FLR, as well as technical considerations related to tumor and liver anatomy, must be taken into account before a patient is determined to have potentially resectable disease. Univariate analyses from a database study including 141 patients with HCC and liver cirrhosis who underwent resection at a German hospital showed that patient age >70 years ($P < .05$), Clavien grade of complications ($P < .001$), positive lymph vessels ($P < .001$), mechanical ventilation ($P < .001$), and body mass index (BMI) ($P < .05$) were significantly associated with survival.[228]

Resection is recommended only in the setting of preserved liver function. The CTP score provides an estimate of liver function, although it has been suggested that it is more useful as a tool to rule out patients for liver resection (ie, serving as a means to identify patients with substantially decompensated liver disease).[229] An evaluation of the presence of significant portal hypertension is also an important part of the surgical assessment. A meta-analysis including 11 studies showed that clinically significant portal hypertension is associated with increased 3- and 5-year mortality (pooled odds ratio [OR], 2.09; 95% CI, 1.52–2.88 for 3-year mortality; pooled OR, 2.07; 95% CI, 1.51–2.84 for 5-year mortality), as well

Version 2.2025 © 2025 National Comprehensive Cancer Network© (NCCN©), All rights reserved. NCCN Guidelines® and this illustration may not be reproduced in any form without the express written permission of NCCN.

PLEASE NOTE that use of this NCCN Content is governed by the End-User License Agreement, and you MAY NOT distribute this Content or use it with any artificial intelligence model or tool.
Printed by Galya Basol Kochav on 1/5/2026 10:54:24 AM. Copyright © 2026 National Comprehensive Cancer Network, Inc. All Rights Reserved.

as postoperative clinical decompensation (pooled OR, 3.04; 95% CI, 2.02–4.59).[230] In general, evidence of optimal liver function in the setting of liver resection is characterized by a CTP Class A score and absence of portal hypertension. However, in highly selected patients, limited liver resection is an option for patients with a CTP Class B score, particularly if liver function tests are normal and clinical signs of portal hypertension are absent. Further, limited resection may be feasible in patients who have mild portal hypertension. A prospective observational study of 223 patients with cirrhosis with HCC showed that, though portal hypertension was significantly associated with liver-related morbidity following resection, it was only associated with worse survival when there was biochemical evidence of liver decompensation. A multivariate analysis showed that albumin, but not portal hypertension, was significantly associated with survival following resection.[231]

With respect to tumor characteristics and estimates of the FLR following resection, preoperative imaging is essential for surgical planning.[98] Multiphasic CT/MRI can be used to facilitate characterization of the number and size of the HCC lesions in order to detect the presence of satellite nodules, extrahepatic metastasis, and tumor invasion of the portal vein or the hepatic veins/inferior vena cava, and to help establish the location of the tumors with respect to vascular and biliary structures.

Optimal tumor characteristics for liver resection are solitary tumors without major vascular invasion. Although no limitation on the size of the tumor is specified for liver resection, the risk of microscopic vascular invasion and dissemination increases with size.[220,232] However, in one study no evidence of vascular invasion was seen in approximately one-third of patients with single HCC tumors ≥10 cm.[220] Nevertheless, the presence of macro- or microscopic vascular invasion is a strong predictor of HCC recurrence.[220,233,234] The role of liver resection for patients with limited and resectable multifocal disease and/or signs of major vascular invasion is controversial, as the recurrence rates are extremely high.[219,233,235] A systematic review including 23 studies with 2412 patients showed that predicted 5-year OS and DFS rates for patients with multinodular disease who underwent resection were 35% and 22%, respectively.[236] The authors also examined survival rates of patients with macrovascular invasion who underwent resection (29 studies with 3659 patients). The 5-year predicted OS and DFS rates were 20% and 16%, respectively. Results of a retrospective analysis showed a 5-year OS rate of 81% for selected patients with a single tumor ≤5 cm, or ≤3 tumors ≤3 cm undergoing liver resection.[237]

Another critical preoperative assessment includes evaluation of the postoperative FLR volume, which serves as an indicator of postoperative liver function. Cross-sectional imaging is used to measure the FLR and total liver volume. The ratio of future remnant/total liver volume (subtracting tumor volume) is then determined.[238] The Panel recommends that this ratio be at least 20% in patients without cirrhosis and at least 30% to 40% in patients with chronic liver disease and a CTP A score.[239,240] For patients with chronic liver disease being considered for major resection, preoperative portal vein embolization (PVE) should be considered.[241,242] PVE is a safe and effective procedure for redirecting blood flow toward the portion of the liver that will remain following surgery.[243] Hypertrophy is induced in these segments of the liver while the embolized portion of the liver undergoes atrophy.[244] There are some investigational methods focused on improving FLR growth, such as lobar yttrium-90 (Y-90) or PVE combined with hepatic vein embolization or with arterial embolization.[245] The estimated future liver remnant function (eFLRF), which accounts for individual differences in body surface area, can also be calculated.[246] A comparison of the two methods showed that the eFLRF deviated from the FLR by ≥5% in 32% of 116 patients enrolled.[247] The kinetic growth rate is another common measure that predicts the risk of postoperative liver failure.[248]

Version 2.2025 © 2025 National Comprehensive Cancer Network© (NCCN©), All rights reserved. NCCN Guidelines® and this illustration may not be reproduced in any form without the express written permission of NCCN.

PLEASE NOTE that use of this NCCN Content is governed by the End-User License Agreement, and you MAY NOT distribute this Content or use it with any artificial intelligence model or tool.
Printed by Galya Basol Kochav on 1/5/2026 10:54:24 AM. Copyright © 2026 National Comprehensive Cancer Network, Inc. All Rights Reserved.

In one analysis, Roayaie et al categorized 8656 patients with HCC from Asia, Europe, and North America into one of four groups: 1) met standard criteria for resection and underwent resection (n = 718); 2) met standard criteria for resection but did not undergo resection (n = 144); 3) did not meet standard criteria for resection but underwent resection (n = 1624); and 4) did not meet standard criteria for resection and did not undergo resection (n = 6170).[249] For patients who met criteria for resection (including those who did not undergo resection), receiving a treatment other than resection was associated with an increased risk of mortality (hazard ratio [HR], 2.07; 95% CI, 1.35–3.17; $P < .001$). For patients who did not meet criteria for resection (including those who underwent resection), resection was associated with greater survival, relative to embolization (HR, 1.43; 95% CI, 1.27–1.61; $P < .001$) and other treatments (eg, Y-90 radioembolization, external beam radiation therapy [EBRT], systemic therapy) (HR, 1.78; 95% CI, 1.36–2.34; $P < .001$). However, survival rates for resection in these patients were worse than those for ablation (HR, 0.85; 95% CI, 0.74–0.98; $P = .022$) and transplantation (HR, 0.20; 95% CI, 0.14–0.27; $P < .001$). Despite the fact that these study results are powerfully influenced by selection bias, the study investigators suggest that criteria for resection could potentially be expanded, since patients who are not considered candidates for resection based on current criteria may still benefit.

Neoadjuvant Therapy

Data from an open-label phase II trial found that of 21 patients treated with neoadjuvant cemiplimab, 20 of them had a successful resection.[250] The patients also received adjuvant cemiplimab post-resection. Of these 20 patients, 20% achieved the primary endpoint of significant tumor necrosis, with an ORR of 15%. Ten percent of patients had grade 3 neoadjuvant-related treatment-related adverse events. Another phase II study randomized patients to receive nivolumab monotherapy or the combination of nivolumab and ipilimumab prior to and after surgery.[251] Thirty-three percent of patients receiving nivolumab monotherapy and 27% of patients receiving the combination treatment in the neoadjuvant setting had a major pathologic response. At 6 weeks before surgery, the ORR was 23% in the first group and 0% in the second group. A higher percentage of patients in the combination therapy group had a grade 3 adverse event (43% vs. 23%).

Postoperative Adjuvant Therapy

The phase III STORM trial examined sorafenib, an antiangiogenic agent approved for treating unresectable HCC, for use in the adjuvant setting for patients who underwent hepatic resection or ablation with curative intent. This international trial accrued 1114 patients, 62% of whom were Asian.[252] Patients were randomized to receive sorafenib (800 mg daily) or placebo until progression or for a maximum duration of 4 years. Treatment-emergent adverse events were high in both study groups, and sorafenib was not well tolerated at the intended study dose (median dose achieved was 578 mg daily [72.3% of the intended dose]). No significant between-group differences were observed in OS, relapse-free survival (RFS), and time to recurrence.

In a phase III study, patients with HCC with microvascular invasion (MVI) were randomized to receive adjuvant hepatic arterial infusion chemotherapy (HAIC) with FOLFOX or routine follow-up.[253] The results of the intention-to-treat analysis showed that adjuvant HAIC with FOLFOX significantly improved the median DFS (20.3 months vs. 10.0 months in the control group; HR, 0.59; 95% CI, 0.43–0.81; $P = .001$). At 1, 2, and 3 years, the OS rates were 93.8%, 86.4%, and 80.4%, respectively, for those treated with adjuvant HAIC with FOLFOX and 92.0%, 86.0%, and 74.9%, respectively, for those in the control group. 40.1% of those in the treatment group experienced recurrence, compared to 55.7% in the control group.

A study of 200 patients with MVI-HCC found that adjuvant TACE after resection led to significantly higher OS ($P = .03$), especially in patients with

Version 2.2025 © 2025 National Comprehensive Cancer Network© (NCCN©), All rights reserved. NCCN Guidelines® and this illustration may not be reproduced in any form without the express written permission of NCCN.

PLEASE NOTE that use of this NCCN Content is governed by the End-User License Agreement, and you MAY NOT distribute this Content or use it with any artificial intelligence model or tool.
Printed by Galya Basol Kochav on 1/5/2026 10:54:24 AM. Copyright © 2026 National Comprehensive Cancer Network, Inc. All Rights Reserved.

tumor diameter >5 cm or multinodular tumors.[254] DFS was also improved in these patients. A meta-analysis of 12 studies and 2190 patients found similar results. However, more studies are needed to validate these findings.[255]

Historically, postoperative prognosis for patients with HBV-related HCC has been poor. In a two-stage longitudinal study that enrolled 780 patients with HBV infection and HCC, viral load >10,000 copies per milliliter was correlated with poor outcomes.[256] Adjuvant antiviral therapy in a postoperative setting may improve outcomes. In a randomized trial including 163 patients, antiviral therapy with lamivudine, adefovir, dipivoxil, or entecavir significantly decreased HCC recurrence (HR, 0.48; 95% CI, 0.32–0.70) and HCC-related death (HR, 0.26; 95% CI, 0.14–0.50), and improved liver function at 6 months after surgery (P = .001).[256] In another RCT including 200 patients who received R0 resection for HBV-related HCC, adefovir improved RFS (P = .026) and OS (P = .001), relative to those who did not receive adefovir.[257] The RR of mortality with adefovir after resection was 0.42 (95% CI, 0.27–0.65; P < .001), and results indicated that antiviral therapy may protect against late tumor recurrence (HR, 0.35; 95% CI, 0.18–0.69; P = .002).

With the availability of newer potent antiviral therapies for chronic hepatitis C viral infection, similar trials are anticipated. Two meta-analyses showed that antiviral therapy for HBV or HCV after curative HCC treatment may improve outcomes including survival.[258,259] A meta-analysis including 10 studies with 1794 patients with HCV showed that sustained viral response is associated with improved OS (HR, 0.18; 95% CI, 0.11–0.29) and better RFS (HR, 0.50; 95% CI, 0.40–0.63) following resection or locoregional therapy for HCC.[260] Another study revealed that the use of antiviral therapy prior to or within 6 months of an HCC diagnosis was associated with improved survival outcomes in patients with HBV-related (adjusted HR, 0.60; 95% CI, 0.43–0.83; P = .002) and HCV-related (adjusted HR, 0.18; 95% CI, 0.11–0.31; P < .0001) HCC following curative intent resection.[261] There is some concern that the rising use of DAAs might increase HCC recurrence or progression following treatment.[262-264] This is an area of controversy, and well-designed trials are needed to determine the mechanism through which HCC incidence increases.[262,263] The Panel recommends that providers discuss the potential use of antiviral therapy for carriers of hepatitis with a hepatologist to individualize postoperative therapy.

A meta-analysis including five studies (two RCTs and three case-control studies) with 334 patients showed that iodine-131 lipiodol injected into the hepatic artery following resection may improve DFS (Peto OR, 0.47; 95% CI, 0.37–0.59) and OS (Peto OR, 0.50; 95% CI, 0.39–0.64).[265] However, more randomized studies with long follow-up are needed to determine the benefit of this treatment in patients with resected HCC.

Immunotherapy, or using the immune system to treat cancer, is beginning to be investigated as adjuvant HCC treatment. A systematic review of adjuvant treatment options for HCC including 14 studies (two immunotherapy studies with 277 patients) showed that immunotherapy may prevent recurrence in resected HCC.[266] In a Korean phase III randomized trial, the efficacy and safety of activated cytokine-induced killer cells was examined as adjuvant immunotherapy for HCC.[267] Patients (N = 230) who received the adjuvant immunotherapy had greater RFS relative to patients in the control group (HR, 0.63; 95% CI, 0.43–0.94; P = .01).

The IMbrave050 study randomized patients with CTP Class A HCC 1:1 to undergo active surveillance or to receive adjuvant treatment with atezolizumab plus bevacizumab following curative therapy.[268] Crossover from the active surveillance group was permitted after recurrence. The combination treatment improved the primary endpoint of RFS (HR, 0.72; 95% CI, 0.53–0.98; P = .012), as determined by an independent review facility, compared to active surveillance. The HR for the secondary

Version 2.2025 © 2025 National Comprehensive Cancer Network© (NCCN©), All rights reserved. NCCN Guidelines® and this illustration may not be reproduced in any form without the express written permission of NCCN.

PLEASE NOTE that use of this NCCN Content is governed by the End-User License Agreement, and you MAY NOT distribute this Content or use it with any artificial intelligence model or tool.
Printed by Galya Basol Kochav on 1/5/2026 10:54:24 AM. Copyright © 2026 National Comprehensive Cancer Network, Inc. All Rights Reserved.

endpoint of RFS, as assessed by the investigator, was 0.70 (95% CI, 0.54–0.91; *P* = .007). The risk for recurrence, as assessed by an independent review facility, was 33% less for patients treated with atezolizumab plus bevacizumab (HR, 0.67; 95% CI, 0.52–0.88; *P* = .003). Grade 3/4 and grade 5 adverse events were reported in 41.0% and 2%, respectively, in the treatment group, and 13% and <1%, respectively, in the control group. However, an updated analysis, published in an abstract, demonstrated that the RFS benefit was not sustained.[269] Following the updated analysis, the Panel has not included atezolizumab plus bevacizumab as an adjuvant therapy option.

Liver Transplantation

Liver transplantation is a potentially curative therapeutic option for patients with early HCC. It is especially appealing since it removes both detectable and undetectable tumor lesions, treats underlying liver cirrhosis, and avoids surgical complications associated with a small FLR. However, there is also a risk of potential complications such as early mortality and issues related to chronic immunosuppression.[270] In a landmark study published in 1996, Mazzaferro et al proposed the Milan criteria (single tumors ≤5 cm in diameter or no more than three nodules ≤3 cm in diameter in patients with multiple tumors and no macrovascular invasion) for patients with unresectable HCC and cirrhosis.[271] The 4-year OS and RFS rates were 85% and 92%, respectively, when liver transplantation was restricted to a subgroup of patients meeting the Milan selection criteria. These results have been supported by studies in which patient selection for liver transplantation was based on these criteria.[272] These selection criteria were adopted by UNOS, because they identify a subgroup of patients with HCC whose liver transplantation results are similar to those who underwent liver transplantation for end-stage cirrhosis without HCC.

The UNOS criteria (radiologic evidence of a single lesion ≥2 cm and ≤5 cm in diameter, or 2–3 lesions ≥1 cm and ≤3 cm in diameter, and no evidence of macrovascular involvement or extrahepatic disease) specify that patients eligible for liver transplantation should not be candidates for liver resection.[273] Therefore, liver transplantation has been generally considered to be the initial treatment of choice for well-selected patients with early-stage HCC and moderate-to-severe cirrhosis (ie, patients with CTP Class B and C scores), with partial hepatectomy generally accepted as the best option for the first-line treatment of patients with early-stage HCC and CTP Class A scores when tumor location is amenable to resection. Retrospective studies have reported similar survival rates for hepatic resection and liver transplantation in patients with early-stage HCC when accounting for the fallout while on waiting lists for transplantation.[223,274-277] However, there are no prospective randomized studies that have compared the effectiveness of liver resection and liver transplantation for this group of patients.

The MELD score as a measure of liver function is also used as a measure of pre-transplant mortality.[179] The MELD score was adopted by UNOS in 2002 to provide an estimate of risk of death within 3 months for patients on the waiting list for cadaveric liver transplant. MELD score is also used by UNOS to assess the severity of liver disease and prioritize the allocation of the liver transplants. According to the current Organ Procurement and Transplantation Network (OPTN) policy, patients with AFP levels ≤1000 ng/mL and with T2 tumors are eligible for a standardized MELD exception.[278] In a retrospective analysis of data provided by UNOS of 15,906 patients undergoing first-time liver transplantation during 1997 to 2002 and 19,404 patients undergoing the procedure during 2002 to 2007, 4.6% of liver transplant recipients had HCC compared with 26% in 2002 to 2007, with most patients in the latter group receiving an “HCC MELD exception.”[279] From 2002 to 2007, patients with an “HCC MELD-exception” had similar survival to patients without HCC. Important predictors of poor post-transplantation survival for patients with HCC were a MELD score of ≥20 and serum AFP level of ≥455 ng/mL,[279] although the reliability of the

Version 2.2025 © 2025 National Comprehensive Cancer Network© (NCCN©), All rights reserved. NCCN Guidelines® and this illustration may not be reproduced in any form without the express written permission of NCCN.

PLEASE NOTE that use of this NCCN Content is governed by the End-User License Agreement, and you MAY NOT distribute this Content or use it with any artificial intelligence model or tool.
Printed by Galya Basol Kochav on 1/5/2026 10:54:24 AM. Copyright © 2026 National Comprehensive Cancer Network, Inc. All Rights Reserved.

MELD score as a measure of post-transplantation mortality is controversial. Survival was also significantly lower for the subgroup of patients with HCC tumors between 3 and 5 cm.

Expansion of the Milan/UNOS criteria to provide patients who have marginally larger HCC tumors with liver transplant eligibility is an active area of debate, with exceptional cases frequently prompting analysis and revisions.[205,272,280,281] An expanded set of criteria including patients with a single HCC tumor ≤6.5 cm, with a maximum of three total tumors with no tumor >4.5 cm (and cumulative tumor size <8 cm) as liver transplant candidates has been proposed by Yao et al at the University of California at San Francisco (UCSF).[282,283] Studies evaluating the post-transplantation survival of patients who exceed the Milan criteria but meet the UCSF criteria show wide variation in 5-year survival rates (range, 38%–93%).[280-282,284-286] An argument in favor of expanding the Milan/UNOS criteria includes the general recognition that many patients with HCC tumors exceeding the Milan criteria can be cured by liver transplant. Opponents of an expansion of the Milan/UNOS criteria cite the increased risk of vascular invasion and tumor recurrence associated with larger tumors and higher HCC stage, the shortage of donor organs, and taking organs away from patients with liver failure who do not have HCC.[272,280,284] Some support for the former objection comes from a large retrospective analysis of the UNOS database showing significantly lower survival for the subgroup of patients with tumors between 3 and 5 cm compared with those who had smaller tumors.[279]

There is a risk of tumor recurrence following liver transplantation. A group from France argued that the Milan criteria may be overly restrictive and thus developed a predictive model of HCC recurrence that combines AFP value with tumor size and number.[287] Analyses from samples of patients from France and Italy who underwent liver transplantation showed that this AFP model predicted an increase in 5-year risk of recurrence and decreased survival.[287,288] The Panel does not provide specific recommendations regarding whether or not AFP should be considered a transplant criterion, and this may depend on local practice. Another analysis of patients who underwent liver transplantation (N = 1061) showed that MVI, AFP at time of transplant, and sum of the largest diameter of viable tumor plus number of viable tumors on explant were associated with HCC recurrence.[289]

Resection or liver transplantation can be considered for patients with CTP Class A liver function or for highly selected patients with CTP Class B liver function who meet UNOS criteria/extended criteria (www.unos.org) and are resectable. The guidelines recommend that these patients be evaluated by a multidisciplinary team for individualized decision-making when deciding an optimal treatment approach. The OPTN has proposed imaging criteria for patients with HCC who may be candidates for transplant.[138] Specifically, they propose a classification system for nodules identified by well-defined imaging from contrast-enhanced CT or MRI. OPTN also provides guidance on equipment specifications and use of a standardized protocol. While the Panel does not have a recommendation regarding liver transplantation in older adults with HCC, some centers report transplant in highly selected patients >70 years.[290,291] A systematic review of 50 studies with 4169 older patients and 13,158 young patients with HCC found that while old age increased the risk of mortality after resection (3.0% vs. 1.2%), the 5-year OS was only marginally lower (51% vs. 56%).[292]

Bridge Therapy

Bridge therapy is used to decrease tumor progression and the dropout rate from the liver transplantation waiting list.[293] It is also an effective way to help select the best patients for transplant and is recommended for patients who meet the transplant criteria. An analysis including 205 patients from a transplant center registry who had HCC showed that bridging locoregional therapy was associated with survival following transplant (P = .005).[294] A

Version 2.2025 © 2025 National Comprehensive Cancer Network© (NCCN©), All rights reserved. NCCN Guidelines® and this illustration may not be reproduced in any form without the express written permission of NCCN.

PLEASE NOTE that use of this NCCN Content is governed by the End-User License Agreement, and you MAY NOT distribute this Content or use it with any artificial intelligence model or tool.
Printed by Galya Basol Kochav on 1/5/2026 10:54:24 AM. Copyright © 2026 National Comprehensive Cancer Network, Inc. All Rights Reserved.

number of studies have investigated the role of locoregional therapies as a bridge to liver transplantation in patients on a waiting list.[295,296] These studies included RFA/microwave ablation (MWA)[297-300]; transarterial embolization (TAE)[301,302]; TACE,[299,303] including conventional TACE[299,304,305] and TACE with drug-eluting beads (DEB-TACE)[306]; selective internal radiation therapy (SIRT) or transarterial radioembolization (TARE) with Y-90 microspheres[307]; radiation therapy (RT)[308]; and TACE followed by three-dimensional (3D) conformal RT (3D-CRT),[309] as "bridge" therapies.

A meta-analysis showed that bridge therapy did not significantly impact post-transplantation mortality, survival, and recurrence rates, compared to transplant alone.[310] The small size and retrospective methodology of studies in this area, as well as the heterogeneous nature of the study populations, and the absence of RCTs evaluating the utility of bridge therapy for reducing the liver transplantation waiting list drop-out rate, limit the conclusions that can be drawn.[310-312] Nevertheless, the use of bridge therapy in this setting is increasing, and it is administered at most NCCN Member Institutions, especially in areas where there are long wait times for a transplant.

Downstaging Therapy

Downstaging therapy is used to reduce the tumor burden in selected patients with more advanced HCC (without distant metastasis) who are beyond the accepted transplant criteria with the goal of future transplant.[293,313,314] A meta-analysis including three studies showed that downstaging therapy was associated with increased 1- (RR, 1.11; 95% CI, 1.01–1.23) and 5-year survival (RR, 1.17; 95% CI, 1.03–1.32) post-transplant, compared to transplant alone.[310] Downstaging therapy did not significantly increase RFS. However, the three studies included in these analyses were heterogeneous and biased by the fact that outcomes were measured in patients who responded well to therapy. A systematic review including 13 studies with 950 patients showed that downstaging decreased tumor burden to within Milan criteria (pooled success rate of 0.48; 95% CI, 0.39–0.58), with recurrence rates after transplantation at 16% (95% CI, 0.11–0.23).[315] In a multicenter study, patients with HCC beyond the Milan criteria who received locoregional therapy for downstaging had an OS of 64.3% and an RFS of 59.5% at 5 years post-transplant compared to 71.3% and 68.2%, respectively, in patients with HCC within the Milan criteria.[316] The OS and PFS were 60.2% and 53.8%, respectively, in patients who did not receive downstaging therapy. Additionally, compared to these patients, those who did receive downstaging therapy had an improved RFS (60% vs. 54%; $P = .043$) and a decreased rate of HCC recurrence (18% vs. 32%; $P < .001$). Candidates are eligible for a standardized MELD exception if, before completing locoregional therapy, they have lesions that meet one of the following: 1) one lesion >5 cm and ≤8 cm; 2) two or three lesions that meet all of the following: each lesion ≤5 cm, with at least one lesion >3 cm and a total diameter of all lesions ≤8 cm; and 3) four or five lesions each <3 cm, and a total diameter of all lesions ≤8 cm.[278] The UCSF criteria can be used as the current limit for consideration of downstaging and potential candidates for this therapy should be assessed by a transplant center.

Prospective studies have demonstrated that downstaging (prior to transplant) with percutaneous ethanol injection (PEI),[317] RFA,[317,318] TACE,[317-321] TARE with Y-90 microspheres,[320] and transarterial chemoinfusion[322] is associated with improved outcomes such as DFS and recurrence following transplant. However, such studies have used different selection criteria for the downstaging therapy and different transplant criteria after successful downstaging. In some studies, response to locoregional therapy has been associated with good outcomes after transplantation.[323-325] In a phase IIb/III randomized trial, patients underwent downstaging with locoregional, surgical, or systemic therapies. Liver transplantation was then performed in one group.[326] The results showed that transplantation improved the 5-year tumor-free survival (77% vs. 18%) and the 5-year OS (78% vs. 31%) compared to non-transplantation.

Version 2.2025 © 2025 National Comprehensive Cancer Network© (NCCN©), All rights reserved. NCCN Guidelines® and this illustration may not be reproduced in any form without the express written permission of NCCN.

PLEASE NOTE that use of this NCCN Content is governed by the End-User License Agreement, and you MAY NOT distribute this Content or use it with any artificial intelligence model or tool.
Printed by Galya Basol Kochav on 1/5/2026 10:54:24 AM. Copyright © 2026 National Comprehensive Cancer Network, Inc. All Rights Reserved.

Another study demonstrated survival and recurrence rates of 52.1% and 20.6%, respectively, at 10 years post transplant, in patients who underwent downstaging therapy.[327] These rates were 61.5% and 13.3%, respectively, in patients with disease that was within the Milan criteria, and 43.3% and 41.1%, respectively, in patients who did not undergo downstaging therapy. Further validation is needed to define the endpoints for successful downstaging prior to transplant.[314]

The NCCN Guidelines recommend that patients with disease meeting transplant criteria, namely the UNOS criteria, be considered for transplantation using either cadaveric or living donation. Patients with tumor characteristics that are marginally outside of the UNOS guidelines may be considered for transplantation at select institutions. For patients with initial tumor characteristics beyond the Milan criteria who have undergone successful downstaging therapy (ie, tumor currently meeting Milan criteria), transplantation can also be considered.

Locoregional Therapies

Locoregional therapies are directed toward inducing selective tumor necrosis, and are broadly classified into ablation, arterially directed therapies, and RT. Multidisciplinary review is recommended. Tumor necrosis induced by locoregional therapy is typically estimated by the extent to which contrast uptake on dynamic CT/MRI is diminished at a specified time following the treatment when compared with pretreatment imaging findings. The absence of contrast uptake within the treated tumor is believed to be an indication of tumor necrosis. A number of factors are involved in measuring the effectiveness of locoregional therapies, and the criteria for evaluating tumor response are evolving.[190,328-331] A few studies have shown that the use of modified RECIST (mRECIST) is more suitable than RECIST.[332,333] AFP response after locoregional therapy has also been reported to be a reliable predictor of tumor response, time to progression (TTP), PFS, and OS.[334]

Ablation

In an ablative procedure, tumor necrosis can be induced by thermal ablation (RFA or MWA). Ablative procedures can be performed by surgical, percutaneous (ethanol injection), laparoscopic, or open approaches. RFA and MWA have largely replaced PEI, although PEI is used in select patients.

The safety and efficacy of RFA and PEI in the treatment of patients with CTP Class A early-stage HCC tumors (either a single tumor ≤5 cm or multiple tumors [up to 3 tumors] each ≤3 cm) has been compared in a number of RCTs.[335-342] Both RFA and PEI were associated with relatively low complication rates. RFA was shown to be superior to PEI with respect to complete response (CR) rate (65.7% vs. 36.2%, respectively; P = .0005)[340] and local recurrence rate (3-year local recurrence rates were 14% and 34%, respectively; P = .012).[338] Local tumor progression rates were also significantly lower for RFA than for PEI (4-year local tumor progression rates were 1.7% and 11%, respectively; P = .003).[339]

In addition, in two studies, patients in the RFA arm were shown to require fewer treatment sessions.[336,339] However, an OS benefit for RFA over PEI was demonstrated in three randomized studies performed in Asia,[337-339] whereas three European randomized studies did not show a significant difference in the OS between the two treatment arms.[336,340,341] In an Italian randomized trial of 143 patients with HCC, the 5-year survival rates were 68% and 70%, respectively, for PEI and RFA groups; the corresponding RFS rates were 12.8% and 11.7%, respectively.[341] Nevertheless, independent meta-analyses of randomized trials that have compared RFA and PEI have concluded that RFA is superior to PEI with respect to OS and tumor response in patients with early-stage HCC, particularly for tumors >2 cm.[343-345] Results of some long-term studies show survival rates of >50% at 5 years for patients with early HCC treated with RFA.[346-349]

Version 2.2025 © 2025 National Comprehensive Cancer Network© (NCCN©), All rights reserved. NCCN Guidelines® and this illustration may not be reproduced in any form without the express written permission of NCCN.

PLEASE NOTE that use of this NCCN Content is governed by the End-User License Agreement, and you MAY NOT distribute this Content or use it with any artificial intelligence model or tool.
Printed by Galya Basol Kochav on 1/5/2026 10:54:24 AM. Copyright © 2026 National Comprehensive Cancer Network, Inc. All Rights Reserved.

The reported OS and recurrence rates vary widely across the studies for patients treated with RFA, which is most likely due to differences in the size and number of tumors and, perhaps more importantly, tumor biology and the extent of underlying liver function in the patient populations studied. In a multivariate analysis, CTP Class, tumor size, and tumor number were independent predictors of survival.[347-349]

RFA and PEI have also been compared with resection in randomized studies. In the only randomized study that compared PEI with resection in 76 patients without cirrhosis, with one or two tumors ≤3 cm, PEI was equally as effective as resection.[350] On the other hand, studies that have compared RFA and resection have not provided conclusive evidence (reviewed by Weis et al[342]). RFA and liver resection in the treatment of patients with HCC have been compared in randomized prospective studies.[351-355] The results of one randomized trial showed a significant survival benefit for resection over RFA in 235 patients with small HCC conforming to the Milan criteria.[352] The 5-year OS rates were 54.8% and 75.6%, respectively, for the RFA group and resection. The corresponding RFS rates for the two groups were 28.7% and 51.3%, respectively. However, more patients in the resection group were lost to follow-up than the RFA group. Conversely, other randomized studies demonstrated that percutaneous local ablative therapy with RFA is as effective as resection for patients with early-stage disease (eg, small tumors).[351,353-355] These studies did not show statistically significant differences in OS and DFS between the two treatment groups. In addition, in one of the studies, tumor location was an independent risk factor associated with survival.[353] These studies, however, were limited by the small number of patients (180 patients and 168 patients, respectively) and the lack of a non-inferiority design. Nevertheless, results from these studies support ablation as an alternative to resection in patients with small (<3 cm), properly located tumors.

RFA has been compared to resection in some meta-analyses, which have shown that resection is generally associated with better survival outcomes than RFA[356-359] but is associated with more complications and morbidity from complications.[356,358] One meta-analysis reported no significant difference in OS but determined that treatment with resection improved the RFS (when RCTs were analyzed) at 5 years (HR, 0.75; 95% CI, 0.62–0.92; $P = .006$).[360] Subgroup analyses from one meta-analysis showed no significant differences in 1-year mortality and disease recurrence when including only studies with patients who had solitary or small tumors (>3 cm).[357] Another meta-analysis also found no significant difference in OS and 1-year DFS rates in patients with HCC that meets the Milan criteria.[361] One meta-analysis comparing RFA to resection in recurrent HCC (including 6 retrospective comparative studies) showed that 3- and 5-year DFS rates were greater for resection, relative to RFA (OR, 2.25; 95% CI, 1.37–3.68; $P = .001$; OR, 3.70; 95% CI, 1.98–6.93; $P < .001$, respectively).[362] Yang et al[363] also reported a higher OS with resection compared to RFA in recurrent HCC (HR, 0.81; 95% CI, 0.68–0.95). The DFS rate was not significantly different during the entire follow-up period (HR, 0.90; 95% CI, 0.76–1.07) but was significantly higher at 2 to 5 years in patients who underwent resection.

Subgroup analyses from some retrospective studies suggest that tumor size is a critical factor in determining the effectiveness of RFA or resection.[297,298,361,364-367] Mazzaferro et al reported findings from a prospective study of 50 consecutive patients with liver cirrhosis undergoing RFA while awaiting liver transplantation (the rate of overall complete tumor necrosis was 55% [63% for tumors ≤3 cm and 29% for tumors ≥3 cm]).[298] In a retrospective analysis, Vivarelli et al reported that OS and DFS were significantly higher with surgery compared to percutaneous RFA. The advantage of surgery was more evident for patients with CTP Class A single tumors greater than 3 cm in diameter and the results were similar in two groups for patients with CTP Class B liver function.[365] In another

Version 2.2025 © 2025 National Comprehensive Cancer Network© (NCCN©), All rights reserved. NCCN Guidelines® and this illustration may not be reproduced in any form without the express written permission of NCCN.

retrospective analysis of 40 patients with CTP Class A or B HCC treated with percutaneous ablative procedures, the overall rate of complete necrosis was 53%, which increased to 62% when considering only the subset of tumors <3 cm treated with RFA.[297] In a propensity case-matched study that compared liver resection and percutaneous ablative therapies in 478 patients with CTP A cirrhosis, survival was not different between resection and ablation for tumors that met the Milan criteria; however, resection was associated with significantly improved long-term survival for patients with single HCC tumors >5 cm or multiple tumors (up to 3 tumors) >3 cm.[366] Median survival for the resection group was 80 months and 83 months, respectively, compared to 21.5 months and 19 months, respectively, for patients treated with ablative procedures.

Some investigators consider RFA as the first-line treatment in highly selected patients with HCC tumors that are ≤2 cm in diameter in an accessible location and away from major vascular and biliary structures and adjacent organs.[368,369] In one study, RFA as the initial treatment in 218 patients with a single HCC lesion ≤2.0 cm induced complete necrosis in 98% of patients (214 of 218 patients).[368] After a median follow-up of 31 months, the sustained CR rate was 97% (212 of 218 patients). In a retrospective comparative study, Peng et al reported that percutaneous RFA was better than resection in terms of OS and RFS, especially for patients with central HCC tumors <2 cm.[369] The 5-year OS rates in patients with central HCC tumors were 80% for RFA compared to 62% for resection (P = .02). The corresponding RFS rates were 67% and 40%, respectively (P = .033).

MWA is an alternative to RFA for the treatment of patients with small or unresectable HCC.[370-374] So far, only two randomized trials have compared MWA with resection and RFA.[370,374] In the RCT that compared percutaneous RFA with microwave coagulation, no significant differences were observed between these two procedures in terms of therapeutic effects, complication rates, and the rates of residual foci of untreated disease.[370] In a randomized study that evaluated the efficacy of MWA and resection in the treatment of HCC conforming to Milan criteria, MWA was associated with lower DFS rates than resection with no differences in OS rates.[374]

Irreversible electroporation (IRE) is an emerging modality for tumor ablation.[375] It targets tumor tissue by delivering non-thermal high-voltage electric pulses. By doing so, it increases permeability of the cell membrane, disrupting cellular homeostasis and triggering apoptosis. IRE has some advantages over RFA, notably the lack of “heat sink” effect and the ability to treat near vessels, bile ducts, and other critical structures.[376,377] However, IRE can cause cardiac arrhythmias and uncontrolled muscle contractions.[378] Some small studies have shown that IRE treatment for unresectable HCC is safe and feasible.[379-381] In a small nonrandomized trial including 30 patients with malignant liver tumors, none of the eight patients with HCC experienced a recurrence through 6-month follow-up.[381] Recurrences have been reported following IRE for larger tumors.[378,380] Larger studies are needed to determine the effectiveness of IRE for local HCC treatment.

Although inconclusive, available evidence suggests that the choice of ablative therapy for patients with early-stage HCC should be based on tumor size and location, underlying liver function, as well as available local radiologist expertise and experience. Ablative therapies are most effective for tumors <3 cm that are in an appropriate location away from other organs and major vessels/bile ducts, with the best outcomes in tumors <2 cm.

Arterially Directed Therapies

Arterially directed therapy involves the selective catheter-based infusion of particles targeted to the arterial branch of the hepatic artery feeding the portion of the liver in which the tumor is located.[382] Arterially directed

Version 2.2025 © 2025 National Comprehensive Cancer Network© (NCCN©), All rights reserved. NCCN Guidelines® and this illustration may not be reproduced in any form without the express written permission of NCCN.

PLEASE NOTE that use of this NCCN Content is governed by the End-User License Agreement, and you MAY NOT distribute this Content or use it with any artificial intelligence model or tool.
Printed by Galya Basol Kochav on 1/5/2026 10:54:24 AM. Copyright © 2026 National Comprehensive Cancer Network, Inc. All Rights Reserved.

therapy is made possible by the dual blood supply to the liver; whereas the majority of the blood supply to normal liver tissue comes from the portal vein, blood flow to liver tumors is mainly from the hepatic artery.[96] Furthermore, HCC tumors are hypervascular resulting from increased blood flow to tumor relative to normal liver tissue. Arterially directed therapies that are currently in use include TAE, conventional TACE, DEB-TACE, and SIRT/TARE with Y-90 microspheres.

The principle of TAE is to reduce or eliminate blood flow to the tumor, resulting in tumor ischemia followed by tumor necrosis. Gelatin sponge particles, polyvinyl alcohol particles, and polyacrylamide microspheres have been used to block arterial flow. TAE has been shown to be an effective treatment option for patients with unresectable HCC.[383-386] In a multicenter retrospective study of 476 patients with unresectable HCC, TAE was associated with prolonged survival compared to supportive care (P = .0002). The 1-, 2-, and 5-year survival rates were 60.2%, 39.3%, and 11.5%, respectively, for patients who underwent TAE. The corresponding survival rates were 37.3%, 17.6%, and 2%, respectively, for patients who underwent supportive care.[384] In a multivariate analysis, tumor size <5 cm and earlier CLIP stage were independent factors associated with a better survival. In another retrospective analysis of 322 patients undergoing TAE for the treatment of unresectable HCC in which a standardized technique (including small particles to cause terminal vessel blockade) was used, 1-, 2-, and 3-year OS rates of 66%, 46%, and 33%, respectively, were observed. The corresponding survival rates were 84%, 66%, and 51%, respectively, when only the subgroup of patients without extrahepatic spread or portal vein involvement was considered.[385] In multivariate analysis, tumor size ≥5 cm, ≥5 tumors, and extrahepatic disease were identified as predictors of poor prognosis following TAE.

TACE is distinguished from TAE in that, in addition to arterial blockade, the goal is to also deliver a highly concentrated dose of chemotherapy to tumor cells, prolong the contact time between the chemotherapeutic agents and the cancer cells, and minimize systemic toxicity of chemotherapy.[387] The results of two RCTs and one retrospective case-control study have shown a survival benefit for TACE compared with supportive care in patients with unresectable HCC.[388-390] In one study that randomized patients with unresectable HCC to TACE or best supportive care, the actuarial survival was significantly better in the TACE group (1 year, 57%; 2 years, 31%; 3 years, 26%) than in the control group (1 year, 32%; 2 years, 11%; 3 years, 3%; P = .002).[388] Although death from liver failure was more frequent in patients who received TACE, the liver function of the survivors was not significantly different between the two groups. In the other randomized study, which compared TAE and TACE with supportive care for patients with unresectable HCC, the 1- and 2-year survival rates were 82%; 63%, 75%, and 50%; and 63% and 27% for patients in the TACE, TAE, and supportive care arms, respectively.[389] The majority of the patients in the study had liver function classified as CTP Class A, a performance status of 0, and a main tumor nodule size of about 5 cm. For the group of evaluable patients receiving TACE or TAE, partial response (PR) and CR rates sustained for at least 6 months were observed in 35% (14/40) and 43% (16/37), respectively. However, this study was terminated early due to an obvious benefit associated with TACE. Although this study demonstrated that TACE was significantly more effective than supportive care (P = .009), there were insufficient patients in the TAE group to make any statement regarding its effectiveness compared to either TACE or supportive care. In a randomized trial, the effectiveness of TAE was compared to that of doxorubicin-based TACE in 101 patients with HCC.[391] Study investigators did not find statistically significant differences in response, PFS, and OS between the two groups. Some institutions prefer the use of bland embolization using particles without chemotherapy.[391]

A retrospective analysis of patients with advanced HCC who had undergone embolization in the past 10 years revealed that TACE (with

Version 2.2025 © 2025 National Comprehensive Cancer Network© (NCCN©), All rights reserved. NCCN Guidelines® and this illustration may not be reproduced in any form without the express written permission of NCCN.

PLEASE NOTE that use of this NCCN Content is governed by the End-User License Agreement, and you MAY NOT distribute this Content or use it with any artificial intelligence model or tool.
Printed by Galya Basol Kochav on 1/5/2026 10:54:24 AM. Copyright © 2026 National Comprehensive Cancer Network, Inc. All Rights Reserved.

doxorubicin plus mitomycin C) is significantly associated with prolonged PFS and TTP but not OS, as compared to TAE.[392] In a multivariable analysis, the type of embolization and CLIP score were significant predictors of PFS and TTP, whereas CLIP score and AFP were independent predictors of OS.

Many of the clinical studies evaluating the effectiveness of TAE and/or TACE in the treatment of patients with HCC are confounded by use of a wide range of treatment strategies, including type of embolic particles, type of chemotherapy and type of emulsifying agent (for studies involving TACE), and number of treatment sessions. In a randomized trial, the effectiveness of TAE was compared to that of doxorubicin-based TACE in 101 patients with HCC.[391] Study investigators did not find statistically significant differences in response, PFS, and OS between the two groups.

Complications common to TAE and TACE include non-target embolization, liver failure, pancreatitis, and cholecystitis. Additional complications following TACE include acute portal vein thrombosis (PVT), bone marrow suppression, and pancreatitis (very rare), although the reported frequencies of serious adverse events vary across studies.[76,393] Reported rates of treatment-related mortality for TAE and TACE are usually well under 5%.[76,385,389,393] A transient post-embolization syndrome involving fever, abdominal pain, and intestinal ileus is relatively common in patients undergoing these procedures.[76,393] A retrospective study from a single institution in Spain showed that PVT and liver function categorized as CTP Class C were significant predictors of poor prognosis in patients treated with TACE.[394] However, TACE has since been shown to be safe and feasible in highly selected patients with HCC and PVT,[395] and results of a meta-analysis (5 prospective studies with 600 patients) showed that TACE may improve survival in these patients, compared to patients who received control treatments.[396] Therefore, the Panel considers TACE to be safe in highly selected patients who have limited tumor invasion of the portal vein. TACE is not recommended in those with liver function characterized as CTP Class C (absolute contraindication). Because TAE can increase the risk of liver failure, hepatic necrosis, and liver abscess formation in patients with biliary obstruction, the Panel recommends that a total bilirubin level >3 mg/mL should be considered as a relative contraindication for TACE or TAE unless segmental treatment can be performed. Furthermore, patients with previous biliary enteric bypass have an increased risk of intrahepatic abscess following TACE and should be considered for prolonged antibiotic coverage at the time of the procedure.[397,398]

TACE causes increased hypoxia leading to an up-regulation of vascular endothelial growth factor receptor (VEGFR) and insulin-like growth factor receptor 2 (IGFR-2).[399] Increased plasma levels of VEGFR and IGFR-2 have been associated with the development of metastasis after TACE.[400,401] These findings have led to the evaluation of TACE in combination with sorafenib in patients with residual or recurrent tumor not amenable to additional locoregional therapies.[402-409]

DEB-TACE has also been evaluated in patients with unresectable HCC.[410-417] A randomized study (PRECISION V) of 212 patients with localized, unresectable HCC with CTP Class A or B cirrhosis and without nodal involvement showed no difference in CR, objective response, and disease control between DEB-TACE with doxorubicin-eluting embolic beads and conventional TACE with doxorubicin.[412] Overall, DEB-TACE was not superior to conventional TACE with doxorubicin (P = .11) in this study. In a subgroup analysis, DEB-TACE was associated with a significant increase in objective response (P = .038) compared to conventional TACE in patients with CTP Class B, Eastern Cooperative Oncology Group (ECOG) performance status 1, bilobar disease, and recurrent disease. DEB-TACE was also associated with improved tolerability with a significant reduction in serious liver toxicity and a significantly lower rate of doxorubicin-related

Version 2.2025 © 2025 National Comprehensive Cancer Network© (NCCN©), All rights reserved. NCCN Guidelines® and this illustration may not be reproduced in any form without the express written permission of NCCN.

PLEASE NOTE that use of this NCCN Content is governed by the End-User License Agreement, and you MAY NOT distribute this Content or use it with any artificial intelligence model or tool.
Printed by Galya Basol Kochav on 1/5/2026 10:54:24 AM. Copyright © 2026 National Comprehensive Cancer Network, Inc. All Rights Reserved.

side effects, compared to conventional TACE.[412] In another small prospective randomized study (n = 83), Malagari et al also showed that DEB-TACE resulted in higher response rates, lower recurrences, and longer TTP compared to TAE in patients with intermediate-state HCC; however, this study also did not show any OS benefit for DEB-TACE.[413] A randomized study comparing DEB-TACE to conventional TACE in 177 patients with intermediate-stage, unresectable, persistent, or recurrent HCC revealed no significant efficacy or safety differences between the two approaches; however, DEB-TACE was associated with less post-procedural abdominal pain.[417] Conversely, Dhanasekaran et al reported a survival advantage for DEB-TACE over conventional TACE in a prospective randomized study of 71 patients with unresectable HCC.[414] However, these results are from underpowered studies and need to be confirmed in large prospective studies. The findings from a meta-analysis of 28 studies suggest that DEB-TACE led to longer OS compared to TARE and conventional TACE.[418] However, there were lower complications associated with TARE.

Systemic therapy following arterially directed therapies may be appropriate in patients with adequate liver function once bilirubin returns to baseline, if there is evidence of residual or recurrent tumor not amenable to additional locoregional therapies.[404-406] Results from non-randomized phase II studies and a retrospective analysis suggest that concurrent administration of sorafenib with TACE or DEB-TACE may be a treatment option for patients with unresectable HCC.[403-409,419] A meta-analysis including 14 studies with 1670 patients with advanced HCC examined the efficacy and safety of TACE combined with sorafenib.[420] Results showed that this combination was associated with greater 1-year OS, compared to TACE alone (OR, 1.88; 95% CI, 1.39–2.53; $P < .001$), but combination therapy also resulted in greater frequency of some adverse events (hand-foot skin reaction, diarrhea, hypertension, fatigue, hepatotoxicity, and rash). This meta-analysis is limited by lack of an evaluation of a longer follow-up period. One meta-analysis of 13 studies with 2538 patients found that the combination of TACE with sorafenib improved OS in the Asian regions but not in non-Asian areas,[421] while another did not find a difference in OS in either region but noted a longer time to disease progression in the Asian population but not the European population.[422] In a phase III randomized trial, sorafenib, when given following treatment with TACE, did not significantly prolong TTP or OS in patients with unresectable HCC that responded to TACE.[409] Another phase III trial determined that the combination of sorafenib with DEB-TACE did not improve PFS.[423] Currently, the Panel does not recommend sorafenib following TACE, given the lack of evidence to support this treatment sequence. In the phase III EMERALD-1 trial, patients with unresectable HCC were randomized to receive treatment with TACE and one of the following: durvalumab plus bevacizumab, durvalumab plus placebo, or placebo.[424] The data showed a median PFS of 15.0 months (95% CI, 11.1–18.9 months) for the durvalumab/bevacizumab arm (HR, 0.77; 95% CI, 0.61–0.98; $P = .032$ compared to placebo), 10.0 months (95% CI, 9.0–12.7 months) for the durvalumab/placebo arm (HR, 0.94; 95% CI, 0.75–1.19; $P = .64$ compared to placebo), and 8.2 months (95% CI, 6.9–11.1 months) for the placebo arm. Twenty-seven percent of patients in the first group had a grade 3–4 study treatment-related adverse event, compared to 6% of patients in both the second and third group.

In a phase III randomized trial from China, patients with recurrent intermediate-stage HCC with positive MVI were treated with sorafenib plus TACE or with TACE alone.[425] The results showed that outcomes were improved in the group treated with sorafenib plus TACE in terms of median OS (22.2 months vs. 15.1 months; HR, 0.55; $P < .001$), ORR based on mRECIST (80.2% vs. 58.0%; $P = .002$), and PFS (16.2 months vs. 11.8 months; HR, 0.54; $P < .001$). In the multicenter phase III LAUNCH study in China, patients with advanced HCC were randomized to receive lenvatinib and TACE or lenvatinib alone, either as primary treatment or following initial disease recurrence post surgery.[426] Treatment with lenvatinib and TACE

Version 2.2025 © 2025 National Comprehensive Cancer Network© (NCCN©), All rights reserved. NCCN Guidelines® and this illustration may not be reproduced in any form without the express written permission of NCCN.

PLEASE NOTE that use of this NCCN Content is governed by the End-User License Agreement, and you MAY NOT distribute this Content or use it with any artificial intelligence model or tool.
Printed by Galya Basol Kochav on 1/5/2026 10:54:24 AM. Copyright © 2026 National Comprehensive Cancer Network, Inc. All Rights Reserved.

resulted in a higher ORR, per mRECIST (54.1% vs. 25.0%; $P < .001$), and an improved median OS (17.8 vs. 11.5 months; HR, 0.45; $P < .001$) and PFS (10.6 vs. 6.4 months; HR, 0.43; $P < .001$). A randomized study evaluated the combination of TACE with lenvatinib versus TACE with sorafenib.[427] Treatment with TACE plus lenvatinib resulted in a higher median TTP (4.7 vs. 3.1 months with TACE/sorafenib; HR, 0.55; 95% CI, 0.32–0.95; $P = .029$) and ORR (53.1% vs. 25.0% with TACE/sorafenib; $P = .039$). The results of a multivariable analysis also determined that TACE with lenvatinib led to prolonged TTP compared to TACE with sorafenib (HR, 0.50; 95% CI, 0.28–0.90; $P = 0.021$).

TARE is a method that involves internal delivery of high-dose beta radiation to the tumor-associated capillary bed, thereby sparing the normal liver tissue.[382,428] TARE is accomplished through the catheter-based administration of microspheres (glass or resin microspheres) embedded with Y-90, an emitter of beta radiation. One study reported a 92.8% 3-year OS in patients who received TARE as neoadjuvant therapy prior to liver resection or transplant, compared to 86.6% of all patients, which include those who received TARE as primary therapy.[429]

There is a growing body of literature to suggest that radioembolization might be an effective treatment option for patients with liver-limited, unresectable disease,[430-435] though additional RCTs are needed to determine the RRs and benefits of TARE with Y-90 microspheres in patients with unresectable HCC and long-term impact on liver function.[436] Delivery of ≥205 Gy to the tumor may be associated with increased OS.[437] A dose of >400 Gy to 25% of the liver or less in patients with CTP A liver function is recommended.[438,439] For anatomically limited disease, radiation segmentectomy with Y-90 or ablative dose stereotactic body RT (SBRT) should be considered.[440-442] Although radioembolization with Y-90 microspheres, like TAE and TACE, involves some level of particle-induced vascular occlusion, it has been proposed that such occlusion is more likely to be microvascular than macrovascular, and that the resulting tumor necrosis is more likely to be induced by radiation rather than ischemia.[430] RCTs have shown that Y-90 is not superior to sorafenib for treating advanced HCC.[443,444] Radioembolization may be appropriate in some patients with advanced HCC,[443,444] specifically patients with segmental or lobar portal vein, rather than main PVT.[430]

Reported complications of TARE include cholecystitis/bilirubin toxicity, gastrointestinal ulceration, radiation-induced liver disease, and abscess formation.[430,432,445] A PR rate of 42.2% was observed in a phase II study of 108 patients with unresectable HCC with and without PVT treated with TARE and followed for up to 6 months.[430] Grade 3/4 adverse events were more common in patients with main PVT. However, patients with branch PVT experienced a similar frequency of adverse events related to elevated bilirubin levels as patients without PVT. Results from a single-center, prospective longitudinal cohort study of 291 patients with HCC treated with TARE showed a significant difference in median survival times based on liver function level (17.2 months for patients with CTP Class A disease and 7.7 months for patients with CTP Class B disease; $P = .002$).[432] Median survival for patients with CTP Class B disease and those with PVT was 5.6 months. A meta-analysis including 17 studies with 722 patients with HCC and PVT showed that median TTP, CR rate, PR rate, stable disease (SD) rate, progressive disease rate, and OS were 5.6 months, 3.2%, 16.5%, 31.3%, 28%, and 9.7 months, respectively.[446] Median OS for patients with CTP Class B liver function (6.1 months) was lower than for patients with CTP Class A liver function (12.1 months), and lower for patients with main PVT (6.1 months) than for patients with branch PVT (13.4 months). Toxicities reported in these studies included fatigue (2.9%–67%), abdominal pain (2.9%–57%), and nausea/vomiting (5.7%–28%). Results from this meta-analysis suggest that TARE is safe and effective for patients with HCC who have PVT.

Version 2.2025 © 2025 National Comprehensive Cancer Network© (NCCN©), All rights reserved. NCCN Guidelines® and this illustration may not be reproduced in any form without the express written permission of NCCN.

A multicenter study analyzed radiation segmentectomy, a selective TARE approach that limits radioembolization to two or fewer hepatic segments. This technique was evaluated in 102 patients with solitary unresectable HCC not amenable to RFA treatment due to tumor proximity to critical structures. The procedure resulted in CR, PR, and SD in 47%, 39%, and 12% of patients, respectively.[435] In the multicenter LEGACY study, treatment with TARE, with a median absorbed dose to the treated liver volume of 410 Gy, as a neoadjuvant therapy or primary therapy yielded an ORR (best response) of 88.3% (95% CI, 82.4%–92.4%), as assessed by localized mRECIST, with 62.2% (95% CI, 54.1%–69.8%) of patients achieving a duration of response (DOR) of ≥6 months.[429]

In a meta-analysis including five studies, patients with unresectable HCC (N = 553) treated with TACE or TARE with Y-90 microspheres had similar survival times and response rates.[447] However, TARE resulted in a longer TTP, less toxicity, and less post-treatment pain than TACE. Further, TACE requires a 1-day hospital stay, while TARE is usually an outpatient procedure. A phase II randomized trial also reported similar results, including a significantly longer median TTP in patients treated with TARE (>26 vs. 6.8 months in patients treated with conventional TACE; P = .0012; HR, 0.122; 95% CI, 0.027–0.557; P = .007).[448] Another meta-analysis including 14 studies compared DEB-TACE to TARE with Y-90 microspheres in patients with HCC and found that DEB-TACE had a superior 1-year OS rate (79% vs. 55%, respectively; OR, 0.57; 95% CI, 0.36–0.92; P = .02), though this difference is no longer statistically significant for 2-year and 3-year OS.[449] However, an interim analysis in the intent-to-treat population from the randomized phase II TRACE trial, which compared these two treatment modalities in patients with unresectable HCC, showed that TARE with Y-90 resulted in improved outcomes.[450] The median TTP and OS were 17.1 months and 30.2 months, respectively, in patients treated with TARE with Y-90 compared to 9.5 months (HR, 036; 95% CI, 0.18–0.70; P = .002) and 15.6 months (HR, 0.48; 95% CI, 0.28–0.82; P = .006), respectively, in patients treated with DEB-TACE. Similar results were obtained for TTP in the per-protocol population (HR, 0.29; 95% CI, 0.14–0.60; P < .001). These findings need to be confirmed in large RCTs.

Two phase III RCTs compared the efficacy and safety of TARE with Y-90 microspheres to sorafenib in patients with locally advanced HCC.[443,444] In both trials, OS rates were not significantly different between the two treatment groups. However, adverse events grade 3 or higher (eg, diarrhea, fatigue, hand-foot skin reaction) were more frequent in patients randomized to receive sorafenib than in patients randomized to receive TARE.

Radiation Therapy

RT options for patients with liver-confined, unresectable HCC deemed ineligible for transplant include SBRT. RT allows focal administration of high-dose radiation to liver tumors while sparing surrounding liver tissue, thereby limiting the risk of radiation-induced liver damage in patients with unresectable HCC.[451,452] Advances in RT, such as intensity-modulated RT (IMRT) and image–guided radiotherapy, have allowed for enhanced delivery of higher radiation doses to the tumor while sparing surrounding critical tissue. SBRT is an advanced technique of RT that delivers large ablative doses of radiation. There is growing evidence (primarily from non-RCTs) supporting the usefulness of SBRT for unresectable, locally advanced, or recurrent HCC.[453-457]

In a phase II trial of 50 patients with inoperable HCC treated with SBRT after incomplete TACE, SBRT induced CRs and PRs in 38.3% of patients within 6 months of completing SBRT.[456] The 2-year local control rate, OS, and PFS rates were 94.6%, 68.7%, and 33.8%, respectively. In another study that evaluated the long-term efficacy of SBRT for patients with primarily small HCC ineligible for local therapy or surgery (42 patients), SBRT induced an overall CR rate of 33%, with 1- and 3-year OS rates of

Version 2.2025 © 2025 National Comprehensive Cancer Network© (NCCN©), All rights reserved. NCCN Guidelines® and this illustration may not be reproduced in any form without the express written permission of NCCN.

PLEASE NOTE that use of this NCCN Content is governed by the End-User License Agreement, and you MAY NOT distribute this Content or use it with any artificial intelligence model or tool.
Printed by Galya Basol Kochav on 1/5/2026 10:54:24 AM. Copyright © 2026 National Comprehensive Cancer Network, Inc. All Rights Reserved.

92.9% and 58.6%, respectively.[453] In patients with recurrent HCC treated with SBRT, tumor size, recurrent stage, and CTP were identified as independent prognostic factors for OS in multivariate analysis.[455] In a report from Princess Margaret Cancer Centre on 102 patients treated with SBRT for locally advanced HCC in sequential phase I and phase II trials, Bujold et al reported a 1-year local control rate of 87% and a median survival of 17 months. The majority of these patients were at high risk with relatively advanced-stage tumors (55% of patients had tumor vascular thrombosis, and 61% of patients had multiple lesions with a median sum of largest diameter of almost 10 cm and a median diameter of 7.2 cm for the largest lesion).[457] A retrospective analysis comparing RFA and SBRT in 224 patients with inoperable, nonmetastatic HCC showed that SBRT may be a preferred option for tumors ≥2 cm.[458] However, another retrospective analysis from the National Cancer Database including 3980 patients with stage I or II HCC showed that 5-year OS was greater for patients who received RFA, compared to patients who received SBRT (30% vs. 19%, $P < .001$).[459] SBRT has also been shown to be an effective bridging therapy for patients with HCC and cirrhosis awaiting liver transplant.[460-462]

Most tumors, irrespective of their location, may be amenable to 3D-CRT, IMRT, or SBRT. RT dosing,[463] including SBRT, hypofractionation, and conventional fractionation dosing, is dependent on the ability to meet normal organ constraints and underlying liver function. SBRT or hypofractionation are preferred RT options. For SBRT, doses ranging between 40 to 60 Gy (in 3–5 fractions; biologically effective dose [BED] 10 >100) is preferred if dose constraints can be met.[463] The dose for hypofractionation is 37.5 to 72 Gy in 10 to 15 fractions and the dose for conventional fractionation is 50 to 66 Gy in 25 to 33 fractions.[464-466] SBRT is often used for patients with one to three tumors with minimal or uncertain extrahepatic disease. There is no strict size limit, so SBRT may be used for larger lesions if there is sufficient uninvolved liver and liver radiation dose constraints can be respected. The majority of safety and efficacy data on the use of SBRT are available for patients with HCC and CTP A liver function; limited safety data are available for the use of SBRT in patients with CTP B or poorer liver function.[454,457,467-469] Those with CTP B cirrhosis may require dose modifications and strict dose constraint adherence to increase safety in this population. The safety of SBRT for patients with CTP C cirrhosis has not been established, as there are not likely to be clinical trials available for this group of patients with a very poor prognosis. Hypofractionation with photons[464] or protons[464,470] is an acceptable option for intrahepatic tumors, although treatment at centers of experience is recommended. A multi-institutional trial reported a local control rate of 91.2% and an OS rate of 65.6% at 1 year for patients with HCC treated with hypofractionated proton beam therapy (PBT).[471]

ASTRO (American Society for Radiation Oncology) has released a model policy supporting the use of PBT in some oncology populations. [472] In a phase II study, 94.8% of patients with unresectable HCC who received high-dose hypofractionated PBT demonstrated >80% local control after 2 years, as defined by RECIST criteria.[464] In a meta-analysis including 70 studies, charged particle therapy (mostly including PBT) was compared to SBRT and conventional radiotherapy.[473] OS (RR, 25.9; 95% CI, 1.64–408.5; $P = .02$), PFS (RR, 1.86; 95% CI, 1.08–3.22; $P = .013$), and locoregional control (RR, 4.30; 95% CI, 2.09–8.84; $P < .001$) through 5 years were greater for charged particle therapy than for conventional radiotherapy. There were no significant differences between charged particle therapy and SBRT for these outcomes. In a comparison of PBT and IMRT, PBT was linked with higher OS (31 vs. 14 months), which could be due to decreased occurrence of liver decompensation.[474] Analyses from a prospective RCT showed that PBT was associated with improved local control ($P = .003$), better median PFS ($P = .002$), and fewer hospitalization days following treatment ($P < .001$), relative to patients with HCC who received TACE.[470] However, both groups had a 2-year OS rate of 68%. The Panel advises that PBT may be considered and

Version 2.2025 © 2025 National Comprehensive Cancer Network© (NCCN©), All rights reserved. NCCN Guidelines® and this illustration may not be reproduced in any form without the express written permission of NCCN.

appropriate in select settings for treating HCC. Several ongoing studies are continuing to investigate the impact of hypofractionated PBT on HCC outcomes,[475] including randomized trials comparing PBT to RFA (NCT02640924). Hypofractionated PBT was evaluated in a phase II study with 45 patients with HCC.[476] At 3 years, the local PFS and OS were 95.2% (95% CI, 89.1%–100%) and 86.4% (95% CI, 72.9%–99.9%), respectively. A phase III non-inferiority randomized trial comparing PBT to RFA in patients with recurrent or residual HCC determined a local PFS rate of 92.8% and 83.2% ($P < .001$) with PBT (n = 72) versus RFA (n = 72), respectively, in the intent-to-treat population at 2 years.[477] Similar results were obtained in the per-protocol population: the local PFS rates were 94.8% and 83.9% ($P < .001$) in the PBT arm (n = 80) versus the RFA arm (n = 56), respectively.

In a phase III trial, patients with locally advanced HCC were randomized to receive sorafenib or SBRT followed by sorafenib.[478] Patients treated with sorafenib had a median OS of 12.3 months (90% CI, 10.6–14.3 months) compared to 15.8 months (90% CI, 11.4–19.2 months) for those treated with SBRT followed by sorafenib (HR, 0.77; 90% CI, 0.59–1.01; $P = .06$). After taking the stratification factors (performance status, liver function, degree of metastases, and macrovascular invasion) into account, the OS was higher with SBRT followed by sorafenib (HR, 0.72; 95% CI, 0.52–0.99). These patients also had improved median PFS (9.2 months vs. 5.5 months with sorafenib; HR, 0.55; 95% CI, 0.40–0.75; $P < .001$). The authors concluded that SBRT followed by sorafenib was associated with higher OS that was clinically important but without statistical significance.

Combinations of Locoregional Therapies

Results from retrospective analyses suggest that the combination of TACE with RFA is more effective (both in terms of tumor response and OS) than TACE or RFA alone or resection in patients with single or multiple tumors fulfilling the UNOS or Milan criteria[237,479] or in patients with single tumors up to 7 cm.[480,481] The principle behind the combination of RFA and embolization is that the focused heat delivery of RFA may be enhanced by vessel occlusion through embolization since blood circulation inside the tumor may interfere with the transfer of heat to the tumor.

However, randomized trials that have compared the combination of ablation and embolization with ablation or embolization alone have shown conflicting results. Combination therapy with TACE and PEI resulted in superior survival compared to TACE or PEI alone in the treatment of patients with small HCC tumors, especially for patients with HCC tumors measuring <2 cm.[482,483] In another randomized study, Peng et al reported that the combination of TACE and RFA was superior to RFA alone in terms of OS and RFS for patients with tumors <7 cm, although this study had several limitations (small sample size and the study did not include TACE alone as one of the treatment arms, thus making it difficult to assess the relative effectiveness of TACE alone compared to the combination of TACE and RFA).[484] In a prospective randomized study, Shibata et al reported that the combination of RFA and TACE was equally as effective as RFA alone for the treatment of patients with small (≤3 cm) tumors.[485] Conversely, results from other randomized trials indicate that the survival benefit associated with the combination approach is limited only to patients with tumors that are between 3 cm and 5 cm.[486,487] In the randomized prospective trial that evaluated sequential TACE and RFA versus RFA alone in 139 patients with recurrent HCC ≤5 cm, the sequential TACE and RFA approach was better than RFA in terms of OS and RFS only for patients with tumors between 3.1 and 5.0 cm ($P = .002$ and $P < .001$) but not for those with tumors ≤3 cm ($P = .478$ and $P = .204$).[487]

In a small RCT including 50 patients with an unresectable single HCC lesion (ie, >4 cm, serum bilirubin >1.2 mg/dL, and/or presence of esophageal varices), patients received either TACE alone, TACE following RFA, or TACE following MWA.[488] Patients who received TACE alone had a

Version 2.2025 © 2025 National Comprehensive Cancer Network© (NCCN©), All rights reserved. NCCN Guidelines® and this illustration may not be reproduced in any form without the express written permission of NCCN.

PLEASE NOTE that use of this NCCN Content is governed by the End-User License Agreement, and you MAY NOT distribute this Content or use it with any artificial intelligence model or tool.
Printed by Galya Basol Kochav on 1/5/2026 10:54:24 AM. Copyright © 2026 National Comprehensive Cancer Network, Inc. All Rights Reserved.

greater recurrence rate 1 month after intervention completion, compared to patients who received TACE with RFA or MWA (30% vs. 5% vs. 0%, respectively; *P* = .027). However, at 3- and 6-month follow-up, recurrence rates between the three groups were no longer statistically significant. A randomized trial with 265 patients with HCC >3 cm and <5 cm demonstrated that patients treated with the combination of conventional TACE and MWA had improved outcomes compared to those treated with TACE or MWA in terms of CR (combined therapy, 86.5%; TACE, 54.8%; MWA, 56.5%; *P* = .0002), recurrence rate at 12 months (combined therapy, 22.5%; TACE, 60.7%; MWA, 51.1%; *P* = .0001), OS at 3 years post therapy (combined therapy, 69.6%; TACE, 54.7%; MWA, 54.3%; *P* = .02), and mean PFS (*P* < .001).[489]

The results of a meta-analysis of 10 RCTs comparing the outcomes of TACE plus percutaneous ablation with those of TACE or ablation alone suggest that while there is a significant OS benefit for the combination of TACE and PEI compared to TACE alone for patients with large HCC tumors, there was no survival benefit for the combination of TACE and RFA in the treatment of small lesions as compared with that of RFA alone.[490]

Therefore, available evidence suggests that the combination of TACE with RFA or PEI may be effective, especially for patients with larger lesions that do not respond to either procedure alone. A meta-analysis including 25 studies with 2577 patients with unresectable HCC showed that TACE combined with RT (eg, 3D conformal RT, SBRT) was associated with a complete tumor response (OR, 2.73; 95% CI, 1.95–3.81) and survival through 5 years (OR, 3.98; 95% CI, 1.89–8.50), compared with TACE delivered alone.[491] However, this combination was also associated with increased gastroduodenal ulcers (OR, 12.80; 95% CI, 1.57–104.33), levels of ALT (OR, 2.46; 95% CI, 1.30–4.65), and total bilirubin (OR, 2.16; 95% CI, 1.05–4.45).

A Cochrane review including nine RCTs with 879 patients with unresectable HCC showed that EBRT combined with TACE is associated with lower 1-year mortality (RR, 0.51; 95% CI, 0.41–0.62; *P* < .001) and a better response rate (CR or PR; RR, 1.58; 95% CI, 1.40–1.78; *P* < .001), compared to TACE alone.[492] However, patients who received the combination treatment had increased toxicity compared to patients who received TACE alone, as illustrated by elevated alanine aminotransferase (RR, 1.41; 95% CI, 1.08–1.84; *P* = .01) and bilirubin (RR, 2.69; 95% CI, 1.34–5.40; *P* = .005). The investigators who conducted the review cautioned that the quality of evidence for these findings was low to very low. In an RCT, 90 patients with HCC confined to the liver and with macroscopic vascular invasion were randomized to receive first-line sorafenib or TACE combined with EBRT.[493] The TACE/EBRT arm had better median OS (55 vs. 43 weeks, respectively; *P* = .04), 12-week PFS (86.7% vs. 34.3%, respectively; *P* < .001), radiologic response (33.3% vs. 2.2%, respectively; *P* < .001), and median TTP (31 vs. 12 weeks, respectively; *P* < .001) compared to the sorafenib arm.

NCCN Recommendations for Locoregional Therapies

The consensus of the Panel is that liver resection or transplantation is preferred for patients who meet resection with or without transplant selection criteria since these are established potentially curative therapies. Locoregional therapy (ie, ablation, arterially directed therapies, RT) is a treatment approach for patients who are not amenable to surgery or liver transplantation. Ablation is the preferred locoregional therapy approach.

All tumors considered for ablation should be amenable to complete treatment with a margin of normal tissue around the tumor. Tumors should be in a location accessible for percutaneous, laparoscopic, or open approaches. Lesions abutting key structures such as the bile ducts, stomach, bowel, gallbladder, or diaphragm may be difficult locations for ablation, although hydrodissection techniques can be used to safely treat in

Version 2.2025 © 2025 National Comprehensive Cancer Network© (NCCN©), All rights reserved. NCCN Guidelines® and this illustration may not be reproduced in any form without the express written permission of NCCN.

some instances. The Panel emphasizes that caution should be exercised when ablating lesions near these structures to decrease complications. Similarly, ablative treatment of tumors located on the liver capsule may cause tumor rupture with track seeding, especially with direct puncture techniques. Tumor seeding along the needle track has been reported in <1% of patients with HCC treated with RFA.[494-496] Lesions with subcapsular location and poor differentiation seem to be at higher risk for this complication.[494] During an ablation procedure, major vessels in close proximity to the tumor can absorb large amounts of heat (known as the "heat sink effect"), which can decrease the effectiveness and significantly increase local recurrence rates.

The consensus of the Panel is that ablation alone may be a curative treatment for tumors ≤3 cm. In well-selected patients with small, properly located tumors ablation should be considered as definitive treatment in the context of a multidisciplinary review.[351,353] Tumors between 3 and 5 cm may be treated with a combination of MWA and/or arterially directed therapies to prolong survival, as long as the tumor location is favorable to ablation and underlying liver function is adequate.[486,487,497] The Panel recommends that patients with unresectable or inoperable lesions >5 cm should be considered for treatment using arterially directed therapies, RT, or systemic therapy.

All HCC tumors, irrespective of location in the liver, may be amenable to arterially directed therapies, provided that the arterial blood supply to the tumor can be isolated.[385,389,430,480] An evaluation of the arterial anatomy of the liver, patient's performance status, and liver function is necessary prior to the initiation of arterially directed therapy. In addition, more individualized patient selection that is specific to the particular arterially directed therapy being considered is necessary to avoid significant treatment-related toxicity. General patient selection criteria for arterially directed therapies include unresectable or inoperable tumors not amenable to ablation therapy only, and the absence of large-volume extrahepatic disease. Minimal extrahepatic disease is considered a "relative" contraindication for arterially directed therapies.

All arterially directed therapies are relatively contraindicated in patients with bilirubin >3 mg/dL unless segmental treatment can be performed. Outside of segmental therapy, TARE with Y-90 microspheres has an increased risk of radiation-induced liver disease in patients with bilirubin >2 mg/dL.[432] Arterially directed therapies in highly selected patients have been shown to be safe to use in patients with limited tumor invasion of the portal vein. It is also important to note that the contrast agent used may be nephrotoxic, and, thus, these therapies should not be used if creatinine clearance is elevated.

The Panel recommends that SBRT be considered as an alternative to ablation and/or embolization techniques or when these therapies have failed or are contraindicated (in patients with unresectable disease characterized as extensive or otherwise not suitable for liver transplantation and those with local disease but who are not considered candidates for surgery due to performance status or comorbidity).[478] Radiotherapy should be guided by imaging to improve treatment accuracy and reduce toxicity. Palliative RT is appropriate for symptom control and/or prevention of complications from metastatic HCC lesions, such as bone or brain, and extensive liver tumor burden.[498] The Panel encourages prospective clinical trials evaluating the role of SBRT in patients with unresectable, locally advanced, or recurrent HCC.

Systemic Therapy

The majority of patients diagnosed with HCC have advanced disease, and only a small percentage are eligible for potentially curative therapies. Furthermore, with the wide range of locoregional therapies available to treat patients with unresectable HCC confined to the liver, systemic therapy

Version 2.2025 © 2025 National Comprehensive Cancer Network© (NCCN©), All rights reserved. NCCN Guidelines® and this illustration may not be reproduced in any form without the express written permission of NCCN.

has often been a treatment of last resort for those patients with very advanced disease. An FDA-approved biosimilar is an appropriate substitute for any recommended systemic biologic therapy in the NCCN Guidelines.

First-Line Systemic Therapy

Atezolizumab and Bevacizumab

Bevacizumab, a VEGF inhibitor, has modest clinical activity as a single agent or in combination with erlotinib or chemotherapy in phase II studies in patients with advanced HCC.[499-503] The IMbrave150 phase III trial enrolled 501 patients with unresectable HCC and CTP A liver function, with randomization to either the combination of atezolizumab and bevacizumab or sorafenib as first-line treatment. All patients were required to have an upper endoscopy within 6 months prior to enrollment due to risk of upper gastrointestinal bleeding observed in prior phase 2 studies of bevacizumab in HCC.[500,504] The IMbrave150 study showed that the combination of atezolizumab plus bevacizumab significantly improved outcomes compared to sorafenib.[505] Analyses from an independent reviewer (using HCC RECIST criteria) comparing the atezolizumab and bevacizumab combination to sorafenib showed an ORR of 27.3% versus 11.9% (5.5% vs. 0% CR, 21.8% vs. 11.9% PR), with SD in 46.3% versus 43.4% of patients and progressive disease in 19.6% versus 24.5%. DOR >6 months was estimated to be 87.6% in the atezolizumab and bevacizumab arm and 59.1% in the sorafenib arm. Updated data revealed a median OS and PFS of 19.2 months (95% CI, 17.0–23.7 months) and 6.9 months (95% CI, 5.7–8.6 months), respectively, for patients in the atezolizumab and bevacizumab group versus 13.4 months (95% CI, 11.4–16.9 months) and 4.3 months (95% CI, 4.0–5.6 months), respectively, for patients in the sorafenib group (HR for OS, 0.66; 95% CI, 0.52–0.85; descriptive $P < .001$; HR for PFS, 0.65; 95% CI, 0.53–0.81; descriptive $P < .001$).[506] Grade 3/4 treatment-related adverse events were reported in 43% of evaluable patients receiving the combination treatment versus 46% in patients receiving sorafenib. Prior to the initiation of the atezolizumab plus bevacizumab regimen, patients should have adequate endoscopic evaluation and management for esophageal varices within approximately 6 months prior to treatment or according to institutional practice and based on the assessment of bleeding risk.

Preliminary findings from a real-world study revealed a median OS of 16.8 months (95% CI, 14.1–23.9 months), a median PFS of 7.6 months (95% CI, 6.2–8.9 months), a median TTP of 7.6 months (95% CI, 6.4–8.8 months), and an ORR of 26% in patients with CTP A HCC compared to a median OS of 6.7 months (95% CI, 4.3–15.6 months; $P = .0003$), a median PFS of 3.4 months (95% CI, 2.6–4.2 months; $P = .03$), a median TTP of 4.6 months (95% CI, 0.8–8.4 months; $P = .28$), and an ORR of 21% ($P > .05$) in patients with CTP B HCC.[507] Treatment-related adverse events were comparable in both groups.

A case series compared first-line immunotherapy with atezolizumab plus bevacizumab (N = 141) or with nivolumab (N = 46) to best supportive care (N = 158) in patients with unresectable CTP Class B HCC.[508] In the inverse probability of treatment weighting population, treatment with immunotherapy resulted in an improved median OS of 7.5 months (95% CI, 5.62–11.15 months) compared to 4.04 months with best supportive care (95% CI, 3.03–5.03 months; HR, 0.59; 95% CI, 0.43–0.80 months; $P < .001$). Treatment with atezolizumab plus bevacizumab yielded a median OS of 7.43 months (95% CI, 5.62–12.57 months; HR, 0.60; 95% CI, 0.42–0.87; $P = .005$; when compared to best supportive care). Treatment with nivolumab yielded a median OS of 7.50 months (95% CI, 4.14–14.34 months; HR, 0.54; 95% CI, 0.36–0.81; $P = .004$; when compared to best supportive care). Multivariable analysis also showed that the risk of death was also significantly lower in the immunotherapy arm (HR, 0.55; 95% CI, 0.35–0.86; $P < .001$).

Atezolizumab and hyaluronidase-tqjs subcutaneous injection may be substituted for IV atezolizumab. Atezolizumab and hyaluronidase-tqjs has

Version 2.2025 © 2025 National Comprehensive Cancer Network© (NCCN©), All rights reserved. NCCN Guidelines® and this illustration may not be reproduced in any form without the express written permission of NCCN.

PLEASE NOTE that use of this NCCN Content is governed by the End-User License Agreement, and you MAY NOT distribute this Content or use it with any artificial intelligence model or tool.
Printed by Galya Basol Kochav on 1/5/2026 10:54:24 AM. Copyright © 2026 National Comprehensive Cancer Network, Inc. All Rights Reserved.

different dosing and administration instructions compared to atezolizumab for intravenous infusion.

Tremelimumab-actl and Durvalumab

The phase III HIMALAYA study randomized 1171 patients with unresectable HCC with no prior systemic treatment to receive tremelimumab, an anti-CTLA-4 antibody, in combination with durvalumab, an anti-PD-1 antibody, durvalumab monotherapy, or sorafenib.[156] The median OS was 16.4 months (95% CI, 14.2–19.6 months), 16.6 months (95% CI, 14.1–19.1 months), and 13.8 months (95% CI, 12.3–16.1 months), respectively. Compared to sorafenib, the combination treatment significantly ameliorated OS (HR, 0.78; 96% CI, 0.65–0.93; $P = .0035$). There was no significant difference in PFS. At 5 years, the HR for OS was 0.76 (95% CI, 0.65–0.89), with an OS and DCR (per RECIST version 1.1) rate of 19.6% and 28.7%, respectively, for tremelimumab-actl and durvalumab and 9.4% and 12.7%, respectively, for sorafenib.[509] Serious treatment-related adverse events were reported in 17.5% and 9.9% of patients treated with the combination treatment and sorafenib, respectively.

Durvalumab

In the phase III HIMALAYA study, patients with unresectable HCC with no prior systemic treatment were randomized to receive tremelimumab in combination with durvalumab, durvalumab monotherapy, or sorafenib.[156] The median OS was 16.4 months (95% CI, 14.2–19.6 months), 16.6 months (95% CI, 14.1–19.1 months), and 13.8 months (95% CI, 12.3–16.1 months), respectively. The results showed that durvalumab monotherapy was noninferior to sorafenib (HR, 0.86; 95% CI, 0.73–1.03). There was no significant difference in PFS among the three groups. Treatment-emergent adverse events that were grade 3 or 4 were reported in 50.5%, 37.1%, and 52.4% of patients treated with the combination treatment, durvalumab monotherapy, and sorafenib, respectively. At 5 years, the HR for OS was 0.85 (95% CI, 0.73–1.00), with an OS rate of 14.4% for durvalumab and 9.4% for sorafenib.[509] Serious treatment-related adverse events occurred in 8.5% and 9.9% of patients treated with durvalumab and sorafenib, respectively.

Lenvatinib

Lenvatinib is an inhibitor of VEGFR, fibroblast growth factor receptor, platelet-derived growth factor receptor (PDGFR), and other growth signaling kinases. In the phase III randomized REFLECT trial, patients with unresectable HCC ($N = 954$) were randomized to receive either lenvatinib or sorafenib as first-line treatment.[510] The trial was designed to demonstrate non-inferiority or superiority of lenvatinib; the prespecified boundary for non-inferiority was met with median OS of 13.6 months in the lenvatinib arm compared to 12.3 months for sorafenib (HR, 0.92; 95% CI, 0.79–1.06). Based on results of the REFLECT trial, the FDA approved lenvatinib in 2018 as first-line treatment for patients with unresectable HCC.

Sorafenib

Sorafenib, an oral multikinase inhibitor that suppresses tumor cell proliferation and angiogenesis, was evaluated in two randomized, placebo-controlled, phase III trials for the treatment of patients with advanced or metastatic HCC.[511,512]

In one of these phase III trials (SHARP trial), 602 patients with advanced HCC were randomly assigned to sorafenib or best supportive care. In this study, advanced HCC was defined as patients not eligible for or those who had disease progression after surgical or locoregional therapies.[511] The majority of the patients had preserved liver function (≥95% of patients classified as CTP Class A) and good performance status (>90% of patients had ECOG performance status of 0 or 1). Median OS was significantly longer in the sorafenib arm (10.7 months in the sorafenib arm vs. 7.9 months in the placebo group; HR, 0.69; 95% CI, 0.55–0.87; $P < .001$).[511] In the Asia-Pacific study, another phase III trial with a similar design to the

Version 2.2025 © 2025 National Comprehensive Cancer Network© (NCCN©), All rights reserved. NCCN Guidelines® and this illustration may not be reproduced in any form without the express written permission of NCCN.

PLEASE NOTE that use of this NCCN Content is governed by the End-User License Agreement, and you MAY NOT distribute this Content or use it with any artificial intelligence model or tool.
Printed by Galya Basol Kochav on 1/5/2026 10:54:24 AM. Copyright © 2026 National Comprehensive Cancer Network, Inc. All Rights Reserved.

SHARP study, 226 patients were randomly assigned to sorafenib or placebo arms (150 and 76 in sorafenib and placebo arms, respectively).[512] While the HR for the sorafenib arm compared with the placebo arm (HR, 0.68; CI, 0.50–0.93; *P* = .014) was nearly identical to that reported for the SHARP study, the median OS was strikingly lower in both treatment and placebo groups in the Asia-Pacific study (6.5 vs. 4.2 months).

Data on the efficacy of sorafenib in patients with CTP Class B liver function are limited since only patients with preserved liver function (CTP Class A) were to be included in those trials.[513,514] However, approximately 28% of the 137 patients enrolled in a phase 2 trial evaluating sorafenib in the treatment of HCC had CTP Class B liver function.[515] A subgroup analysis of these patients demonstrated a median OS for patients in the CTP Class B group of only 3.2 months compared to 9.5 months for those in the CTP Class A group.[516] Other investigators have also reported lower median OS for patients with CTP Class B liver function.[517-521] In the GIDEON registry, the safety profile of sorafenib was generally similar for CTP Class A and CTP Class B.[522] In the final analysis of the trial, in the intent-to-treat population (3213 patients), the median OS was 13.6 months for the CTP Class A group compared to 5.2 months for the CTP Class B group. These unsurprising results reflect the balance between cancer progression and worsening liver disease as competing causes of death for patients with unresectable HCC and forms the basis for the exclusion of patients with poorer liver function from these and other clinical trials.

In addition to clinical outcome, impaired liver function may impact the dosing and toxicity of sorafenib. Abou-Alfa et al found higher levels of hyperbilirubinemia, encephalopathy, and ascites in the group with CTP Class B liver function, although it is difficult to separate the extent to which treatment drug and underlying liver function contributed to these disease manifestations.[516] A pharmacokinetic and phase I study of sorafenib in patients with hepatic and renal dysfunction showed an association between elevated bilirubin levels and possible hepatic toxicity.[523] Finally, it is important to mention that sorafenib induces only rare objective volumetric tumor responses, and this has led to a search for other validated criteria to evaluate tumor response (such as RECIST[332,333] or EASL criteria[205]).[513]

Sorafenib combined with erlotinib for patients with advanced HCC was assessed in a phase III RCT (*N* = 720).[524] Results showed that this combination did not significantly improve survival, relative to sorafenib delivered with a placebo. Further, disease control rate was significantly lower for patients who received the sorafenib/erlotinib combination, relative to those in the comparison group (*P* = .021). Treatment duration was shorter for those receiving the sorafenib/erlotinib combination (86 vs. 123 days).

Tislelizumab-jsgr

The phase III RATIONALE-301 study investigated the efficacy of tislelizumab, an anti-PD-1 monoclonal antibody, in patients with unresectable HCC who did not receive prior systemic therapy or who were not eligible for or with disease progression after locoregional therapy.[525] The results demonstrated that tislelizumab was noninferior to sorafenib in terms of the primary endpoint of OS. 14.3% of patients in the tislelizumab arm achieved an objective response, compared to 5.4% of patients in the sorafenib arm. Treatment with tislelizumab resulted in a median OS of 15.9 months (95% CI, 13.2–19.7 months), median PFS of 2.1 months (95% CI, 2.1–3.5 months), median DOR of 36.1 months (95% CI, 16.8 months–not evaluable), and incidence rate of 22.2% for treatment-related adverse events that were grade 3 and higher, compared to a median OS of 14.1 months (95% CI, 12.6–17.4 months; HR, 0.85; 95% CI, 0.71–1.02), median PFS of 3.4 months (95% CI, 2.2–4.1 months; HR, 1.11; 95% CI, 0.92–1.33), median DOR of 11.0 months (95% CI, 6.2–14.7 months), and treatment-related adverse events rate of 53.4% in patients in the sorafenib arm.

Version 2.2025 © 2025 National Comprehensive Cancer Network© (NCCN©), All rights reserved. NCCN Guidelines® and this illustration may not be reproduced in any form without the express written permission of NCCN.

PLEASE NOTE that use of this NCCN Content is governed by the End-User License Agreement, and you MAY NOT distribute this Content or use it with any artificial intelligence model or tool.
Printed by Galya Basol Kochav on 1/5/2026 10:54:24 AM. Copyright © 2026 National Comprehensive Cancer Network, Inc. All Rights Reserved.

Nivolumab Plus Ipilimumab

The phase III CheckMate 9DW trial randomized patients with unresectable HCC to receive either nivolumab plus ipilimumab or to receive sorafenib or lenvatinib as a first-line treatment.[526] Patients treated with nivolumab plus ipilimumab had higher median OS (23.7 months; 95% CI, 18.8–29.4 months vs. 20.6 months; 95% CI, 17.5–22.5 months; HR, 0.79; 95% CI, 0.65–0.96; $P = .018$) and higher median DOR (30.4 months; 95% CI, 21.2 months–not estimable vs. 12.9 months; 95% CI, 10.2–31.2 months) compared to those treated with sorafenib or lenvatinib. Thirty-six percent (95% CI, 31%–42%) of patients in the nivolumab plus ipilimumab arm achieved a confirmed overall response compared to 13% (95% CI, 10%–17%) of patients in the sorafenib or lenvatinib arm ($P < .0001$). The proportion of patients who experienced a grade 3–4 treatment-related adverse events was similar in both groups (41% in the former group and 42% in the latter group). Nivolumab and hyaluronidase-nvhy is not approved for concurrent use with IV ipilimumab; however, for nivolumab monotherapy, nivolumab and hyaluronidase-nvhy subcutaneous injection may be substituted for IV nivolumab. Nivolumab and hyaluronidase-nvhy has different dosing and administration instructions compared to IV nivolumab.

Pembrolizumab

Pembrolizumab, an anti-PD-1-antibody, was evaluated in the KEYNOTE-224 phase II clinical trial in 51 patients with previously untreated HCC and demonstrated durable responses.[527] A median ORR of 16% (95% CI, 7%–29%) was reported. The median DOR, disease control rate, PFS, TTP, and OS were 16 months (range, 3 to 24+ months), 57% (95% CI, 42%–71%), 4 months (95% CI, 2–8 months), 4 months (95% CI, 3–9 months), and 17 months (95% CI, 8–23 months), respectively. Sixteen percent of patients had a grade 3 or higher treatment-related adverse event.

Subsequent-Line Therapy if Disease Progression

Recent advancements have produced some effective systemic therapy options for patients with HCC who have disease progression. However, there are no comparative data to define optimal treatment after first-line systemic therapy.

Cabozantinib

Cabozantinib, another oral multikinase inhibitor with potent activity against VEGFR1-3 and MET among other targets, was assessed in the phase III randomized CELESTIAL trial including 707 patients with advanced HCC who have progressed on or after sorafenib, with 7.6% of the sample having received more than one line of previous treatment.[528] Median OS and PFS were significantly greater in patients randomized to receive cabozantinib (10.2 and 5.2 months, respectively), compared to patients randomized to receive a placebo (8.0 and 1.9 months, respectively) (HR, 0.76; 95% CI, 0.63–0.92; $P = .005$ for OS; HR, 0.44; 95% CI, 0.36–0.52; $P < .001$ for PFS), as was the ORR (4% vs. 0.4%; $P = .009$). A subsequent analysis showed that the benefits of cabozantinib spanned across a range of AFP levels.[529] The on-treatment AFP response was higher in the cabozantinib arm, which was linked to longer OS and PFS. These outcomes were also shown to be improved in patients with ALBI grade 1 (OS HR, 0.63; 95% CI, 0.46–0.86; PFS HR, 0.42; 95% CI, 0.32–0.56) and ALBI grade 2 (OS HR, 0.84; 95% CI, 0.66–1.06; PFS HR, 0.46; 95% CI, 0.37–0.58).[530] Patients with ALBI grade 2 disease had more frequent grade 3/4 adverse events associated with liver decompensation. Cabozantinib was approved by the FDA in 2019 for patients with CTP A liver function who have disease progression on or after sorafenib.

Regorafenib

The first drug to get approved for HCC after sorafenib was regorafenib, an oral multikinase inhibitor with activity against VEGFR1-3, PDGFRB, KIT, RET, RAF-1, and other growth signaling kinases. The

Version 2.2025 © 2025 National Comprehensive Cancer Network© (NCCN©), All rights reserved. NCCN Guidelines® and this illustration may not be reproduced in any form without the express written permission of NCCN.

PLEASE NOTE that use of this NCCN Content is governed by the End-User License Agreement, and you MAY NOT distribute this Content or use it with any artificial intelligence model or tool.
Printed by Galya Basol Kochav on 1/5/2026 10:54:24 AM. Copyright © 2026 National Comprehensive Cancer Network, Inc. All Rights Reserved.

randomized, double-blind, placebo-controlled, international phase III RESORCE trial assessed the efficacy and safety of regorafenib in 573 patients with HCC and CTP A liver function who progressed on sorafenib and who tolerated sorafenib at a dose of 400 mg per day for at least 20 of the prior 28 days of treatment.[162] Compared to the placebo, regorafenib improved median OS (10.6 vs. 7.8 months, respectively; HR, 0.63; 95% CI, 0.50–0.79; $P < .001$), median PFS by mRECIST (3.1 vs. 1.5 months; HR, 0.46; 95% CI, 0.37–0.56; $P < .001$), TTP by mRECIST (3.2 vs. 1.5 months; HR, 0.44; 95% CI, 0.36–0.55; $P < .001$), objective response (11% vs. 4%; $P = .005$), and disease control (65% vs. 36%; $P < .001$). Adverse events were universal among patients randomized to receive regorafenib ($n = 374$), with the most frequent grade 3 or 4 treatment-related events being hypertension (15%), hand-foot skin reaction (13%), fatigue (9%), and diarrhea (3%). Seven deaths that occurred were considered by the investigators to have been related to treatment with regorafenib. Based on the results of this trial, the FDA approved regorafenib in 2017 for patients with HCC who progressed on or after sorafenib.

Nivolumab Plus Ipilimumab

Combination treatment with nivolumab and the CTLA-4 antibody ipilimumab in 148 patients with advanced HCC who were previously treated with sorafenib led to improved clinical responses.[160] The results showed a response rate of 32% (95% CI, 20%–47%), per RECIST version 1.1 as assessed by blinded independent central review, and a median OS of 22.8 months (95% CI, 9.4 months–not reached) in patients treated with 1 mg/kg nivolumab plus 3 mg/kg ipilimumab given every 3 weeks (4 doses) followed by 240 mg nivolumab every 2 weeks (arm A). The 5-year results demonstrated that durable responses (median DOR 51.2 months; 95% CI, 12.6 months– not estimable) were achieved and the median OS was maintained at 22.2 months (95% CI, 9.4–54.8 months) in arm A.[531] Thirty-four percent of patients achieved an overall response. Serious grade 3/4 treatment-related adverse events were reported in 20% of patients. With an ORR of 22% by RECIST 1.1, nivolumab plus ipilimumab also demonstrated efficacy in a retrospective study of 32 patients with advanced HCC previously treated with anti-programmed cell death protein 1 (PD-1)/ programmed death ligand 1 (PD-L1) therapy, excluding anti-CTLA-4 therapy.[532] The median OS and PFS were 9.2 months (95% CI, 5.9 months–not reached) and 2.9 months (95% CI, 2.1 months – not reached), respectively. The most frequent grade 3–4 immune-related adverse events were pneumonitis and colitis/esophagitis (both 6%) and autoimmune hepatitis and myocarditis (both 3%). Grade 5 autoimmune hepatitis was also reported in 3% of patients.

Pembrolizumab

Pembrolizumab was assessed in the non-randomized, open-label, phase II KEYNOTE-224 trial, which included 104 patients with HCC who progressed on or were intolerant to sorafenib.[159] Based on this study, the FDA granted accelerated approval for pembrolizumab for patients with HCC who were previously treated with sorafenib. Patients were treated with pembrolizumab for up to 35 cycles or until disease progression was confirmed or there was unacceptable toxicity.[533] Data from an updated analysis showed that 18.3% of patients (95% CI, 11.4%–27.1%) had an objective response. The median OS, PFS, TTP, and DOR were 13.2 months (95% CI, 9.7–15.3 months), 4.9 months (95% CI, 3.5–6.7 months), 4.8 months (95% CI, 3.9–7.0 months), and 21.0 months (range, 3.1 to 39.5+ months), respectively. The disease control rate was 61.5%. Twenty-five percent and 1% of patients had a grade 3–4 or grade 5 treatment-related adverse event, respectively. However, the phase 3 KEYNOTE-240 trial comparing pembrolizumab to a placebo in second-line HCC did not meet its primary endpoints (OS and PFS) based on the rigorous statistical plan.[157] Patients received treatment for 35 cycles or until the disease progressed or there was unacceptable toxicity. Data from the KEYNOTE-240 trial showed that the median OS with pembrolizumab versus placebo was 13.9 versus 10.6 months, respectively (HR, 0.771; 95% CI, 0.617–

Version 2.2025 © 2025 National Comprehensive Cancer Network© (NCCN©), All rights reserved. NCCN Guidelines® and this illustration may not be reproduced in any form without the express written permission of NCCN.

0.964), and the median PFS was 3.0 versus 2.8 months, respectively (HR, 0.718; 95% CI, 0.571–0.903).[534] Also, a difference in ORR was seen favoring pembrolizumab (18.3% vs. 4.4%), and the median DOR on pembrolizumab was 13.9 months compared to 15.2 months on placebo. Grade 3 or 4 adverse events occurred in 53.4% of patients on pembrolizumab and in 46.3% of patients on placebo. Pembrolizumab has maintained its accelerated approval in patients previously treated with sorafenib.

Pembrolizumab was also assessed in the phase III KEYNOTE-394 study in Asia in patients with advanced HCC with progression on or after or intolerance to sorafenib or oxaliplatin-based chemotherapy.[158] Patients were randomized 2:1 to receive pembrolizumab or placebo and all received best supportive care. Data demonstrated that treatment with pembrolizumab resulted in a significant amelioration in the median OS (14.6 vs. 13.0 months for placebo; HR, 0.79; 95% CI, 0.63–0.99; $P = .0180$) and median PFS (2.6 vs. 2.3 months for placebo; HR, 0.74; 95% CI, 0.60–0.92; $P = .0032$). An ORR of 12.7% (95% CI, 9.1%–17.0%) was obtained in the pembrolizumab arm versus 1.3% (95% CI, 0.2%–4.6%) ($P < .0001$) in the placebo arm. Twelve percent, 1.3%, and 1% of patients in the pembrolizumab arm experienced grades 3, 4, and 5 treatment-related adverse events, respectively. In the placebo arm, these percentages were 5.9%, 0%, and 0%, respectively.

Ramucirumab

In a phase III randomized REACH trial, the monoclonal antibody against VEGFR2, ramucirumab, was assessed as second-line therapy following sorafenib in patients with advanced HCC ($N = 565$).[535,536] Though this regimen did not improve median OS (9.2 vs. 7.6 months; HR, 0.87), median PFS (HR, 0.63; 95% CI, 0.52–0.75; $P < .001$) and TTP (HR, 0.59; 95% CI, 0.49–0.72; $P < .001$) were improved, relative to the placebo group. A subgroup analysis in patients with a baseline AFP level of ≥400 ng/mL (n = 250) showed that the median OS and PFS were 7.8 months (HR, 0.67) and 2.7 months, respectively, for patients in the ramucirumab arm, and 4.2 months and 1.5 months, respectively, for patients in the placebo arm. Analyses of patient-focused outcomes showed that deterioration of symptoms was not significantly different in patients randomized to receive ramucirumab, compared to the placebo group.[536]

Based on these findings, the REACH-2 randomized phase III trial assessed the efficacy of ramucirumab in patients with HCC who had disease progression on or after sorafenib who had a baseline AFP level of ≥400 ng/mL (N = 292).[537] OS and PFS were greater in patients who received ramucirumab with best supportive care, compared to patients randomized to receive a placebo with best supportive care (median OS, 8.5 vs. 7.3 months, respectively; HR, 0.71; 95% CI, 0.53–0.95; $P = .0199$; median PFS 2.8 vs. 1.6 months, respectively; HR, 0.45; 95% CI, 0.34–0.60; $P < .0001$). A pooled analysis of results from REACH and REACH-2, including 542 patients with disease progression on or after sorafenib who had a baseline AFP level of ≥400 ng/mL, showed that median OS was greater for patients who received ramucirumab, compared to patients who received the placebo (8.1 vs. 5.0 months, respectively; HR, 0.69; 95% CI, 0.57–0.84; $P = .0002$).[537] Post hoc analyses of the REACH and REACH-2 trials revealed the importance of AFP as a prognostic factor as the AFP response was significantly higher in patients treated with ramucirumab compared to placebo ($P < .0001$).[538] An AFP response was associated with significantly improved survival (13.6 vs. 5.6 months; HR, 0.45; $P < .0001$).[538] A real-world study reported a higher median PFS in patients with HCC and serum AFP levels of ≥400 ng/mL who were treated with ramucirumab (n = 13) compared to those treated with sorafenib (n = 11) as subsequent-line therapy (2.7 vs. 0.9 months; $P = .005$).[539] No significant difference was reported for ORR (9.1% vs. 54.5%) and disease control rate (0.0% vs. 22.2%).

Version 2.2025 © 2025 National Comprehensive Cancer Network© (NCCN©), All rights reserved. NCCN Guidelines® and this illustration may not be reproduced in any form without the express written permission of NCCN.

PLEASE NOTE that use of this NCCN Content is governed by the End-User License Agreement, and you MAY NOT distribute this Content or use it with any artificial intelligence model or tool.
Printed by Galya Basol Kochav on 1/5/2026 10:54:24 AM. Copyright © 2026 National Comprehensive Cancer Network, Inc. All Rights Reserved.

Nivolumab

Based on the results from the CheckMate 040 trial, the FDA gave accelerated approval for nivolumab in 2017 for patients with HCC who progressed on or after sorafenib.[540] In 2021, the FDA's Oncologic Drugs Advisory Committee voted against maintaining the accelerated approval of nivolumab as a single agent for patients with advanced HCC who were previously treated with sorafenib.[541] As treatment options are limited, the Panel elected to maintain nivolumab as a subsequent-line treatment option. The phase I/II CheckMate 040 cohort 5 trial enrolled patients with advanced CTP B HCC who received prior sorafenib treatment as well as those who did not receive prior treatment with sorafenib.[542] Patients received treatment with nivolumab. The investigator-assessed ORR was 12% (95% CI, 5%–25%) overall and 13% in patients who received prior treatment with sorafenib. The median time to response and DOR were 2.7 months (interquartile range, 1.4–4.2 months) and 9.9 months (95% CI, 9.7–9.9 months), respectively. The median OS and PFS were 7.6 months (95% CI, 4.4–10.5 months) and 2.7 months (95% CI, 1.6–4.0 months), respectively, for all patients and 7.4 months (95% CI, 2.3–12.1 months) and 2.2 months (1.4–4.2 months), respectively, in patients who received prior sorafenib treatment. Treatment-related adverse events that were grade 3/4 were reported in 24% of all patients and in 33% of patients who received prior sorafenib treatment.

Nivolumab and hyaluronidase-nvhy subcutaneous injection may be substituted for IV nivolumab. Nivolumab and hyaluronidase-nvhy has different dosing and administration instructions compared to IV nivolumab.

Dostarlimab-gxly

Dostarlimab-gxly, another anti-PD-1 antibody, was assessed in the open-label phase I GARNET study with two cohorts.[543] One cohort had patients with advanced or recurrent microsatellite instability-high (MSI-H)/mismatch repair deficient (dMMR) endometrial cancer and another had patients with advanced or recurrent MSI-H/dMMR or POLE-altered non-endometrial solid tumors. An interim analysis revealed an ORR of 44.0% (95% CI, 38.6%–49.6%), per RECIST version 1.1, for patients with dMMR tumors. The ORR for the cohort with non-endometrial cancer was 43.1% (95% CI, 36.2%–50.2%). The median DOR and median OS were not reached in either cohort. In the overall dMMR cohort, the median PFS was 6.9 months (95% CI, 4.2–13.6 months). In the non-endometrial cancer cohort, the median PFS was 7.1 months (95% CI, 3.6–19.5 months). In patients with colorectal cancer, the ORR was 43.5% (95% CI, 34.3%–53.0%). The most frequent grade 3 or higher treatment-related adverse events were anemia (2.5%), increased lipase (1.3%), and increased alanine aminotransferase (1.9%).

Selpercatinib

Selpercatinib, a selective RET kinase inhibitor, was investigated in the phase 1/2 LIBRETTO-001 clinical trial in patients with *RET* fusion-positive tumors.[544] Of 41 patients who were evaluable for efficacy and with tumors other than lung or thyroid, the ORR, as assessed by an independent review committee, was 43.9% (95% CI, 28.5%–60.3%).

NTRK Inhibitors

NTRK1/NTRK2/NTRK3 fusions are extremely rare in HCC. However, studies have demonstrated response rates in the 50% to 75% range in pre-treated *NTRK* fusion-positive tumors.[545-547]

Other Agents and Emerging Therapies

In a systematic review and meta-analysis of 22 studies of advanced HCC with 699 patients with CTP Class B and 2114 patients with CTP Class A treated with immune checkpoint inhibitors, researchers found that those with CTP Class B had a worse ORR and DCR compared to those with CTP Class A.[548] Patients with CTP Class B had an ORR of 14% (95% CI, 11%–17%) and a DCR of 46% (95% CI, 36%–56%). The median OS and median PFS of these patients were 5.49 months (95% CI, 3.57–7.42 months) and

Version 2.2025 © 2025 National Comprehensive Cancer Network© (NCCN©), All rights reserved. NCCN Guidelines® and this illustration may not be reproduced in any form without the express written permission of NCCN.

PLEASE NOTE that use of this NCCN Content is governed by the End-User License Agreement, and you MAY NOT distribute this Content or use it with any artificial intelligence model or tool.
Printed by Galya Basol Kochav on 1/5/2026 10:54:24 AM. Copyright © 2026 National Comprehensive Cancer Network, Inc. All Rights Reserved.

2.68 months (95% CI, 1.85–3.52 months), respectively. Additionally, 12% of them had a grade 3 or higher treatment-related adverse event compared to 11% of patients with CTP Class A.

The combination of lenvatinib and pembrolizumab was investigated in the randomized phase III LEAP-002 trial against lenvatinib and placebo for the frontline treatment of unresectable HCC. The study did not achieve the preset significance for its primary endpoints (OS and PFS).[549] A median OS of 21.2 months (95% CI, 19.0–23.6 months) was obtained with the combination of lenvatinib and pembrolizumab, as opposed to 19.0 months (95% CI, 17.2–21.7 months) with lenvatinib and placebo (HR, 0.84; 95% CI, 0.71–1.00; $P = .023$). The PFS analysis demonstrated an HR of 0.87 (95% CI, 0.73–1.02; $P = .047$), with a median PFS of 8.2 months (95% CI, 6.4–8.4 months) for lenvatinib and pembrolizumab and 8.0 months (95% CI, 6.3–8.2 months) for lenvatinib and placebo. At final analysis, the ORR, as assessed by RECIST version 1.1, was 26.1% (95% CI, 21.8%–30.7%) for the lenvatinib/pembrolizumab arm compared to 17.5% (95% CI, 13.9%–21.6%) for the lenvatinib/placebo arm. Sixty-two percent of patients in the first group experienced grade 3–4 treatment-related adverse events compared to 57% of patients in the second group. Long-term follow-up data published in an abstract showed that with a median follow-up of 59.2 months, the HR for OS was maintained at 0.80 (95% CI, 0.69–0.94).[550] Rates for OS were 19.7% with lenvatinib/pembrolizumab and 10.7% with lenvatinib/placebo at 60 months.

In a phase III trial, linifanib, a VEGF and PDGFR inhibitor, was compared to sorafenib in patients with advanced HCC ($N = 1035$).[551] Patients who were randomized to receive linifanib had a greater ORR ($P = .018$), but also a greater rate of serious adverse events ($P < .001$) and adverse events leading to dose reduction and drug discontinuation ($P < .001$), compared to patients randomized to receive sorafenib. Overall, survival did not significantly differ between the two drugs.

An oral MET inhibitor, tivantinib, was compared to a placebo in a phase III trial including 340 patients with HCC that was previously treated with sorafenib and had high MET expression,[552] based on encouraging results from a randomized phase II trial.[553] OS did not significantly differ between patients randomized to receive tivantinib or placebo.

Data from a phase II trial have demonstrated potential activity of axitinib and tolerability for patients with intermediate/advanced CTP class A disease as a second-line therapy.[554] In the phase III AHELP study, patients previously treated with at least one line of systemic therapy were randomized 2:1 to receive apatinib or placebo.[555] The results showed that compared to the placebo arm, patients treated with apatinib had significantly improved median OS (8.7 vs. 6.8 months; HR, 0.785; 95% CI, 0.617–0.998; $P = .048$), median PFS (4.5 vs. 1.9 months; HR, 0.471; 95% CI, 0.369–0.601; $P < .0001$), and ORR (11% vs. 2%). In patients treated with apatinib, the most frequent grade 3 or 4 adverse events were hypertension (28% vs. 2% in the placebo arm), hand-foot syndrome (18% vs. 0% in the placebo arm), and reduction in platelet count (13% vs. 1% in the placebo arm).

Cohort 6 of the open-label randomized phase I/II CheckMate 040 trial comprised patients with advanced HCC who were treatment-naïve, or with intolerance to sorafenib, or with disease progression on sorafenib.[556] Patients were treated with nivolumab plus cabozantinib or nivolumab plus cabozantinib with ipilimumab. Seventeen percent of patients treated with the doublet therapy had a response, compared to 29% of those treated with the triplet therapy. The median DOR, median OS, and median PFS were 8.3 months (vs. not reached in the triplet arm), 20.2 months (vs. 22.1 months), and 5.1 months (vs. 4.3 months), respectively, in the doublet arm. Fifty percent of patients in the doublet arm reported a grade 3–4 treatment-related adverse event, compared to 74% of patients in the triplet arm.

Version 2.2025 © 2025 National Comprehensive Cancer Network© (NCCN©), All rights reserved. NCCN Guidelines® and this illustration may not be reproduced in any form without the express written permission of NCCN.

PLEASE NOTE that use of this NCCN Content is governed by the End-User License Agreement, and you MAY NOT distribute this Content or use it with any artificial intelligence model or tool.
Printed by Galya Basol Kochav on 1/5/2026 10:54:24 AM. Copyright © 2026 National Comprehensive Cancer Network, Inc. All Rights Reserved.

There is no established indication for routine molecular profiling in HCC, but it should be considered on a case-by-case basis. Clinical trials of molecular profiling and/or targeted therapies are encouraged in this population. Tumor molecular testing may be warranted in patients with atypical histology, cHCC-CCA histology, unusual clinical presentations, or for clinical trial enrollment. Evidence remains insufficient for definitive recommendations regarding specific criteria to guide genetic risk assessment in hepatobiliary cancers or for universal germline testing in these tumors.

Though exceedingly rare in other tumor types, incidence of *IDH1* mutations may be higher in clear cell HCC histology.[557] The PD-L1 system functions to inhibit T-cell functions. PD-L1 protein expression on malignant or inflammatory associated tumor cells generally indicates active tumor immunity suppressed by the PD-1/ PD-L1 system. The incidence of PD-L1-high in HCC ranges from around 13% to 20% for tumor cell PD-L1 expression ≥1%, and from around 42% to 59% for combined tumor plus immune cell PD-L1 expression ≥1%. [159,558,559] There is no established role for MSI, MMR, tumor mutational burden (TMB), or PD-L1 testing in HCC at this time. Immune checkpoint inhibition has shown clinical benefit leading to regulatory approvals in patients with HCC without selection for MSI, MMR, TMB, or PD-L1 status.[157,159,505,558]

Management of Resectable Disease

Results of an RCT (*N* = 200) showed that partial hepatectomy was associated with better OS and RFS, relative to combination TACE and RFA.[560] In a meta-analysis of 18 studies with 5986 patients comparing TACE to resection, the survival benefits were significantly higher in the hepatectomy study arm.[561] The consensus of the Panel is that in patients being considered for surgery, patients with CTP Class A or highly selected patients with CTP Class B liver function, who fit UNOS criteria/extended criteria and are resectable could be considered for resection or transplant. Patients should be evaluated by a multidisciplinary team.

Hepatic resection is a potentially curative treatment option for patients with the following disease characteristics: adequate liver function (CTP Class A and selected CTP Class B patients without portal hypertension), solitary mass without major vascular invasion, and adequate liver remnant.[562,563] Resection or liver transplant (if transplant criteria are met) are preferred options for patients who meet resection criteria (CTP Class A or CTP Class B [highly selected patients] liver function, no portal hypertension, suitable tumor location, adequate liver reserve, and suitable liver remnant), with or without transplant criteria. Locoregional therapy is also a recommended option and includes ablation (preferred), arterially directed therapies, and RT. Ablation has shown benefit in patients with tumors <3 cm in diameter who are not resection candidates due to age or comorbidity.[374] The presence of extrahepatic metastasis is considered to be a contraindication for resection. Hepatic resection is controversial in patients with limited multifocal disease as well as those with major vascular invasion. Liver resection in patients with major vascular invasion should only be performed in highly selected situations by experienced teams.

Transplantation is recommended for patients who meet the UNOS criteria (AFP level ≤1000 ng/mL and radiologic evidence of either a single lesion ≥2 cm and ≤5 cm in diameter, or 2–3 lesions ≥1 cm and ≤3 cm in diameter and no evidence of macrovascular involvement or extrahepatic disease) or can be downstaged to within Milan criteria. Transplant also provides a curative intent option for patients with CTP Class B and C cirrhosis who would not otherwise be surgical candidates. Patients should be referred to a liver transplant center. The guidelines recommend bridge therapy as indicated for patients eligible for liver transplant. Patients with tumor characteristics that are marginally outside of the UNOS guidelines should be considered for transplantation.[564] Additionally, transplantation can be considered for

Version 2.2025 © 2025 National Comprehensive Cancer Network© (NCCN©), All rights reserved. NCCN Guidelines® and this illustration may not be reproduced in any form without the express written permission of NCCN.

PLEASE NOTE that use of this NCCN Content is governed by the End-User License Agreement, and you MAY NOT distribute this Content or use it with any artificial intelligence model or tool.
Printed by Galya Basol Kochav on 1/5/2026 10:54:24 AM. Copyright © 2026 National Comprehensive Cancer Network, Inc. All Rights Reserved.

patients who have undergone successful downstaging therapy (ie, tumor currently meeting Milan criteria).[565]

Surveillance

Although data on the role of surveillance in patients with resected HCC are very limited, recommendations are based on the consensus that earlier identification of disease, primary or recurrent, may facilitate patient eligibility for investigational studies or other forms of life-prolonging treatment. The Panel recommends ongoing surveillance—specifically, multiphasic, high-quality, cross-sectional imaging of the chest, abdomen, and pelvis every 3 to 6 months for 2 years, then every 6 months. Multiphasic cross-sectional imaging (ie, CT or MRI) is the preferred method for surveillance following treatment because of its reliability in assessing arterial vascularity,[566] which is associated with increased risk of HCC recurrence following treatment.[567,568] Elevated AFP levels are associated with poor prognosis following treatment[282,569,570] and should be measured every 3 to 6 months for 2 years, then every 6 months. Surveillance imaging and AFP should continue for at least 5 years and thereafter screening is dependent on HCC risk factors. Re-evaluation according to the initial workup should be considered in the event of disease progression. Early imaging per local protocol can be considered for patients treated with locoregional therapy.

Management of Advanced Disease

Enrollment in a clinical trial, systemic therapy, and best supportive care are options for patients with liver-confined, unresectable HCC deemed ineligible for transplant; and for those with extrahepatic/metastatic HCC deemed ineligible for resection, transplant, or locoregional therapy. Additionally, locoregional therapy (ablation, arterially directed therapies, or RT) is also a treatment option for patients with liver-confined, unresectable HCC deemed ineligible for transplant. Therapies listed below may have limited safety data available for CTP Class B or C liver function. The Panel recommends extreme caution in patients with elevated bilirubin levels. The prescribing information for individual agents should be consulted.

The combination of atezolizumab plus bevacizumab and the combination of tremelimumab-actl plus durvalumab are category 1 preferred first-line systemic therapy options. Durvalumab (category 1), lenvatinib (category 1), sorafenib (category 1), tislelizumab-jsgr (category 1), nivolumab plus ipilimumab, and pembrolizumab (category 2B) are listed as other recommended options for first-line systemic therapy. Pembrolizumab is a recommended treatment option for patients with or without MSI-H tumors and is FDA-approved for MSI-H tumors in the subsequent-line setting.

The Panel now recommends several subsequent-line therapy options for disease progression following first-line systemic therapy. However, there are no comparative data to define optimal treatment after first-line systemic therapy. Options include cabozantinib (category 1) and regorafenib (category 1). Regimens recommended for first-line systemic therapy are reasonable to consider for subsequent-line treatment, if not previously used (atezolizumab plus bevacizumab, tremelimumab-actl plus durvalumab, durvalumab, lenvatinib, sorafenib, tislelizumab-jsgr, nivolumab plus ipilimumab, and pembrolizumab) and are included as other recommended regimens. When used as subsequent-line therapy, atezolizumab plus bevacizumab, durvalumab, tislelizumab-jsgr, and pembrolizumab are recommended for patients who have not been previously treated with a checkpoint inhibitor; and tremelimumab-actl plus durvalumab and nivolumab plus ipilimumab are recommended for patients who have not been previously treated with anti CTL4-based combinations. Regimens that are included as useful in certain circumstances are ramucirumab for patients with a baseline AFP level of ≥400 ng/mL (category 1); nivolumab for patients who have not been previously treated with a checkpoint inhibitor; dostarlimab-gxly for patients with MSI-H/dMMR recurrent or advanced tumors that have progressed on or following prior treatment, who

Version 2.2025 © 2025 National Comprehensive Cancer Network© (NCCN©), All rights reserved. NCCN Guidelines® and this illustration may not be reproduced in any form without the express written permission of NCCN.

PLEASE NOTE that use of this NCCN Content is governed by the End-User License Agreement, and you MAY NOT distribute this Content or use it with any artificial intelligence model or tool.
Printed by Galya Basol Kochav on 1/5/2026 10:54:24 AM. Copyright © 2026 National Comprehensive Cancer Network, Inc. All Rights Reserved.

have no satisfactory alternative treatment options, and who have not been previously treated with a checkpoint inhibitor (category 2B); selpercatinib for patients with *RET* gene fusion-positive tumors (category 2B); and entrectinib, larotrectinib, and repotrectinib for *NTRK* gene fusion-positive tumors.

The Panel recommends best supportive care as an option for patients with advanced disease. For all patients with advanced stages of HCC treated with any therapy except best supportive care, the Panel recommends periodic response assessment with cross-sectional imaging of sites at risk for metastatic progression, including chest, multiphase abdomen, and pelvis. In patients with elevated AFP tumor marker at the start of therapy, AFP changes on treatment have shown association with treatment response and survival. [529,538,571] Resection, transplant, and locoregional therapy should be reconsidered as treatment options. Subsequent-line systemic therapy is also an option if there is progression on or after systemic therapy.

Summary

HCC is associated with a poor prognosis. Many patients with HCC are diagnosed at an advanced stage. In the past few years, several advances have been made in the therapeutic approaches for patients with HCC.

Complete resection of the tumor in well-selected patients is currently the best available potentially curative treatment. Liver transplantation is a curative option for select patients with resectable tumors. Bridge therapy is recommended for patients with HCC to decrease tumor progression and the dropout rate from the liver transplantation waiting list.

Locoregional therapies (ablation, arterially directed therapies, and RT) are often the initial approach for patients with HCC who are not candidates for surgery or liver transplantation. Ablation should be considered as definitive treatment in the context of a multidisciplinary review in well-selected patients with small properly located tumors. Arterially directed therapies (TACE, DEB-TACE, or TARE with Y-90 microspheres) are appropriate for patients with unresectable tumors that are not amenable to ablation therapy. SBRT can be considered as an alternative to ablation and/or embolization techniques (especially for patients with 1–3 tumors and minimal or no extrahepatic disease) or when these therapies have failed or are contraindicated. Though it is currently rarely used, there are emerging data supporting its usefulness. PBT may also be used in select settings.

The combination of atezolizumab and bevacizumab, as well as the combination of tremelimumab-actl and durvalumab, are preferred first-line systemic therapy options. Durvalumab, lenvatinib, sorafenib, tislelizumab-jsgr, nivolumab plus ipilimumab, and pembrolizumab are listed as other recommended first-line options. A number of agents are recommended for subsequent-line systemic therapy for patients with disease progression. These include cabozantinib and regorafenib. Durvalumab, lenvatinib, sorafenib, tislelizumab-jsgr, nivolumab plus ipilimumab, and pembrolizumab are other recommended regimens that are reasonable to consider, if not previously used. Ramucirumab is a useful in certain circumstances option. Certain targeted therapies are also useful in certain circumstances and are based on the actionable alterations. These include dostarlimab-gxly, selpercatinib, larotrectinib, entrectinib, and repotrectinib.

It is essential that all patients be evaluated by a multidisciplinary team prior to initiation of treatment. Careful patient selection for treatment and patient engagement are essential. Patient participation in prospective clinical trials is encouraged for the treatment of patients with all stages of disease.

Version 2.2025 © 2025 National Comprehensive Cancer Network© (NCCN©), All rights reserved. NCCN Guidelines® and this illustration may not be reproduced in any form without the express written permission of NCCN.

PLEASE NOTE that use of this NCCN Content is governed by the End-User License Agreement, and you MAY NOT distribute this Content or use it with any artificial intelligence model or tool.
Printed by Galya Basol Kochav on 1/5/2026 10:54:24 AM. Copyright © 2026 National Comprehensive Cancer Network, Inc. All Rights Reserved.

References

1. Siegel RL, Kratzer TB, Giaquinto AN, et al. Cancer statistics, 2025. CA Cancer J Clin 2025;75:10–45. Available at: https://www.ncbi.nlm.nih.gov/pubmed/39817679.

2. PubMed Overview. Available at: https://pubmed.ncbi.nlm.nih.gov/about/. Accessed September 20, 2022.

3. Freedman-Cass DA, Fischer T, Alpert AB, et al. The value and process of iclusion: Using sensitive, respectful, and inclusive language and images in NCCN content. J Natl Compr Canc Netw 2023;21:434–441. Available at: https://www.ncbi.nlm.nih.gov/pubmed/37156485.

4. Danpanichkul P, Duangsonk K, Kalligeros M, et al. Alcohol-related liver disease, followed by metabolic dysfunction-associated steatotic liver disease, emerges as the fastest-growing aetiologies for primary liver cancer in the United States. Aliment Pharmacol Ther 2025;61:959–970. Available at: https://www.ncbi.nlm.nih.gov/pubmed/39757456.

5. Petrick JL, Kelly SP, Altekruse SF, et al. Future of hepatocellular carcinoma incidence in the United States forecast through 2030. J Clin Oncol 2016;34:1787–1794. Available at: https://www.ncbi.nlm.nih.gov/pubmed/27044939.

6. Herbst DA, Reddy KR. Risk factors for hepatocellular carcinoma. Clin Liver Dis (Hoboken) 2012;1:180–182. Available at: https://www.ncbi.nlm.nih.gov/pubmed/31186882.

7. Janevska D, Chaloska-Ivanova V, Janevski V. Hepatocellular carcinoma: Risk factors, diagnosis and treatment. Open Access Maced J Med Sci 2015;3:732–736. Available at: https://www.ncbi.nlm.nih.gov/pubmed/27275318.

8. Singal AG, Llovet JM, Yarchoan M, et al. AASLD Practice Guidance on prevention, diagnosis, and treatment of hepatocellular carcinoma. Hepatology 2023;78:1922–1965. Available at: https://www.ncbi.nlm.nih.gov/pubmed/37199193.

9. Di Bisceglie AM, Lyra AC, Schwartz M, et al. Hepatitis C-related hepatocellular carcinoma in the United States: influence of ethnic status. Am J Gastroenterol 2003;98:2060–2063. Available at: http://www.ncbi.nlm.nih.gov/pubmed/14499788.

10. Chen CJ, Yu MW, Liaw YF. Epidemiological characteristics and risk factors of hepatocellular carcinoma. J Gastroenterol Hepatol 1997;12:S294–308. Available at: http://www.ncbi.nlm.nih.gov/pubmed/9407350.

11. Yang HI, Lu SN, Liaw YF, et al. Hepatitis B e antigen and the risk of hepatocellular carcinoma. N Engl J Med 2002;347:168–174. Available at: http://www.ncbi.nlm.nih.gov/pubmed/12124405.

12. Chen G, Lin W, Shen F, et al. Past HBV viral load as predictor of mortality and morbidity from HCC and chronic liver disease in a prospective study. Am J Gastroenterol 2006;101:1797–1803. Available at: http://www.ncbi.nlm.nih.gov/pubmed/16817842.

13. Chen CJ, Yang HI, Su J, et al. Risk of hepatocellular carcinoma across a biological gradient of serum hepatitis B virus DNA level. JAMA 2006;295:65–73. Available at: http://www.ncbi.nlm.nih.gov/pubmed/16391218.

14. Lee MH, Yang HI, Lu SN, et al. Hepatitis C virus seromarkers and subsequent risk of hepatocellular carcinoma: long-term predictors from a community-based cohort study. J Clin Oncol 2010;28:4587–4593. Available at: http://www.ncbi.nlm.nih.gov/pubmed/20855826.

15. Ishiguro S, Inoue M, Tanaka Y, et al. Impact of viral load of hepatitis C on the incidence of hepatocellular carcinoma: A population-based cohort study (JPHC Study). Cancer Lett 2011;300:173–179. Available at: http://www.ncbi.nlm.nih.gov/pubmed/21035947.

16. Alter MJ. The epidemiology of acute and chronic hepatitis C. Clin Liver Dis 1997;1:559–568. Available at: http://www.ncbi.nlm.nih.gov/pubmed/15560058.

Version 2.2025 © 2025 National Comprehensive Cancer Network© (NCCN©), All rights reserved. NCCN Guidelines® and this illustration may not be reproduced in any form without the express written permission of NCCN.

PLEASE NOTE that use of this NCCN Content is governed by the End-User License Agreement, and you MAY NOT distribute this Content or use it with any artificial intelligence model or tool.
Printed by Galya Basol Kochav on 1/5/2026 10:54:24 AM. Copyright © 2026 National Comprehensive Cancer Network, Inc. All Rights Reserved.

17. Ryder SD, Irving WL, Jones DA, et al. Progression of hepatic fibrosis in patients with hepatitis C: a prospective repeat liver biopsy study. Gut 2004;53:451–455. Available at: http://www.ncbi.nlm.nih.gov/pubmed/14960533.

18. Falade-Nwulia O, Suarez-Cuervo C, Nelson DR, et al. Oral direct-acting agent therapy for hepatitis C virus infection: a systematic review. Ann Intern Med 2017;166:637–648. Available at: https://www.ncbi.nlm.nih.gov/pubmed/28319996.

19. Suwanthawornkul T, Anothaisintawee T, Sobhonslidsuk A, et al. Efficacy of second generation direct-acting antiviral agents for treatment naive hepatitis C genotype 1: a systematic review and network meta-analysis. PLoS One 2015;10:e0145953. Available at: https://www.ncbi.nlm.nih.gov/pubmed/26720298.

20. Ogata F, Kobayashi M, Akuta N, et al. Outcome of all-oral direct-acting antiviral regimens on the rate of development of hepatocellular carcinoma in patients with hepatitis C virus genotype 1-related chronic liver disease. Oncology 2017;93:92–98. Available at: https://www.ncbi.nlm.nih.gov/pubmed/28448999.

21. Carrat F, Fontaine H, Dorival C, et al. Clinical outcomes in patients with chronic hepatitis C after direct-acting antiviral treatment: a prospective cohort study. Lancet 2019;393:1453–1464. Available at: https://www.ncbi.nlm.nih.gov/pubmed/30765123.

22. The burden of primary liver cancer and underlying etiologies from 1990 to 2015 at the global, regional, and national level: results from the Global Burden of Disease Study 2015. JAMA Oncol 2017;3:1683–1691. Available at: https://www.ncbi.nlm.nih.gov/pubmed/28983565.

23. Lavanchy D. Worldwide epidemiology of HBV infection, disease burden, and vaccine prevention. J Clin Virol 2005;34 Suppl 1:1–3. Available at: http://www.ncbi.nlm.nih.gov/pubmed/16461208.

24. Goldstein ST, Zhou F, Hadler SC, et al. A mathematical model to estimate global hepatitis B disease burden and vaccination impact. Int J Epidemiol 2005;34:1329–1339. Available at: http://www.ncbi.nlm.nih.gov/pubmed/16249217.

25. Beasley RP, Hwang LY, Lin CC, Chien CS. Hepatocellular carcinoma and hepatitis B virus. A prospective study of 22 707 men in Taiwan. Lancet 1981;2:1129–1133. Available at: http://www.ncbi.nlm.nih.gov/pubmed/6118576.

26. Thiele M, Gluud LL, Fialla AD, et al. Large variations in risk of hepatocellular carcinoma and mortality in treatment naive hepatitis B patients: systematic review with meta-analyses. PLoS One 2014;9:e107177. Available at: http://www.ncbi.nlm.nih.gov/pubmed/25225801.

27. Kim WR, Loomba R, Berg T, et al. Impact of long-term tenofovir disoproxil fumarate on incidence of hepatocellular carcinoma in patients with chronic hepatitis B. Cancer 2015;121:3631–3638. Available at: https://www.ncbi.nlm.nih.gov/pubmed/26177866.

28. Chang MH, You SL, Chen CJ, et al. Decreased incidence of hepatocellular carcinoma in hepatitis B vaccinees: a 20-year follow-up study. J Natl Cancer Inst 2009;101:1348–1355. Available at: https://www.ncbi.nlm.nih.gov/pubmed/19759364.

29. Chang MH, You SL, Chen CJ, et al. Long-term effects of hepatitis B immunization of infants in preventing liver cancer. Gastroenterology 2016;151:472–480.e471. Available at: https://www.ncbi.nlm.nih.gov/pubmed/27269245.

30. McMahon BJ, Bulkow LR, Singleton RJ, et al. Elimination of hepatocellular carcinoma and acute hepatitis B in children 25 years after a hepatitis B newborn and catch-up immunization program. Hepatology 2011;54:801–807. Available at: https://www.ncbi.nlm.nih.gov/pubmed/21618565.

31. Asselah T, Rizzetto M. Hepatitis D virus infection. N Engl J Med 2023;389:58–70. Available at: https://www.ncbi.nlm.nih.gov/pubmed/37407002.

Version 2.2025 © 2025 National Comprehensive Cancer Network© (NCCN©), All rights reserved. NCCN Guidelines® and this illustration may not be reproduced in any form without the express written permission of NCCN.

PLEASE NOTE that use of this NCCN Content is governed by the End-User License Agreement, and you MAY NOT distribute this Content or use it with any artificial intelligence model or tool.
Printed by Galya Basol Kochav on 1/5/2026 10:54:24 AM. Copyright © 2026 National Comprehensive Cancer Network, Inc. All Rights Reserved.

32. Fattovich G, Stroffolini T, Zagni I, Donato F. Hepatocellular carcinoma in cirrhosis: incidence and risk factors. Gastroenterology 2004;127:S35–50. Available at: http://www.ncbi.nlm.nih.gov/pubmed/15508101.

33. Blonski W, Kotlyar DS, Forde KA. Non-viral causes of hepatocellular carcinoma. World J Gastroenterol 2010;16:3603–3615. Available at: http://www.ncbi.nlm.nih.gov/pubmed/20677332.

34. Marrero JA, Kulik LM, Sirlin CB, et al. Diagnosis, staging, and management of hepatocellular carcinoma: 2018 Practice Guidance by the American Association for the Study of Liver Diseases. Hepatology 2018;68:723–750. Available at: https://www.ncbi.nlm.nih.gov/pubmed/29624699.

35. Asare GA, Bronz M, Naidoo V, Kew MC. Synergistic interaction between excess hepatic iron and alcohol ingestion in hepatic mutagenesis. Toxicology 2008;254:11–18. Available at: http://www.ncbi.nlm.nih.gov/pubmed/18852013.

36. Singal AK, Anand BS. Mechanisms of synergy between alcohol and hepatitis C virus. J Clin Gastroenterol 2007;41:761–772. Available at: http://www.ncbi.nlm.nih.gov/pubmed/17700425.

37. Volk ML, Marrero JA. Early detection of liver cancer: diagnosis and management. Curr Gastroenterol Rep 2008;10:60–66. Available at: http://www.ncbi.nlm.nih.gov/pubmed/18417044.

38. Terrault NA, Bzowej NH, Chang KM, et al. AASLD guidelines for treatment of chronic hepatitis B. Hepatology 2016;63:261–283. Available at: https://www.ncbi.nlm.nih.gov/pubmed/26566064.

39. Beaton MD, Adams PC. Prognostic factors and survival in patients with hereditary hemochromatosis and cirrhosis. Can J Gastroenterol 2006;20:257–260. Available at: http://www.ncbi.nlm.nih.gov/pubmed/16609753.

40. Yeoman AD, Al-Chalabi T, Karani JB, et al. Evaluation of risk factors in the development of hepatocellular carcinoma in autoimmune hepatitis: Implications for follow-up and screening. Hepatology 2008;48:863–870. Available at: http://www.ncbi.nlm.nih.gov/pubmed/18752332.

41. Tansel A, Katz LH, El-Serag HB, et al. Incidence and determinants of hepatocellular carcinoma in autoimmune hepatitis: a systematic review and meta-analysis. Clin Gastroenterol Hepatol 2017;15:1207–1217.e1204. Available at: https://www.ncbi.nlm.nih.gov/pubmed/28215616.

42. Arnaoutakis DJ, Mavros MN, Shen F, et al. Recurrence patterns and prognostic factors in patients with hepatocellular carcinoma in noncirrhotic liver: a multi-institutional analysis. Ann Surg Oncol 2014;21:147–154. Available at: https://www.ncbi.nlm.nih.gov/pubmed/23959056.

43. McIntyre CA, Chou JF, Gonen M, et al. Hepatocellular carcinoma in patients with no identifiable risk factors. HPB (Oxford) 2021;23:118–126. Available at: https://www.ncbi.nlm.nih.gov/pubmed/32591247.

44. Makarova-Rusher OV, Altekruse SF, McNeel TS, et al. Population attributable fractions of risk factors for hepatocellular carcinoma in the United States. Cancer 2016;122:1757–1765. Available at: https://www.ncbi.nlm.nih.gov/pubmed/26998818.

45. Pearson-Stuttard J, Zhou B, Kontis V, et al. Worldwide burden of cancer attributable to diabetes and high body-mass index: a comparative risk assessment. Lancet Diabetes Endocrinol 2018;6:95–104. Available at: https://www.ncbi.nlm.nih.gov/pubmed/29195904.

46. Kanwal F, Kramer JR, Mapakshi S, et al. Risk of hepatocellular cancer in patients with non-alcoholic fatty liver disease. Gastroenterology 2018;155:1828–1837.e1822. Available at: https://www.ncbi.nlm.nih.gov/pubmed/30144434.

47. Alexander M, Loomis AK, van der Lei J, et al. Risks and clinical predictors of cirrhosis and hepatocellular carcinoma diagnoses in adults with diagnosed NAFLD: real-world study of 18 million patients in four European cohorts. BMC Med 2019;17:95. Available at: https://www.ncbi.nlm.nih.gov/pubmed/31104631.

Version 2.2025 © 2025 National Comprehensive Cancer Network© (NCCN©), All rights reserved. NCCN Guidelines® and this illustration may not be reproduced in any form without the express written permission of NCCN.

PLEASE NOTE that use of this NCCN Content is governed by the End-User License Agreement, and you MAY NOT distribute this Content or use it with any artificial intelligence model or tool.
Printed by Galya Basol Kochav on 1/5/2026 10:54:24 AM. Copyright © 2026 National Comprehensive Cancer Network, Inc. All Rights Reserved.

48. Sohn W, Lee HW, Lee S, et al. Obesity and the risk of primary liver cancer: A systematic review and meta-analysis. Clin Mol Hepatol 2021;27:157–174. Available at: https://www.ncbi.nlm.nih.gov/pubmed/33238333.

49. Huang DQ, Noureddin N, Ajmera V, et al. Type 2 diabetes, hepatic decompensation, and hepatocellular carcinoma in patients with non-alcoholic fatty liver disease: An individual participant-level data meta-analysis. Lancet Gastroenterol Hepatol 2023;8:829–836. Available at: https://www.ncbi.nlm.nih.gov/pubmed/37419133.

50. Le P, Tatar M, Dasarathy S, et al. Estimated burden of metabolic dysfunction-associated steatotic liver disease in US adults, 2020 to 2050. JAMA Netw Open 2025;8:e2454707. Available at: https://www.ncbi.nlm.nih.gov/pubmed/39821400.

51. Marchesini G, Bugianesi E, Forlani G, et al. Nonalcoholic fatty liver, steatohepatitis, and the metabolic syndrome. Hepatology 2003;37:917–923. Available at: http://www.ncbi.nlm.nih.gov/pubmed/12668987.

52. Takamatsu S, Noguchi N, Kudoh A, et al. Influence of risk factors for metabolic syndrome and non-alcoholic fatty liver disease on the progression and prognosis of hepatocellular carcinoma. Hepatogastroenterology 2008;55:609–614. Available at: http://www.ncbi.nlm.nih.gov/pubmed/18613418.

53. Kim NG, Nguyen PP, Dang H, et al. Temporal trends in disease presentation and survival of patients with hepatocellular carcinoma: A real-world experience from 1998 to 2015. Cancer 2018;124:2588–2598. Available at: https://www.ncbi.nlm.nih.gov/pubmed/29624631.

54. Younossi ZM. Review article: current management of non-alcoholic fatty liver disease and non-alcoholic steatohepatitis. Aliment Pharmacol Ther 2008;28:2–12. Available at: http://www.ncbi.nlm.nih.gov/pubmed/18410557.

55. Ascha MS, Hanouneh IA, Lopez R, et al. The incidence and risk factors of hepatocellular carcinoma in patients with nonalcoholic steatohepatitis. Hepatology 2010;51:1972–1978. Available at: http://www.ncbi.nlm.nih.gov/pubmed/20209604.

56. White DL, Kanwal F, El-Serag HB. Association between nonalcoholic fatty liver disease and risk for hepatocellular cancer, based on systematic review. Clin Gastroenterol Hepatol 2012;10:1342–1359.e1342. Available at: http://www.ncbi.nlm.nih.gov/pubmed/23041539.

57. Sanyal AJ, Banas C, Sargeant C, et al. Similarities and differences in outcomes of cirrhosis due to nonalcoholic steatohepatitis and hepatitis C. Hepatology 2006;43:682–689. Available at: http://www.ncbi.nlm.nih.gov/pubmed/16502396.

58. Yatsuji S, Hashimoto E, Tobari M, et al. Clinical features and outcomes of cirrhosis due to non-alcoholic steatohepatitis compared with cirrhosis caused by chronic hepatitis C. J Gastroenterol Hepatol 2009;24:248–254. Available at: http://www.ncbi.nlm.nih.gov/pubmed/19032450.

59. Loomba R, Lim JK, Patton H, El-Serag HB. AGA clinical practice update on screening and surveillance for hepatocellular carcinoma in patients with nonalcoholic fatty liver disease: Expert review. Gastroenterology 2020;158:1822–1830. Available at: https://www.ncbi.nlm.nih.gov/pubmed/32006545.

60. El-Serag HB, Davila JA. Is fibrolamellar carcinoma different from hepatocellular carcinoma? A US population-based study. Hepatology 2004;39:798–803. Available at: https://www.ncbi.nlm.nih.gov/pubmed/14999699.

61. Stipa F, Yoon SS, Liau KH, et al. Outcome of patients with fibrolamellar hepatocellular carcinoma. Cancer 2006;106:1331–1338. Available at: https://www.ncbi.nlm.nih.gov/pubmed/16475212.

62. Mayo SC, Mavros MN, Nathan H, et al. Treatment and prognosis of patients with fibrolamellar hepatocellular carcinoma: a national perspective. J Am Coll Surg 2014;218:196–205. Available at: https://www.ncbi.nlm.nih.gov/pubmed/24315886.

Version 2.2025 © 2025 National Comprehensive Cancer Network© (NCCN©), All rights reserved. NCCN Guidelines® and this illustration may not be reproduced in any form without the express written permission of NCCN.

PLEASE NOTE that use of this NCCN Content is governed by the End-User License Agreement, and you MAY NOT distribute this Content or use it with any artificial intelligence model or tool.
Printed by Galya Basol Kochav on 1/5/2026 10:54:24 AM. Copyright © 2026 National Comprehensive Cancer Network, Inc. All Rights Reserved.

63. Groeschl RT, Miura JT, Wong RK, et al. Multi-institutional analysis of recurrence and survival after hepatectomy for fibrolamellar carcinoma. J Surg Oncol 2014;110:412–415. Available at: https://www.ncbi.nlm.nih.gov/pubmed/24844420.

64. Lafaro KJ, Pawlik TM. Fibrolamellar hepatocellular carcinoma: current clinical perspectives. J Hepatocell Carcinoma 2015;2:151–157. Available at: https://www.ncbi.nlm.nih.gov/pubmed/27508204.

65. Palm V, Sheng R, Mayer P, et al. Imaging features of fibrolamellar hepatocellular carcinoma in gadoxetic acid-enhanced MRI. Cancer Imaging 2018;18:9. Available at: https://www.ncbi.nlm.nih.gov/pubmed/29490696.

66. Ang CS, Kelley RK, Choti MA, et al. Clinicopathologic characteristics and survival outcomes of patients with fibrolamellar carcinoma: Data from the Fibrolamellar Carcinoma Consortium. Gastrointest Cancer Res 2013;6:3–9. Available at: https://www.ncbi.nlm.nih.gov/pubmed/23505572.

67. Honeyman JN, Simon EP, Robine N, et al. Detection of a recurrent DNAJB1-PRKACA chimeric transcript in fibrolamellar hepatocellular carcinoma. Science 2014;343:1010–1014. Available at: https://www.ncbi.nlm.nih.gov/pubmed/24578576.

68. Cornella H, Alsinet C, Sayols S, et al. Unique genomic profile of fibrolamellar hepatocellular carcinoma. Gastroenterology 2015;148:806–818.e810. Available at: https://www.ncbi.nlm.nih.gov/pubmed/25557953.

69. Darcy DG, Chiaroni-Clarke R, Murphy JM, et al. The genomic landscape of fibrolamellar hepatocellular carcinoma: whole genome sequencing of ten patients. Oncotarget 2015;6:755–770. Available at: https://www.ncbi.nlm.nih.gov/pubmed/25605237.

70. Graham RP, Jin L, Knutson DL, et al. DNAJB1-PRKACA is specific for fibrolamellar carcinoma. Mod Pathol 2015;28:822–829. Available at: https://www.ncbi.nlm.nih.gov/pubmed/25698061.

71. El Dika I, Mayer RJ, Venook AP, et al. A multicenter randomized three-arm phase II study of (1) everolimus, (2) estrogen deprivation therapy (EDT) with leuprolide + letrozole, and (3) everolimus + EDT in patients with unresectable fibrolamellar carcinoma. Oncologist 2020;25:925–e1603. Available at: https://www.ncbi.nlm.nih.gov/pubmed/32400000.

72. Heimbach JK, Kulik LM, Finn RS, et al. AASLD guidelines for the treatment of hepatocellular carcinoma. Hepatology 2018;67:358–380. Available at: https://www.ncbi.nlm.nih.gov/pubmed/28130846.

73. European Association for the Study of the L. EASL Clinical Practice Guidelines on the management of hepatocellular carcinoma. J Hepatol 2025;82:315–374. Available at: https://www.ncbi.nlm.nih.gov/pubmed/39690085.

74. Zhang B-H, Yang B-H, Tang Z-Y. Randomized controlled trial of screening for hepatocellular carcinoma. J Cancer Res Clin Oncol 2004;130:417–422. Available at: http://www.ncbi.nlm.nih.gov/pubmed/15042359.

75. Chang P-E, Ong W-C, Lui H-F, Tan C-K. Is the prognosis of young patients with hepatocellular carcinoma poorer than the prognosis of older patients? A comparative analysis of clinical characteristics, prognostic features, and survival outcome. J Gastroenterol 2008;43:881–888. Available at: http://www.ncbi.nlm.nih.gov/pubmed/19012042.

76. El-Serag HB, Marrero JA, Rudolph L, Reddy KR. Diagnosis and treatment of hepatocellular carcinoma. Gastroenterology 2008;134:1752–1763. Available at: http://www.ncbi.nlm.nih.gov/pubmed/18471552.

77. Waidely E, Al-Yuobi AR, Bashammakh AS, et al. Serum protein biomarkers relevant to hepatocellular carcinoma and their detection. Analyst 2016;141:36–44. Available at: https://www.ncbi.nlm.nih.gov/pubmed/26606739.

78. Zhang B, Yang B. Combined alpha fetoprotein testing and ultrasonography as a screening test for primary liver cancer. J Med Screen 1999;6:108–110. Available at: http://www.ncbi.nlm.nih.gov/pubmed/10444731.

Version 2.2025 © 2025 National Comprehensive Cancer Network© (NCCN©), All rights reserved. NCCN Guidelines® and this illustration may not be reproduced in any form without the express written permission of NCCN.

PLEASE NOTE that use of this NCCN Content is governed by the End-User License Agreement, and you MAY NOT distribute this Content or use it with any artificial intelligence model or tool.
Printed by Galya Basol Kochav on 1/5/2026 10:54:24 AM. Copyright © 2026 National Comprehensive Cancer Network, Inc. All Rights Reserved.

79. Tong MJ, Rosinski AA, Huynh CT, et al. Long-term survival after surveillance and treatment in patients with chronic viral hepatitis and hepatocellular carcinoma. Hepatol Commun 2017;1:595–608. Available at: https://www.ncbi.nlm.nih.gov/pubmed/29404481.

80. Pathologic diagnosis of early hepatocellular carcinoma: a report of the international consensus group for hepatocellular neoplasia. Hepatology 2009;49:658–664. Available at: http://www.ncbi.nlm.nih.gov/pubmed/19177576.

81. Lok AS, Sterling RK, Everhart JE, et al. Des-gamma-carboxy prothrombin and alpha-fetoprotein as biomarkers for the early detection of hepatocellular carcinoma. Gastroenterology 2010;138:493–502. Available at: http://www.ncbi.nlm.nih.gov/pubmed/19852963.

82. Tangkijvanich P, Anukulkarnkusol N, Suwangool P, et al. Clinical characteristics and prognosis of hepatocellular carcinoma: analysis based on serum alpha-fetoprotein levels. J Clin Gastroenterol 2000;31:302–308. Available at: http://www.ncbi.nlm.nih.gov/pubmed/11129271.

83. Tzartzeva K, Obi J, Rich NE, et al. Surveillance imaging and alpha fetoprotein for early detection of hepatocellular carcinoma in patients with cirrhosis: a meta-analysis. Gastroenterology 2018;154:1706–1718. Available at: https://www.ncbi.nlm.nih.gov/pubmed/29425931.

84. Arrieta O, Cacho B, Morales-Espinosa D, et al. The progressive elevation of alpha fetoprotein for the diagnosis of hepatocellular carcinoma in patients with liver cirrhosis. BMC Cancer 2007;7:28. Available at: https://www.ncbi.nlm.nih.gov/pubmed/17288606.

85. Sharma B, John S. Hepatic Cirrhosis. [Updated 2022 Oct 31]. In: StatPearls [Internet]. Treasure Island (FL): StatPearls Publishing; 2025 Jan-. Available from: https://www.ncbi.nlm.nih.gov/books/NBK482419/.

86. Liver imaging reporting & data system website. Available at: https://www.acr.org/Clinical-Resources/Clinical-Tools-and-Reference/Reporting-and-Data-Systems/LI-RADS. Accessed July 30, 2025.

87. Ioannou GN. HCC surveillance after SVR in patients with F3/F4 fibrosis. J Hepatol 2021;74:458–465. Available at: https://www.ncbi.nlm.nih.gov/pubmed/33303216.

88. Luo JC, Hwang SJ, Wu JC, et al. Clinical characteristics and prognosis of hepatocellular carcinoma patients with paraneoplastic syndromes. Hepatogastroenterology 2002;49:1315–1319. Available at: http://www.ncbi.nlm.nih.gov/pubmed/12239934.

89. Gera S, Ettel M, Acosta-Gonzalez G, Xu R. Clinical features, histology, and histogenesis of combined hepatocellular-cholangiocarcinoma. World J Hepatol 2017;9:300–309. Available at: https://www.ncbi.nlm.nih.gov/pubmed/28293379.

90. O'Connor K, Walsh JC, Schaeffer DF. Combined hepatocellular-cholangiocarcinoma (cHCC-CC): a distinct entity. Ann Hepatol 2014;13:317–322. Available at: https://www.ncbi.nlm.nih.gov/pubmed/24756005.

91. Li DB, Si XY, Wang SJ, Zhou YM. Long-term outcomes of combined hepatocellular-cholangiocarcinoma after hepatectomy or liver transplantation: A systematic review and meta-analysis. Hepatobiliary Pancreat Dis Int 2019;18:12–18. Available at: https://www.ncbi.nlm.nih.gov/pubmed/30442549.

92. Li R, Yang D, Tang CL, et al. Combined hepatocellular carcinoma and cholangiocarcinoma (biphenotypic) tumors: clinical characteristics, imaging features of contrast-enhanced ultrasound and computed tomography. BMC Cancer 2016;16:158. Available at: https://www.ncbi.nlm.nih.gov/pubmed/26917546.

93. Kassahun WT, Hauss J. Management of combined hepatocellular and cholangiocarcinoma. Int J Clin Pract 2008;62:1271–1278. Available at: https://www.ncbi.nlm.nih.gov/pubmed/18284443.

94. Yano Y, Yamamoto J, Kosuge T, et al. Combined hepatocellular and cholangiocarcinoma: a clinicopathologic study of 26 resected cases. Jpn J Clin Oncol 2003;33:283–287. Available at: https://www.ncbi.nlm.nih.gov/pubmed/12913082.

Version 2.2025 © 2025 National Comprehensive Cancer Network© (NCCN©), All rights reserved. NCCN Guidelines® and this illustration may not be reproduced in any form without the express written permission of NCCN.

PLEASE NOTE that use of this NCCN Content is governed by the End-User License Agreement, and you MAY NOT distribute this Content or use it with any artificial intelligence model or tool.
Printed by Galya Basol Kochav on 1/5/2026 10:54:24 AM. Copyright © 2026 National Comprehensive Cancer Network, Inc. All Rights Reserved.

95. Yin X, Zhang BH, Qiu SJ, et al. Combined hepatocellular carcinoma and cholangiocarcinoma: clinical features, treatment modalities, and prognosis. Ann Surg Oncol 2012;19:2869–2876. Available at: https://www.ncbi.nlm.nih.gov/pubmed/22451237.

96. Breedis C, Young G. The blood supply of neoplasms in the liver. Am J Pathol 1954;30:969–977. Available at: http://www.ncbi.nlm.nih.gov/pubmed/13197542.

97. Marrero JA, Hussain HK, Nghiem HV, et al. Improving the prediction of hepatocellular carcinoma in cirrhotic patients with an arterially-enhancing liver mass. Liver Transpl 2005;11:281–289. Available at: http://www.ncbi.nlm.nih.gov/pubmed/15719410.

98. Miller G, Schwartz LH, D'Angelica M. The use of imaging in the diagnosis and staging of hepatobiliary malignancies. Surg Oncol Clin N Am 2007;16:343–368. Available at: http://www.ncbi.nlm.nih.gov/pubmed/17560517.

99. Forner A, Vilana R, Ayuso C, et al. Diagnosis of hepatic nodules 20 mm or smaller in cirrhosis: Prospective validation of the noninvasive diagnostic criteria for hepatocellular carcinoma. Hepatology 2008;47:97–104. Available at: http://www.ncbi.nlm.nih.gov/pubmed/18069697.

100. Choi JY, Lee JM, Sirlin CB. CT and MR imaging diagnosis and staging of hepatocellular carcinoma: part II. Extracellular agents, hepatobiliary agents, and ancillary imaging features. Radiology 2014;273:30–50. Available at: https://www.ncbi.nlm.nih.gov/pubmed/25247563.

101. Tang A, Bashir MR, Corwin MT, et al. Evidence supporting LI-RADS major features for CT- and MR imaging-based diagnosis of hepatocellular carcinoma: a systematic review. Radiology 2018;286:29–48. Available at: https://www.ncbi.nlm.nih.gov/pubmed/29166245.

102. Dietrich CF, Nolsoe CP, Barr RG, et al. Guidelines and good clinical practice recommendations for contrast-enhanced ultrasound (CEUS) in the liver-update 2020 WFUMB in cooperation with EFSUMB, AFSUMB, AIUM, and FLAUS. Ultrasound Med Biol 2020;46:2579–2604. Available at: https://www.ncbi.nlm.nih.gov/pubmed/32713788.

103. Chou R, Cuevas C, Fu R, et al. Imaging techniques for the diagnosis of hepatocellular carcinoma: a systematic review and meta-analysis. Ann Intern Med 2015;162:697–711. Available at: https://www.ncbi.nlm.nih.gov/pubmed/25984845.

104. Colli A, Fraquelli M, Casazza G, et al. Accuracy of ultrasonography, spiral CT, magnetic resonance, and alpha-fetoprotein in diagnosing hepatocellular carcinoma: a systematic review. Am J Gastroenterol 2006;101:513–523. Available at: https://www.ncbi.nlm.nih.gov/pubmed/16542288.

105. Sun DW, An L, Wei F, et al. Prognostic significance of parameters from pretreatment (18)F-FDG PET in hepatocellular carcinoma: a meta-analysis. Abdom Radiol (NY) 2016;41:33–41. Available at: https://www.ncbi.nlm.nih.gov/pubmed/26830609.

106. Lin CY, Chen JH, Liang JA, et al. 18F-FDG PET or PET/CT for detecting extrahepatic metastases or recurrent hepatocellular carcinoma: a systematic review and meta-analysis. Eur J Radiol 2012;81:2417–2422. Available at: https://www.ncbi.nlm.nih.gov/pubmed/21899970.

107. Park JW, Kim JH, Kim SK, et al. A prospective evaluation of 18F-FDG and 11C-acetate PET/CT for detection of primary and metastatic hepatocellular carcinoma. J Nucl Med 2008;49:1912–1921. Available at: https://www.ncbi.nlm.nih.gov/pubmed/18997056.

108. Lee YJ, Lee JM, Lee JS, et al. Hepatocellular carcinoma: diagnostic performance of multidetector CT and MR imaging-a systematic review and meta-analysis. Radiology 2015;275:97–109. Available at: http://www.ncbi.nlm.nih.gov/pubmed/25559230.

109. Roberts LR, Sirlin CB, Zaiem F, et al. Imaging for the diagnosis of hepatocellular carcinoma: A systematic review and meta-analysis. Hepatology 2018;67:401–421. Available at: https://www.ncbi.nlm.nih.gov/pubmed/28859233.

Version 2.2025 © 2025 National Comprehensive Cancer Network© (NCCN©), All rights reserved. NCCN Guidelines® and this illustration may not be reproduced in any form without the express written permission of NCCN.

PLEASE NOTE that use of this NCCN Content is governed by the End-User License Agreement, and you MAY NOT distribute this Content or use it with any artificial intelligence model or tool.
Printed by Galya Basol Kochav on 1/5/2026 10:54:24 AM. Copyright © 2026 National Comprehensive Cancer Network, Inc. All Rights Reserved.

110. Kierans AS, Kang SK, Rosenkrantz AB. The diagnostic performance of dynamic contrast-enhanced MR imaging for detection of small hepatocellular carcinoma measuring up to 2 cm: a meta-analysis. Radiology 2016;278:82–94. Available at: https://www.ncbi.nlm.nih.gov/pubmed/26098460.

111. Sangiovanni A, Manini MA, Iavarone M, et al. The diagnostic and economic impact of contrast imaging techniques in the diagnosis of small hepatocellular carcinoma in cirrhosis. Gut 2010;59:638–644. Available at: http://www.ncbi.nlm.nih.gov/pubmed/19951909.

112. Schellhaas B, Wildner D, Pfeifer L, et al. LI-RADS-CEUS - proposal for a contrast-enhanced ultrasound algorithm for the diagnosis of hepatocellular carcinoma in high-risk populations. Ultraschall Med 2016;37:627–634. Available at: https://www.ncbi.nlm.nih.gov/pubmed/27486793.

113. Campos JT, Sirlin CB, Choi JY. Focal hepatic lesions in Gd-EOB-DTPA enhanced MRI: The atlas. Insights Imaging 2012;3:451–474. Available at: https://www.ncbi.nlm.nih.gov/pubmed/22700119.

114. Min JH, Lee MW, Park HS, et al. Interobserver variability and diagnostic performance of gadoxetic acid-enhanced MRI for predicting microvascular invasion in hepatocellular carcinoma. Radiology 2020;297:573–581. Available at: https://www.ncbi.nlm.nih.gov/pubmed/32990512.

115. Welle CL, Guglielmo FF, Venkatesh SK. MRI of the liver: Choosing the right contrast agent. Abdom Radiol (NY) 2020;45:384–392. Available at: https://www.ncbi.nlm.nih.gov/pubmed/31392396.

116. Zech CJ, Ba-Ssalamah A, Berg T, et al. Consensus report from the 8th International Forum for Liver Magnetic Resonance Imaging. Eur Radiol 2020;30:370–382. Available at: https://www.ncbi.nlm.nih.gov/pubmed/31385048.

117. Chang TT, Sawhney R, Monto A, et al. Implementation of a multidisciplinary treatment team for hepatocellular cancer at a Veterans Affairs Medical Center improves survival. HPB (Oxford) 2008;10:405–411. Available at: https://www.ncbi.nlm.nih.gov/pubmed/19088925.

118. Yopp AC, Mansour JC, Beg MS, et al. Establishment of a multidisciplinary hepatocellular carcinoma clinic is associated with improved clinical outcome. Ann Surg Oncol 2014;21:1287–1295. Available at: https://www.ncbi.nlm.nih.gov/pubmed/24318095.

119. Agarwal PD, Phillips P, Hillman L, et al. Multidisciplinary management of hepatocellular carcinoma improves access to therapy and patient survival. J Clin Gastroenterol 2017;51:845–849. Available at: https://www.ncbi.nlm.nih.gov/pubmed/28877082.

120. Serper M, Taddei TH, Mehta R, et al. Association of provider specialty and multidisciplinary care with hepatocellular carcinoma treatment and mortality. Gastroenterology 2017;152:1954–1964. Available at: https://www.ncbi.nlm.nih.gov/pubmed/28283421.

121. Farinati F, Marino D, De Giorgio M, et al. Diagnostic and prognostic role of alpha-fetoprotein in hepatocellular carcinoma: both or neither? Am J Gastroenterol 2006;101:524–532. Available at: http://www.ncbi.nlm.nih.gov/pubmed/16542289.

122. Trevisani F, D'Intino PE, Morselli-Labate AM, et al. Serum alpha-fetoprotein for diagnosis of hepatocellular carcinoma in patients with chronic liver disease: influence of HBsAg and anti-HCV status. J Hepatol 2001;34:570–575. Available at: http://www.ncbi.nlm.nih.gov/pubmed/11394657.

123. Gregory JJ, Jr., Finlay JL. Alpha-fetoprotein and beta-human chorionic gonadotropin: their clinical significance as tumour markers. Drugs 1999;57:463–467. Available at: http://www.ncbi.nlm.nih.gov/pubmed/10235686.

124. Torzilli G, Minagawa M, Takayama T, et al. Accurate preoperative evaluation of liver mass lesions without fine-needle biopsy. Hepatology 1999;30:889–893. Available at: http://www.ncbi.nlm.nih.gov/pubmed/10498639.

Version 2.2025 © 2025 National Comprehensive Cancer Network© (NCCN©), All rights reserved. NCCN Guidelines® and this illustration may not be reproduced in any form without the express written permission of NCCN.

PLEASE NOTE that use of this NCCN Content is governed by the End-User License Agreement, and you MAY NOT distribute this Content or use it with any artificial intelligence model or tool.
Printed by Galya Basol Kochav on 1/5/2026 10:54:24 AM. Copyright © 2026 National Comprehensive Cancer Network, Inc. All Rights Reserved.

125. Levy I, Greig PD, Gallinger S, et al. Resection of hepatocellular carcinoma without preoperative tumor biopsy. Ann Surg 2001;234:206–209. Available at: http://www.ncbi.nlm.nih.gov/pubmed/11505066.

126. Lok AS, Lai CL. alpha-Fetoprotein monitoring in Chinese patients with chronic hepatitis B virus infection: role in the early detection of hepatocellular carcinoma. Hepatology 1989;9:110–115. Available at: http://www.ncbi.nlm.nih.gov/pubmed/2461890.

127. Bialecki ES, Di Bisceglie AM. Diagnosis of hepatocellular carcinoma. HPB (Oxford) 2005;7:26–34. Available at: https://www.ncbi.nlm.nih.gov/pubmed/18333158.

128. Debruyne EN, Delanghe JR. Diagnosing and monitoring hepatocellular carcinoma with alpha-fetoprotein: new aspects and applications. Clin Chim Acta 2008;395:19–26. Available at: http://www.ncbi.nlm.nih.gov/pubmed/18538135.

129. Durazo FA, Blatt LM, Corey WG, et al. Des-gamma-carboxyprothrombin, alpha-fetoprotein and AFP-L3 in patients with chronic hepatitis, cirrhosis and hepatocellular carcinoma. J Gastroenterol Hepatol 2008;23:1541–1548. Available at: http://www.ncbi.nlm.nih.gov/pubmed/18422961.

130. Marrero JA, Feng Z, Wang Y, et al. Alpha-fetoprotein, des-gamma carboxyprothrombin, and lectin-bound alpha-fetoprotein in early hepatocellular carcinoma. Gastroenterology 2009;137:110–118. Available at: http://www.ncbi.nlm.nih.gov/pubmed/19362088.

131. Johnson PJ, Pirrie SJ, Cox TF, et al. The detection of hepatocellular carcinoma using a prospectively developed and validated model based on serological biomarkers. Cancer Epidemiol Biomarkers Prev 2014;23:144–153. Available at: https://www.ncbi.nlm.nih.gov/pubmed/24220911.

132. Berhane S, Toyoda H, Tada T, et al. Role of the GALAD and BALAD-2 serologic models in diagnosis of hepatocellular carcinoma and prediction of survival in patients. Clin Gastroenterol Hepatol 2016;14:875–886.e876. Available at: https://www.ncbi.nlm.nih.gov/pubmed/26775025.

133. Yang JD, Addissie BD, Mara KC, et al. GALAD score for hepatocellular carcinoma detection in comparison with liver ultrasound and proposal of GALADUS score. Cancer Epidemiol Biomarkers Prev 2019;28:531–538. Available at: https://www.ncbi.nlm.nih.gov/pubmed/30464023.

134. Best J, Bechmann LP, Sowa JP, et al. GALAD score detects early hepatocellular carcinoma in an international cohort of patients with nonalcoholic steatohepatitis. Clin Gastroenterol Hepatol 2020;18:728–735.e724. Available at: https://www.ncbi.nlm.nih.gov/pubmed/31712073.

135. Chalasani NP, Porter K, Bhattacharya A, et al. Validation of a novel multitarget blood test shows high sensitivity to detect early stage hepatocellular carcinoma. Clin Gastroenterol Hepatol 2022;20:173–182.e177. Available at: https://www.ncbi.nlm.nih.gov/pubmed/34391922.

136. Singal AG, Haaland B, Parikh ND, et al. Comparison of a multitarget blood test to ultrasound and alpha-fetoprotein for hepatocellular carcinoma surveillance: Results of a network meta-analysis. Hepatol Commun 2022;6:2925–2936. Available at: https://www.ncbi.nlm.nih.gov/pubmed/35945907.

137. Chhatwal J, Samur S, Yang JD, et al. Effectiveness of HCC surveillance programs using multitarget blood test: A modeling study. Hepatol Commun 2023;7. Available at: https://www.ncbi.nlm.nih.gov/pubmed/37204402.

138. Pomfret EA, Washburn K, Wald C, et al. Report of a national conference on liver allocation in patients with hepatocellular carcinoma in the United States. Liver Transpl 2010;16:262–278. Available at: https://www.ncbi.nlm.nih.gov/pubmed/20209641.

139. DeLeve LD, Valla DC, Garcia-Tsao G. Vascular disorders of the liver. Hepatology 2009;49:1729–1764. Available at: https://www.ncbi.nlm.nih.gov/pubmed/19399912.

140. Malaguarnera G, Paladina I, Giordano M, et al. Serum markers of intrahepatic cholangiocarcinoma. Dis Markers 2013;34:219–228. Available at: https://www.ncbi.nlm.nih.gov/pubmed/23396291.

Version 2.2025 © 2025 National Comprehensive Cancer Network© (NCCN©), All rights reserved. NCCN Guidelines® and this illustration may not be reproduced in any form without the express written permission of NCCN.

PLEASE NOTE that use of this NCCN Content is governed by the End-User License Agreement, and you MAY NOT distribute this Content or use it with any artificial intelligence model or tool.
Printed by Galya Basol Kochav on 1/5/2026 10:54:24 AM. Copyright © 2026 National Comprehensive Cancer Network, Inc. All Rights Reserved.

141. Khan SA, Thomas HC, Davidson BR, Taylor-Robinson SD. Cholangiocarcinoma. Lancet 2005;366:1303–1314. Available at: https://www.ncbi.nlm.nih.gov/pubmed/16214602.

142. Childs A, Zakeri N, Ma YT, et al. Biopsy for advanced hepatocellular carcinoma: results of a multicentre UK audit. Br J Cancer 2021;125:1350–1355. Available at: https://www.ncbi.nlm.nih.gov/pubmed/34526664.

143. Stewart CJR, Coldewey J, Stewart IS. Comparison of fine needle aspiration cytology and needle core biopsy in the diagnosis of radiologically detected abdominal lesions. J Clin Pathol 2002;55:93–97. Available at: http://www.ncbi.nlm.nih.gov/pubmed/11865001.

144. Pupulim LF, Felce-Dachez M, Paradis V, et al. Algorithm for immediate cytologic diagnosis of hepatic tumors. AJR Am J Roentgenol 2008;190:208–212. Available at: http://www.ncbi.nlm.nih.gov/pubmed/18287414.

145. Asmis T, Balaa F, Scully L, et al. Diagnosis and management of hepatocellular carcinoma: results of a consensus meeting of The Ottawa Hospital Cancer Centre. Curr Oncol 2010;17:6–12. Available at: http://www.ncbi.nlm.nih.gov/pubmed/20404972.

146. Renshaw AA, Haja J, Wilbur DC, Miller TR. Fine-needle aspirates of adenocarcinoma/metastatic carcinoma that resemble hepatocellular carcinoma: correlating cytologic features and performance in the College of American Pathologists Nongynecologic Cytology Program. Arch Pathol Lab Med 2005;129:1217–1221. Available at: http://www.ncbi.nlm.nih.gov/pubmed/16196506.

147. Pawlik TM, Gleisner AL, Anders RA, et al. Preoperative assessment of hepatocellular carcinoma tumor grade using needle biopsy: implications for transplant eligibility. Ann Surg 2007;245:435–442. Available at: http://www.ncbi.nlm.nih.gov/pubmed/17435551.

148. Teufel A, Rodriguez I, Winzler C, et al. Clinical characterization of HCC/CCA mixed cancers in a population-based cohort. J Gastrointestin Liver Dis 2023;32:190–196. Available at: https://www.ncbi.nlm.nih.gov/pubmed/37345609.

149. Raevskaya O, Appelman H, Razumilava N. A contemporary approach to diagnosis and treatment of combined hepatocellular-cholangiocarcinoma. Curr Hepatol Rep 2020;19:478–485. Available at: https://www.ncbi.nlm.nih.gov/pubmed/33415066.

150. Tang Y, Wang L, Teng F, et al. The clinical characteristics and prognostic factors of combined hepatocellular carcinoma and cholangiocarcinoma, hepatocellular carcinoma and intrahepatic cholangiocarcinoma after surgical resection: A propensity score matching analysis. Int J Med Sci 2021;18:187–198. Available at: https://www.ncbi.nlm.nih.gov/pubmed/33390787.

151. Claasen M, Ivanics T, Beumer BR, et al. An international multicentre evaluation of treatment strategies for combined hepatocellular-cholangiocarcinoma. JHEP Rep 2023;5:100745. Available at: https://www.ncbi.nlm.nih.gov/pubmed/37234277.

152. Pomej K, Balcar L, Shmanko K, et al. Clinical characteristics and outcome of patients with combined hepatocellular-cholangiocarcinoma-a European multicenter cohort. ESMO Open 2023;8:100783. Available at: https://www.ncbi.nlm.nih.gov/pubmed/36753993.

153. Kelley RK, Ueno M, Yoo C, et al. Pembrolizumab in combination with gemcitabine and cisplatin compared with gemcitabine and cisplatin alone for patients with advanced biliary tract cancer (KEYNOTE-966): A randomised, double-blind, placebo-controlled, phase 3 trial. Lancet 2023;401:1853–1865. Available at: https://www.ncbi.nlm.nih.gov/pubmed/37075781.

154. Oh DY, Ruth He A, Qin S, et al. Durvalumab plus gemcitabine and cisplatin in advanced biliary tract cancer. NEJM Evid 2022;1:EVIDoa2200015. Available at: https://www.ncbi.nlm.nih.gov/pubmed/38319896.

155. Valle J, Wasan H, Palmer DH, et al. Cisplatin plus gemcitabine versus gemcitabine for biliary tract cancer. N Engl J Med 2010;362:1273–1281. Available at: http://www.ncbi.nlm.nih.gov/pubmed/20375404.

Version 2.2025 © 2025 National Comprehensive Cancer Network© (NCCN©), All rights reserved. NCCN Guidelines® and this illustration may not be reproduced in any form without the express written permission of NCCN.

PLEASE NOTE that use of this NCCN Content is governed by the End-User License Agreement, and you MAY NOT distribute this Content or use it with any artificial intelligence model or tool.
Printed by Galya Basol Kochav on 1/5/2026 10:54:24 AM. Copyright © 2026 National Comprehensive Cancer Network, Inc. All Rights Reserved.

156. Abou-Alfa GK, Lau G, Kudo M, et al. Tremelimumab plus durvalumab in unresectable hepatocellular carcinoma. NEJM Evid 2022;1:EVIDoa2100070. Available at: https://evidence.nejm.org/doi/abs/10.1056/EVIDoa2100070

157. Finn RS, Ryoo BY, Merle P, et al. Pembrolizumab as second-line therapy in patients with advanced hepatocellular carcinoma in KEYNOTE-240: A randomized, double-blind, phase III trial. J Clin Oncol 2020;38:193–202. Available at: https://www.ncbi.nlm.nih.gov/pubmed/31790344.

158. Qin S, Chen Z, Fang W, et al. Pembrolizumab versus placebo as second-line therapy in patients from Asia with advanced hepatocellular carcinoma: A randomized, double-blind, phase III trial. J Clin Oncol 2023;41:1434–1443. Available at: https://www.ncbi.nlm.nih.gov/pubmed/36455168.

159. Zhu AX, Finn RS, Edeline J, et al. Pembrolizumab in patients with advanced hepatocellular carcinoma previously treated with sorafenib (KEYNOTE-224): a non-randomised, open-label phase 2 trial. Lancet Oncol 2018;19:940–952. Available at: https://www.ncbi.nlm.nih.gov/pubmed/29875066.

160. Yau T, Kang YK, Kim TY, et al. Efficacy and safety of nivolumab plus ipilimumab in patients with advanced hepatocellular carcinoma previously treated with sorafenib: The CheckMate 040 randomized clinical trial. JAMA Oncol 2020;6:e204564. Available at: https://www.ncbi.nlm.nih.gov/pubmed/33001135.

161. Klein O, Kee D, Nagrial A, et al. Evaluation of combination nivolumab and ipilimumab immunotherapy in patients with advanced biliary tract cancers: Subgroup analysis of a phase 2 nonrandomized clinical trial. JAMA Oncol 2020;6:1405–1409. Available at: https://www.ncbi.nlm.nih.gov/pubmed/32729929.

162. Bruix J, Qin S, Merle P, et al. Regorafenib for patients with hepatocellular carcinoma who progressed on sorafenib treatment (RESORCE): a randomised, double-blind, placebo-controlled, phase 3 trial. Lancet 2017;389:56–66. Available at: https://www.ncbi.nlm.nih.gov/pubmed/27932229.

163. Sun W, Patel A, Normolle D, et al. A phase 2 trial of regorafenib as a single agent in patients with chemotherapy-refractory, advanced, and metastatic biliary tract adenocarcinoma. Cancer 2019;125:902–909. Available at: https://www.ncbi.nlm.nih.gov/pubmed/30561756.

164. Ghany MG, Strader DB, Thomas DL, Seeff LB. Diagnosis, management, and treatment of hepatitis C: an update. Hepatology 2009;49:1335–1374. Available at: http://www.ncbi.nlm.nih.gov/pubmed/19330875.

165. Katyal S, Oliver JH, Peterson MS, et al. Extrahepatic metastases of hepatocellular carcinoma. Radiology 2000;216:698–703. Available at: http://www.ncbi.nlm.nih.gov/pubmed/10966697.

166. Natsuizaka M, Omura T, Akaike T, et al. Clinical features of hepatocellular carcinoma with extrahepatic metastases. J Gastroenterol Hepatol 2005;20:1781–1787. Available at: http://www.ncbi.nlm.nih.gov/pubmed/16246200.

167. Harding JJ, Abu-Zeinah G, Chou JF, et al. Frequency, morbidity, and mortality of bone metastases in advanced hepatocellular carcinoma. J Natl Compr Canc Netw 2018;16:50–58. Available at: https://www.ncbi.nlm.nih.gov/pubmed/29295881.

168. Dodd GD, 3rd, Baron RL, Oliver JH, 3rd, et al. Enlarged abdominal lymph nodes in end-stage cirrhosis: CT-histopathologic correlation in 507 patients. Radiology 1997;203:127–130. Available at: http://www.ncbi.nlm.nih.gov/pubmed/9122379.

169. Cooper GS, Bellamy P, Dawson NV, et al. A prognostic model for patients with end-stage liver disease. Gastroenterology 1997;113:1278–1288. Available at: http://www.ncbi.nlm.nih.gov/pubmed/9322523.

170. Banerjee R, Pavlides M, Tunnicliffe EM, et al. Multiparametric magnetic resonance for the non-invasive diagnosis of liver disease. J Hepatol 2014;60:69–77. Available at: https://www.ncbi.nlm.nih.gov/pubmed/24036007.

Version 2.2025 © 2025 National Comprehensive Cancer Network© (NCCN©), All rights reserved. NCCN Guidelines® and this illustration may not be reproduced in any form without the express written permission of NCCN.

PLEASE NOTE that use of this NCCN Content is governed by the End-User License Agreement, and you MAY NOT distribute this Content or use it with any artificial intelligence model or tool.
Printed by Galya Basol Kochav on 1/5/2026 10:54:24 AM. Copyright © 2026 National Comprehensive Cancer Network, Inc. All Rights Reserved.

171. Beyer C, Hutton C, Andersson A, et al. Comparison between magnetic resonance and ultrasound-derived indicators of hepatic steatosis in a pooled NAFLD cohort. PLoS One 2021;16:e0249491. Available at: https://www.ncbi.nlm.nih.gov/pubmed/33793651.

172. Imajo K, Tetlow L, Dennis A, et al. Quantitative multiparametric magnetic resonance imaging can aid non-alcoholic steatohepatitis diagnosis in a Japanese cohort. World J Gastroenterol 2021;27:609–623. Available at: https://www.ncbi.nlm.nih.gov/pubmed/33642832.

173. Pavlides M, Banerjee R, Tunnicliffe EM, et al. Multiparametric magnetic resonance imaging for the assessment of non-alcoholic fatty liver disease severity. Liver Int 2017;37:1065–1073. Available at: https://www.ncbi.nlm.nih.gov/pubmed/27778429.

174. Andersson A, Kelly M, Imajo K, et al. Clinical utility of magnetic resonance imaging biomarkers for identifying nonalcoholic steatohepatitis patients at high risk of progression: A multicenter pooled data and meta-analysis. Clin Gastroenterol Hepatol 2022;20:2451–2461.e2453. Available at: https://www.ncbi.nlm.nih.gov/pubmed/34626833.

175. Bruix J, Castells A, Bosch J, et al. Surgical resection of hepatocellular carcinoma in cirrhotic patients: prognostic value of preoperative portal pressure. Gastroenterology 1996;111:1018–1022. Available at: http://www.ncbi.nlm.nih.gov/pubmed/8831597.

176. Groszmann RJ, Wongcharatrawee S. The hepatic venous pressure gradient: anything worth doing should be done right. Hepatology 2004;39:280–282. Available at: http://www.ncbi.nlm.nih.gov/pubmed/14767976.

177. Boyer TD. Changing clinical practice with measurements of portal pressure. Hepatology 2004;39:283–285. Available at: http://www.ncbi.nlm.nih.gov/pubmed/14767977.

178. Thalheimer U, Mela M, Patch D, Burroughs AK. Targeting portal pressure measurements: a critical reappraisal. Hepatology 2004;39:286–290. Available at: http://www.ncbi.nlm.nih.gov/pubmed/14767978.

179. Kamath PS, Wiesner RH, Malinchoc M, et al. A model to predict survival in patients with end-stage liver disease. Hepatology 2001;33:464–470. Available at: http://www.ncbi.nlm.nih.gov/pubmed/11172350.

180. Malinchoc M, Kamath PS, Gordon FD, et al. A model to predict poor survival in patients undergoing transjugular intrahepatic portosystemic shunts. Hepatology 2000;31:864–871. Available at: http://www.ncbi.nlm.nih.gov/pubmed/10733541.

181. Martin AP, Bartels M, Hauss J, Fangmann J. Overview of the MELD score and the UNOS adult liver allocation system. Transplant Proc 2007;39:3169–3174. Available at: http://www.ncbi.nlm.nih.gov/pubmed/18089345.

182. Cholongitas E, Papatheodoridis GV, Vangeli M, et al. Systematic review: The model for end-stage liver disease--should it replace Child-Pugh's classification for assessing prognosis in cirrhosis? Aliment Pharmacol Ther 2005;22:1079–1089. Available at: http://www.ncbi.nlm.nih.gov/pubmed/16305721.

183. Saxena V, Lai JC. Kidney failure and liver allocation: Current practices and potential improvements. Adv Chronic Kidney Dis 2015;22:391–398. Available at: https://www.ncbi.nlm.nih.gov/pubmed/26311601.

184. Johnson PJ, Pinato DJ, Kalyuzhnyy A, Toyoda H. Breaking the Child-Pugh dogma in hepatocellular carcinoma. J Clin Oncol 2022;40:2078–2082. Available at: https://www.ncbi.nlm.nih.gov/pubmed/35344390.

185. Johnson PJ, Berhane S, Kagebayashi C, et al. Assessment of liver function in patients with hepatocellular carcinoma: a new evidence-based approach-the ALBI grade. J Clin Oncol 2015;33:550–558. Available at: https://www.ncbi.nlm.nih.gov/pubmed/25512453.

186. Oikonomou T, Goulis L, Doumtsis P, et al. ALBI and PALBI grades are associated with the outcome of patients with stable decompensated cirrhosis. Ann Hepatol 2019;18:126–136. Available at: https://www.ncbi.nlm.nih.gov/pubmed/31113581.

Version 2.2025 © 2025 National Comprehensive Cancer Network© (NCCN©), All rights reserved. NCCN Guidelines® and this illustration may not be reproduced in any form without the express written permission of NCCN.

PLEASE NOTE that use of this NCCN Content is governed by the End-User License Agreement, and you MAY NOT distribute this Content or use it with any artificial intelligence model or tool.
Printed by Galya Basol Kochav on 1/5/2026 10:54:24 AM. Copyright © 2026 National Comprehensive Cancer Network, Inc. All Rights Reserved.

187. Fan ST. Liver functional reserve estimation: state of the art and relevance for local treatments: the Eastern perspective. J Hepatobiliary Pancreat Sci 2010;17:380–384. Available at: http://www.ncbi.nlm.nih.gov/pubmed/19865790.

188. Fan ST, Lai EC, Lo CM, et al. Hospital mortality of major hepatectomy for hepatocellular carcinoma associated with cirrhosis. Arch Surg 1995;130:198–203. Available at: http://www.ncbi.nlm.nih.gov/pubmed/7848092.

189. Kudo M, Izumi N, Kokudo N, et al. Management of hepatocellular carcinoma in Japan: Consensus-Based Clinical Practice Guidelines proposed by the Japan Society of Hepatology (JSH) 2010 updated version. Dig Dis 2011;29:339–364. Available at: http://www.ncbi.nlm.nih.gov/pubmed/21829027.

190. Bruix J, Sherman M, Llovet JM, et al. Clinical management of hepatocellular carcinoma. Conclusions of the Barcelona-2000 EASL conference. European Association for the Study of the Liver. J Hepatol 2001;35:421–430. Available at: http://www.ncbi.nlm.nih.gov/pubmed/11592607.

191. Dohmen K. Many staging systems for hepatocellular carcinoma: evolution from Child-Pugh, Okuda to SLiDe. J Gastroenterol Hepatol 2004;19:1227–1232. Available at: http://www.ncbi.nlm.nih.gov/pubmed/15482527.

192. Marrero JA, Fontana RJ, Barrat A, et al. Prognosis of hepatocellular carcinoma: comparison of 7 staging systems in an American cohort. Hepatology 2005;41:707–716. Available at: http://www.ncbi.nlm.nih.gov/pubmed/15795889.

193. Pugh RN, Murray-Lyon IM, Dawson JL, et al. Transection of the oesophagus for bleeding oesophageal varices. Br J Surg 1973;60:646–649. Available at: http://www.ncbi.nlm.nih.gov/pubmed/4541913.

194. Amin MB, ed AJCC Cancer Staging Manual. In: Cancer AJCo, ed (ed 8th). Chicago, IL: Springer; 2017.

195. Okuda K, Ohtsuki T, Obata H, et al. Natural history of hepatocellular carcinoma and prognosis in relation to treatment. Study of 850 patients. Cancer 1985;56:918–928. Available at: http://www.ncbi.nlm.nih.gov/pubmed/2990661.

196. Chevret S, Trinchet JC, Mathieu D, et al. A new prognostic classification for predicting survival in patients with hepatocellular carcinoma. Groupe d'Etude et de Traitement du Carcinome Hepatocellulaire. J Hepatol 1999;31:133–141. Available at: http://www.ncbi.nlm.nih.gov/pubmed/10424293.

197. Leung TWT, Tang AMY, Zee B, et al. Construction of the Chinese University Prognostic Index for hepatocellular carcinoma and comparison with the TNM staging system, the Okuda staging system, and the Cancer of the Liver Italian Program staging system: a study based on 926 patients. Cancer 2002;94:1760–1769. Available at: http://www.ncbi.nlm.nih.gov/pubmed/11920539.

198. Kudo M, Chung H, Osaki Y. Prognostic staging system for hepatocellular carcinoma (CLIP score): its value and limitations, and a proposal for a new staging system, the Japan Integrated Staging Score (JIS score). J Gastroenterol 2003;38:207–215. Available at: http://www.ncbi.nlm.nih.gov/pubmed/12673442.

199. A new prognostic system for hepatocellular carcinoma: a retrospective study of 435 patients: the Cancer of the Liver Italian Program (CLIP) investigators. Hepatology 1998;28:751–755. Available at: http://www.ncbi.nlm.nih.gov/pubmed/9731568.

200. Reig M, Forner A, Rimola J, et al. BCLC strategy for prognosis prediction and treatment recommendation: The 2022 update. J Hepatol 2022;76:681–693. Available at: https://www.ncbi.nlm.nih.gov/pubmed/34801630.

201. Omagari K, Honda S, Kadokawa Y, et al. Preliminary analysis of a newly proposed prognostic scoring system (SLiDe score) for hepatocellular carcinoma. J Gastroenterol Hepatol 2004;19:805–811. Available at: http://www.ncbi.nlm.nih.gov/pubmed/15209629.

Version 2.2025 © 2025 National Comprehensive Cancer Network© (NCCN©), All rights reserved. NCCN Guidelines® and this illustration may not be reproduced in any form without the express written permission of NCCN.

PLEASE NOTE that use of this NCCN Content is governed by the End-User License Agreement, and you MAY NOT distribute this Content or use it with any artificial intelligence model or tool.
Printed by Galya Basol Kochav on 1/5/2026 10:54:24 AM. Copyright © 2026 National Comprehensive Cancer Network, Inc. All Rights Reserved.

202. Huo T-I, Lin H-C, Huang Y-H, et al. The model for end-stage liver disease-based Japan Integrated Scoring system may have a better predictive ability for patients with hepatocellular carcinoma undergoing locoregional therapy. Cancer 2006;107:141–148. Available at: http://www.ncbi.nlm.nih.gov/pubmed/16708358.

203. Limquiaco JL, Wong GLH, Wong VWS, et al. Evaluation of model for end stage liver disease (MELD)-based systems as prognostic index for hepatocellular carcinoma. J Gastroenterol Hepatol 2009;24:63–69. Available at: http://www.ncbi.nlm.nih.gov/pubmed/19054256.

204. Nanashima A, Sumida Y, Abo T, et al. Modified Japan Integrated Staging is currently the best available staging system for hepatocellular carcinoma patients who have undergone hepatectomy. J Gastroenterol 2006;41:250–256. Available at: http://www.ncbi.nlm.nih.gov/pubmed/16699859.

205. Bruix J, Sherman M. Management of hepatocellular carcinoma. Hepatology 2005;42:1208–1236. Available at: http://www.ncbi.nlm.nih.gov/pubmed/16250051.

206. Wang J-H, Changchien C-S, Hu T-H, et al. The efficacy of treatment schedules according to Barcelona Clinic Liver Cancer staging for hepatocellular carcinoma - Survival analysis of 3892 patients. Eur J Cancer 2008;44:1000–1006. Available at: http://www.ncbi.nlm.nih.gov/pubmed/18337087.

207. Kamarajah SK, Frankel TL, Sonnenday C, et al. Critical evaluation of the American Joint Commission on Cancer (AJCC) 8th edition staging system for patients with hepatocellular carcinoma (HCC): A Surveillance, Epidemiology, End Results (SEER) analysis. J Surg Oncol 2018;117:644–650. Available at: https://www.ncbi.nlm.nih.gov/pubmed/29127719.

208. Vauthey J-N, Ribero D, Abdalla EK, et al. Outcomes of liver transplantation in 490 patients with hepatocellular carcinoma: validation of a uniform staging after surgical treatment. J Am Coll Surg 2007;204:1016–1027. Available at: http://www.ncbi.nlm.nih.gov/pubmed/17481532.

209. Huitzil-Melendez FD, Capanu M, O'Reilly EM, et al. Advanced hepatocellular carcinoma: which staging systems best predict prognosis? J Clin Oncol 2010;28:2889–2895. Available at: http://www.ncbi.nlm.nih.gov/pubmed/20458042.

210. Cho YK, Chung JW, Kim JK, et al. Comparison of 7 staging systems for patients with hepatocellular carcinoma undergoing transarterial chemoembolization. Cancer 2008;112:352–361. Available at: http://www.ncbi.nlm.nih.gov/pubmed/18008352.

211. Collette S, Bonnetain F, Paoletti X, et al. Prognosis of advanced hepatocellular carcinoma: comparison of three staging systems in two French clinical trials. Ann Oncol 2008;19:1117–1126. Available at: http://www.ncbi.nlm.nih.gov/pubmed/18303031.

212. Cabibbo G, Enea M, Attanasio M, et al. A meta-analysis of survival rates of untreated patients in randomized clinical trials of hepatocellular carcinoma. Hepatology 2010;51:1274–1283. Available at: http://www.ncbi.nlm.nih.gov/pubmed/20112254.

213. Guglielmi A, Ruzzenente A, Pachera S, et al. Comparison of seven staging systems in cirrhotic patients with hepatocellular carcinoma in a cohort of patients who underwent radiofrequency ablation with complete response. Am J Gastroenterol 2008;103:597–604. Available at: http://www.ncbi.nlm.nih.gov/pubmed/17970836.

214. Vitale A, Morales RR, Zanus G, et al. Barcelona Clinic Liver Cancer staging and transplant survival benefit for patients with hepatocellular carcinoma: a multicentre, cohort study. The Lancet Oncology 2011;12:654–662. Available at: http://www.ncbi.nlm.nih.gov/pubmed/21684210.

215. Cho CS, Gonen M, Shia J, et al. A novel prognostic nomogram is more accurate than conventional staging systems for predicting survival after resection of hepatocellular carcinoma. J Am Coll Surg 2008;206:281–291. Available at: http://www.ncbi.nlm.nih.gov/pubmed/18222381.

216. Wang YY, Xiang BD, Ma L, et al. Development and validation of a nomogram to preoperatively estimate post-hepatectomy liver dysfunction

Version 2.2025 © 2025 National Comprehensive Cancer Network© (NCCN©), All rights reserved. NCCN Guidelines® and this illustration may not be reproduced in any form without the express written permission of NCCN.

PLEASE NOTE that use of this NCCN Content is governed by the End-User License Agreement, and you MAY NOT distribute this Content or use it with any artificial intelligence model or tool.
Printed by Galya Basol Kochav on 1/5/2026 10:54:24 AM. Copyright © 2026 National Comprehensive Cancer Network, Inc. All Rights Reserved.

risk and long-term survival in patients with hepatocellular carcinoma. Ann Surg 2021;274:e1209–e1217. Available at: https://www.ncbi.nlm.nih.gov/pubmed/32097166.

217. Nathan H, Schulick RD, Choti MA, Pawlik TM. Predictors of survival after resection of early hepatocellular carcinoma. Ann Surg 2009;249:799–805. Available at: http://www.ncbi.nlm.nih.gov/pubmed/19387322.

218. Nathan H, Mentha G, Marques HP, et al. Comparative performances of staging systems for early hepatocellular carcinoma. HPB (Oxford) 2009;11:382–390. Available at: http://www.ncbi.nlm.nih.gov/pubmed/19768142.

219. Truty MJ, Vauthey J-N. Surgical resection of high-risk hepatocellular carcinoma: patient selection, preoperative considerations, and operative technique. Ann Surg Oncol 2010;17:1219–1225. Available at: http://www.ncbi.nlm.nih.gov/pubmed/20405326.

220. Pawlik TM, Poon RT, Abdalla EK, et al. Critical appraisal of the clinical and pathologic predictors of survival after resection of large hepatocellular carcinoma. Arch Surg 2005;140:450–457. Available at: http://www.ncbi.nlm.nih.gov/pubmed/15897440.

221. Chok KS, Ng KK, Poon RT, et al. Impact of postoperative complications on long-term outcome of curative resection for hepatocellular carcinoma. Br J Surg 2009;96:81–87. Available at: http://www.ncbi.nlm.nih.gov/pubmed/19065644.

222. Kianmanesh R, Regimbeau JM, Belghiti J. Selective approach to major hepatic resection for hepatocellular carcinoma in chronic liver disease. Surg Oncol Clin N Am 2003;12:51–63. Available at: http://www.ncbi.nlm.nih.gov/pubmed/12735129.

223. Llovet JM, Fuster J, Bruix J. Intention-to-treat analysis of surgical treatment for early hepatocellular carcinoma: resection versus transplantation. Hepatology 1999;30:1434–1440. Available at: http://www.ncbi.nlm.nih.gov/pubmed/10573522.

224. Poon RT-P, Fan ST, Lo CM, et al. Long-term survival and pattern of recurrence after resection of small hepatocellular carcinoma in patients with preserved liver function: implications for a strategy of salvage transplantation. Ann Surg 2002;235:373–382. Available at: http://www.ncbi.nlm.nih.gov/pubmed/11882759.

225. Seo DD, Lee HC, Jang MK, et al. Preoperative portal vein embolization and surgical resection in patients with hepatocellular carcinoma and small future liver remnant volume: comparison with transarterial chemoembolization. Ann Surg Oncol 2007;14:3501–3509. Available at: http://www.ncbi.nlm.nih.gov/pubmed/17899289.

226. Cassese G, Han HS, Lee B, et al. The role of minimally invasive surgery in the treatment of HCC. Hepatoma Res 2022;8:26. Available at: https://hrjournal.net/article/view/4864.

227. Wei AC, Tung-Ping Poon R, Fan ST, Wong J. Risk factors for perioperative morbidity and mortality after extended hepatectomy for hepatocellular carcinoma. Br J Surg 2003;90:33–41. Available at: http://www.ncbi.nlm.nih.gov/pubmed/12520572.

228. Faber W, Stockmann M, Schirmer C, et al. Significant impact of patient age on outcome after liver resection for HCC in cirrhosis. Eur J Surg Oncol 2014;40:208–213. Available at: https://www.ncbi.nlm.nih.gov/pubmed/24275202.

229. Ribero D, Curley SA, Imamura H, et al. Selection for resection of hepatocellular carcinoma and surgical strategy: indications for resection, evaluation of liver function, portal vein embolization, and resection. Ann Surg Oncol 2008;15:986–992. Available at: http://www.ncbi.nlm.nih.gov/pubmed/18236112.

230. Berzigotti A, Reig M, Abraldes JG, et al. Portal hypertension and the outcome of surgery for hepatocellular carcinoma in compensated cirrhosis: a systematic review and meta-analysis. Hepatology 2015;61:526–536. Available at: https://www.ncbi.nlm.nih.gov/pubmed/25212123.

231. Santambrogio R, Kluger MD, Costa M, et al. Hepatic resection for hepatocellular carcinoma in patients with Child-Pugh's A cirrhosis: is

Version 2.2025 © 2025 National Comprehensive Cancer Network© (NCCN©), All rights reserved. NCCN Guidelines® and this illustration may not be reproduced in any form without the express written permission of NCCN.

PLEASE NOTE that use of this NCCN Content is governed by the End-User License Agreement, and you MAY NOT distribute this Content or use it with any artificial intelligence model or tool.
Printed by Galya Basol Kochav on 1/5/2026 10:54:24 AM. Copyright © 2026 National Comprehensive Cancer Network, Inc. All Rights Reserved.

clinical evidence of portal hypertension a contraindication? HPB (Oxford) 2013;15:78–84. Available at: https://www.ncbi.nlm.nih.gov/pubmed/23216782.

232. Tsai TJ, Chau GY, Lui WY, et al. Clinical significance of microscopic tumor venous invasion in patients with resectable hepatocellular carcinoma. Surgery 2000;127:603–608. Available at: http://www.ncbi.nlm.nih.gov/pubmed/10840353.

233. Abdalla EK, Denys A, Hasegawa K, et al. Treatment of large and advanced hepatocellular carcinoma. Ann Surg Oncol 2008;15:979–985. Available at: http://www.ncbi.nlm.nih.gov/pubmed/18236115.

234. Jonas S, Bechstein WO, Steinmuller T, et al. Vascular invasion and histopathologic grading determine outcome after liver transplantation for hepatocellular carcinoma in cirrhosis. Hepatology 2001;33:1080–1086. Available at: http://www.ncbi.nlm.nih.gov/pubmed/11343235.

235. Vauthey J-N, Lauwers GY, Esnaola NF, et al. Simplified staging for hepatocellular carcinoma. J Clin Oncol 2002;20:1527–1536. Available at: http://www.ncbi.nlm.nih.gov/pubmed/11896101.

236. Glantzounis GK, Paliouras A, Stylianidi MC, et al. The role of liver resection in the management of intermediate and advanced stage hepatocellular carcinoma. A systematic review. Eur J Surg Oncol 2018;44:195–208. Available at: https://www.ncbi.nlm.nih.gov/pubmed/29258719.

237. Yamakado K, Nakatsuka A, Takaki H, et al. Early-stage hepatocellular carcinoma: radiofrequency ablation combined with chemoembolization versus hepatectomy. Radiology 2008;247:260–266. Available at: http://www.ncbi.nlm.nih.gov/pubmed/18305190.

238. Kubota K, Makuuchi M, Kusaka K, et al. Measurement of liver volume and hepatic functional reserve as a guide to decision-making in resectional surgery for hepatic tumors. Hepatology 1997;26:1176–1181. Available at: http://www.ncbi.nlm.nih.gov/pubmed/9362359.

239. Kishi Y, Abdalla EK, Chun YS, et al. Three hundred and one consecutive extended right hepatectomies: evaluation of outcome based on systematic liver volumetry. Ann Surg 2009;250:540–548. Available at: https://www.ncbi.nlm.nih.gov/pubmed/19730239.

240. Zorzi D, Laurent A, Pawlik TM, et al. Chemotherapy-associated hepatotoxicity and surgery for colorectal liver metastases. Br J Surg 2007;94:274–286. Available at: https://www.ncbi.nlm.nih.gov/pubmed/17315288.

241. Boubaddi M, Marichez A, Adam JP, et al. Comprehensive review of future liver remnant (FLR) assessment and hypertrophy techniques before major hepatectomy: How to assess and manage the FLR. Ann Surg Oncol 2024;31:9205–9220. Available at: https://www.ncbi.nlm.nih.gov/pubmed/39230854.

242. Entezari P, Gabr A, Kennedy K, et al. Radiation lobectomy: An overview of concept and applications, technical considerations, outcomes. Semin Intervent Radiol 2021;38:419–424. Available at: https://www.ncbi.nlm.nih.gov/pubmed/34629708.

243. Glantzounis GK, Tokidis E, Basourakos SP, et al. The role of portal vein embolization in the surgical management of primary hepatobiliary cancers. A systematic review. Eur J Surg Oncol 2017;43:32–41. Available at: https://www.ncbi.nlm.nih.gov/pubmed/27283892.

244. Brouquet A, Andreou A, Shindoh J, Vauthey J-N. Methods to improve resectability of hepatocellular carcinoma. In: Schlag PM, Senn H-J, eds. Recent Results in Cancer Research. Vol. 190: Springer; 2013:57–67.

245. Vouche M, Lewandowski RJ, Atassi R, et al. Radiation lobectomy: Time-dependent analysis of future liver remnant volume in unresectable liver cancer as a bridge to resection. J Hepatol 2013;59:1029–1036. Available at: https://www.ncbi.nlm.nih.gov/pubmed/23811303.

246. Chapelle T, Op de Beeck B, Roeyen G, et al. Measuring future liver remnant function prior to hepatectomy may guide the indication for portal vein occlusion and avoid posthepatectomy liver failure: a prospective

Version 2.2025 © 2025 National Comprehensive Cancer Network© (NCCN©), All rights reserved. NCCN Guidelines® and this illustration may not be reproduced in any form without the express written permission of NCCN.

PLEASE NOTE that use of this NCCN Content is governed by the End-User License Agreement, and you MAY NOT distribute this Content or use it with any artificial intelligence model or tool.
Printed by Galya Basol Kochav on 1/5/2026 10:54:24 AM. Copyright © 2026 National Comprehensive Cancer Network, Inc. All Rights Reserved.

interventional study. HPB (Oxford) 2017;19:108–117. Available at: https://www.ncbi.nlm.nih.gov/pubmed/27956027.

247. Martel G, Cieslak KP, Huang R, et al. Comparison of techniques for volumetric analysis of the future liver remnant: implications for major hepatic resections. HPB (Oxford) 2015;17:1051–1057. Available at: https://www.ncbi.nlm.nih.gov/pubmed/26373675.

248. Leung U, Simpson AL, Araujo RL, et al. Remnant growth rate after portal vein embolization is a good early predictor of post-hepatectomy liver failure. J Am Coll Surg 2014;219:620–630. Available at: https://www.ncbi.nlm.nih.gov/pubmed/25158914.

249. Roayaie S, Jibara G, Tabrizian P, et al. The role of hepatic resection in the treatment of hepatocellular cancer. Hepatology 2015;62:440–451. Available at: https://www.ncbi.nlm.nih.gov/pubmed/25678263.

250. Marron TU, Fiel MI, Hamon P, et al. Neoadjuvant cemiplimab for resectable hepatocellular carcinoma: A single-arm, open-label, phase 2 trial. Lancet Gastroenterol Hepatol 2022;7:219–229. Available at: https://www.ncbi.nlm.nih.gov/pubmed/35065058.

251. Kaseb AO, Hasanov E, Cao HST, et al. Perioperative nivolumab monotherapy versus nivolumab plus ipilimumab in resectable hepatocellular carcinoma: A randomised, open-label, phase 2 trial. Lancet Gastroenterol Hepatol 2022;7:208–218. Available at: https://www.ncbi.nlm.nih.gov/pubmed/35065057.

252. Bruix J, Takayama T, Mazzaferro V, et al. Adjuvant sorafenib for hepatocellular carcinoma after resection or ablation (STORM): a phase 3, randomised, double-blind, placebo-controlled trial. Lancet Oncol 2015;16:1344–1354. Available at: https://www.ncbi.nlm.nih.gov/pubmed/26361969.

253. Li SH, Mei J, Cheng Y, et al. Postoperative adjuvant hepatic arterial infusion chemotherapy with FOLFOX in hepatocellular carcinoma with microvascular invasion: A multicenter, phase III, randomized study. J Clin Oncol 2023;41:1898–1908. Available at: https://www.ncbi.nlm.nih.gov/pubmed/36525610.

254. Qi YP, Zhong JH, Liang ZY, et al. Adjuvant transarterial chemoembolization for patients with hepatocellular carcinoma involving microvascular invasion. Am J Surg 2019;217:739–744. Available at: https://www.ncbi.nlm.nih.gov/pubmed/30103903.

255. Chen ZH, Zhang XP, Zhou TF, et al. Adjuvant transarterial chemoembolization improves survival outcomes in hepatocellular carcinoma with microvascular invasion: A systematic review and meta-analysis. Eur J Surg Oncol 2019;45:2188–2196. Available at: https://www.ncbi.nlm.nih.gov/pubmed/31256949.

256. Yin J, Li N, Han Y, et al. Effect of antiviral treatment with nucleotide/nucleoside analogs on postoperative prognosis of hepatitis B virus-related hepatocellular carcinoma: a two-stage longitudinal clinical study. J Clin Oncol 2013;31:3647–3655. Available at: http://www.ncbi.nlm.nih.gov/pubmed/24002499.

257. Huang G, Lau WY, Wang ZG, et al. Antiviral therapy improves postoperative survival in patients with hepatocellular carcinoma: a randomized controlled trial. Ann Surg 2015;261:56–66. Available at: https://www.ncbi.nlm.nih.gov/pubmed/25072444.

258. Xu J, Li J, Chen J, Liu ZJ. Effect of adjuvant interferon therapy on hepatitis b/c virus-related hepatocellular carcinoma after curative therapy - meta-analysis. Adv Clin Exp Med 2015;24:331–340. Available at: http://www.ncbi.nlm.nih.gov/pubmed/25931368.

259. Xia BW, Zhang YC, Wang J, et al. Efficacy of antiviral therapy with nucleotide/nucleoside analogs after curative treatment for patients with hepatitis B virus-related hepatocellular carcinoma: A systematic review and meta-analysis. Clin Res Hepatol Gastroenterol 2015;39:458–468. Available at: https://www.ncbi.nlm.nih.gov/pubmed/25650304.

260. Manthravadi S, Paleti S, Pandya P. Impact of sustained viral response postcurative therapy of hepatitis C-related hepatocellular carcinoma: a systematic review and meta-analysis. Int J Cancer 2017;140:1042–1049. Available at: https://www.ncbi.nlm.nih.gov/pubmed/27861842.

Version 2.2025 © 2025 National Comprehensive Cancer Network© (NCCN©), All rights reserved. NCCN Guidelines® and this illustration may not be reproduced in any form without the express written permission of NCCN.

PLEASE NOTE that use of this NCCN Content is governed by the End-User License Agreement, and you MAY NOT distribute this Content or use it with any artificial intelligence model or tool.
Printed by Galya Basol Kochav on 1/5/2026 10:54:24 AM. Copyright © 2026 National Comprehensive Cancer Network, Inc. All Rights Reserved.

261. Huang DQ, Hoang JK, Kamal R, et al. Antiviral therapy utilization and 10-year outcomes in resected hepatitis B virus- and hepatitis C virus-related hepatocellular carcinoma. J Clin Oncol 2024;42:790–799. Available at: https://www.ncbi.nlm.nih.gov/pubmed/38175991.

262. Reig M, Boix L, Bruix J. The impact of direct antiviral agents on the development and recurrence of hepatocellular carcinoma. Liver Int 2017;37 Suppl 1:136–139. Available at: https://www.ncbi.nlm.nih.gov/pubmed/28052619.

263. Torres HA, Shigle TL, Hammoudi N, et al. The oncologic burden of hepatitis C virus infection: A clinical perspective. CA Cancer J Clin 2017;67:411–431. Available at: https://www.ncbi.nlm.nih.gov/pubmed/28683174.

264. Conti F, Buonfiglioli F, Scuteri A, et al. Early occurrence and recurrence of hepatocellular carcinoma in HCV-related cirrhosis treated with direct-acting antivirals. J Hepatol 2016;65:727–733. Available at: https://www.ncbi.nlm.nih.gov/pubmed/27349488.

265. Furtado R, Crawford M, Sandroussi C. Systematic review and meta-analysis of adjuvant i(131) lipiodol after excision of hepatocellular carcinoma. Ann Surg Oncol 2014;21:2700–2707. Available at: https://www.ncbi.nlm.nih.gov/pubmed/24743904.

266. Zhu GQ, Shi KQ, Yu HJ, et al. Optimal adjuvant therapy for resected hepatocellular carcinoma: a systematic review with network meta-analysis. Oncotarget 2015;6:18151–18161. Available at: https://www.ncbi.nlm.nih.gov/pubmed/26061709.

267. Lee JH, Lee JH, Lim YS, et al. Adjuvant immunotherapy with autologous cytokine-induced killer cells for hepatocellular carcinoma. Gastroenterology 2015;148:1383–1391.e1386. Available at: https://www.ncbi.nlm.nih.gov/pubmed/25747273.

268. Qin S, Chen M, Cheng AL, et al. Atezolizumab plus bevacizumab versus active surveillance in patients with resected or ablated high-risk hepatocellular carcinoma (IMbrave050): A randomised, open-label, multicentre, phase 3 trial. Lancet 2023;402:1835–1847. Available at: https://www.ncbi.nlm.nih.gov/pubmed/37871608.

269. Yopp A, Kudo M, Chen M, et al. Updated efficacy and safety data from IMbrave050: Phase III study of adjuvant atezolizumab (atezo) + bevacizumab (bev) vs active surveillance in patients (pts) with resected or ablated high-risk hepatocellular carcinoma (HCC) [abstract]. Ann Oncol 2024;35:Abstract LBA39. Available at: https://www.annalsofoncology.org/article/S0923-7534(24)03859-6/fulltext.

270. Watt KD, Pedersen RA, Kremers WK, et al. Evolution of causes and risk factors for mortality post-liver transplant: results of the NIDDK long-term follow-up study. Am J Transplant 2010;10:1420–1427. Available at: https://www.ncbi.nlm.nih.gov/pubmed/20486907.

271. Mazzaferro V, Regalia E, Doci R, et al. Liver transplantation for the treatment of small hepatocellular carcinomas in patients with cirrhosis. N Engl J Med 1996;334:693–699. Available at: http://www.ncbi.nlm.nih.gov/pubmed/8594428.

272. Mazzaferro V, Chun YS, Poon RTP, et al. Liver transplantation for hepatocellular carcinoma. Ann Surg Oncol 2008;15:1001–1007. Available at: http://www.ncbi.nlm.nih.gov/pubmed/18236119.

273. OPTN/UNOS policy notice modification to hepatocellular carcinoma (HCC) extension criteria. Available at: https://optn.transplant.hrsa.gov/media/2411/modification-to-hcc-auto-approval-criteria_policy-notice.pdf.

274. Cha CH, Ruo L, Fong Y, et al. Resection of hepatocellular carcinoma in patients otherwise eligible for transplantation. Ann Surg 2003;238:315–321; discussion 321–323. Available at: http://www.ncbi.nlm.nih.gov/pubmed/14501497.

275. Poon RT, Fan ST, Lo CM, et al. Difference in tumor invasiveness in cirrhotic patients with hepatocellular carcinoma fulfilling the Milan criteria treated by resection and transplantation: impact on long-term survival. Ann Surg 2007;245:51–58. Available at: http://www.ncbi.nlm.nih.gov/pubmed/17197965.

Version 2.2025 © 2025 National Comprehensive Cancer Network© (NCCN©), All rights reserved. NCCN Guidelines® and this illustration may not be reproduced in any form without the express written permission of NCCN.

PLEASE NOTE that use of this NCCN Content is governed by the End-User License Agreement, and you MAY NOT distribute this Content or use it with any artificial intelligence model or tool.
Printed by Galya Basol Kochav on 1/5/2026 10:54:24 AM. Copyright © 2026 National Comprehensive Cancer Network, Inc. All Rights Reserved.

276. Shah SA, Cleary SP, Tan JC, et al. An analysis of resection vs transplantation for early hepatocellular carcinoma: defining the optimal therapy at a single institution. Ann Surg Oncol 2007;14:2608–2614. Available at: http://www.ncbi.nlm.nih.gov/pubmed/17522942.

277. Facciuto ME, Koneru B, Rocca JP, et al. Surgical treatment of hepatocellular carcinoma beyond Milan criteria. Results of liver resection, salvage transplantation, and primary liver transplantation. Ann Surg Oncol 2008;15:1383–1391. Available at: http://www.ncbi.nlm.nih.gov/pubmed/18320284.

278. Organ Procurement and Transplantation Network. OPTN policy. Available at: https://optn.transplant.hrsa.gov/media/eavh5bf3/optn_policies.pdf.

279. Ioannou GN, Perkins JD, Carithers RL. Liver transplantation for hepatocellular carcinoma: impact of the MELD allocation system and predictors of survival. Gastroenterology 2008;134:1342–1351. Available at: http://www.ncbi.nlm.nih.gov/pubmed/18471511.

280. Volk ML, Vijan S, Marrero JA. A novel model measuring the harm of transplanting hepatocellular carcinoma exceeding Milan criteria. Am J Transplant 2008;8:839–846. Available at: http://www.ncbi.nlm.nih.gov/pubmed/18318783.

281. Duffy JP, Vardanian A, Benjamin E, et al. Liver transplantation criteria for hepatocellular carcinoma should be expanded: a 22-year experience with 467 patients at UCLA. Ann Surg 2007;246:502–509. Available at: http://www.ncbi.nlm.nih.gov/pubmed/17717454.

282. Yao FY, Ferrell L, Bass NM, et al. Liver transplantation for hepatocellular carcinoma: expansion of the tumor size limits does not adversely impact survival. Hepatology 2001;33:1394–1403. Available at: http://www.ncbi.nlm.nih.gov/pubmed/11391528.

283. Yao FY, Bass NM, Nikolai B, et al. Liver transplantation for hepatocellular carcinoma: analysis of survival according to the intention-to-treat principle and dropout from the waiting list. Liver Transpl 2002;8:873–883. Available at: http://www.ncbi.nlm.nih.gov/pubmed/12360427.

284. Volk M, Marrero JA. Liver transplantation for hepatocellular carcinoma: who benefits and who is harmed? Gastroenterology 2008;134:1612–1614. Available at: http://www.ncbi.nlm.nih.gov/pubmed/18471530.

285. Lee S-G, Hwang S, Moon D-B, et al. Expanded indication criteria of living donor liver transplantation for hepatocellular carcinoma at one large-volume center. Liver Transpl 2008;14:935–945. Available at: http://www.ncbi.nlm.nih.gov/pubmed/18581465.

286. Wan P, Xia Q, Zhang JJ, et al. Liver transplantation for hepatocellular carcinoma exceeding the Milan criteria: a single-center experience. J Cancer Res Clin Oncol 2014;140:341–348. Available at: http://www.ncbi.nlm.nih.gov/pubmed/24374832.

287. Duvoux C, Roudot-Thoraval F, Decaens T, et al. Liver transplantation for hepatocellular carcinoma: a model including alpha-fetoprotein improves the performance of Milan criteria. Gastroenterology 2012;143:986–994.e983; quiz e914–915. Available at: https://www.ncbi.nlm.nih.gov/pubmed/22750200.

288. Notarpaolo A, Layese R, Magistri P, et al. Validation of the AFP model as a predictor of HCC recurrence in patients with viral hepatitis-related cirrhosis who had received a liver transplant for HCC. J Hepatol 2017;66:552–559. Available at: https://www.ncbi.nlm.nih.gov/pubmed/27899297.

289. Mehta N, Heimbach J, Harnois DM, et al. Validation of a risk estimation of tumor recurrence after transplant (RETREAT) score for hepatocellular carcinoma recurrence after liver transplant. JAMA Oncol 2017;3:493–500. Available at: https://www.ncbi.nlm.nih.gov/pubmed/27838698.

290. Kim J, Ko ME, Nelson RA, et al. Increasing age and survival after orthotopic liver transplantation for patients with hepatocellular cancer. J Am Coll Surg 2014;218:431–438. Available at: https://www.ncbi.nlm.nih.gov/pubmed/24559955.

Version 2.2025 © 2025 National Comprehensive Cancer Network© (NCCN©), All rights reserved. NCCN Guidelines® and this illustration may not be reproduced in any form without the express written permission of NCCN.

PLEASE NOTE that use of this NCCN Content is governed by the End-User License Agreement, and you MAY NOT distribute this Content or use it with any artificial intelligence model or tool.
Printed by Galya Basol Kochav on 1/5/2026 10:54:24 AM. Copyright © 2026 National Comprehensive Cancer Network, Inc. All Rights Reserved.

291. Kozyreva ON, Chi D, Clark JW, et al. A multicenter retrospective study on clinical characteristics, treatment patterns, and outcome in elderly patients with hepatocellular carcinoma. Oncologist 2011;16:310–318. Available at: https://www.ncbi.nlm.nih.gov/pubmed/21349948.

292. Zhao LY, Huo RR, Xiang X, et al. Hepatic resection for elderly patients with hepatocellular carcinoma: a systematic review of more than 17,000 patients. Expert Rev Gastroenterol Hepatol 2018;12:1059–1068. Available at: https://www.ncbi.nlm.nih.gov/pubmed/30145919.

293. Fujiki M, Aucejo F, Kim R. General overview of neo-adjuvant therapy for hepatocellular carcinoma before liver transplantation: necessity or option? Liver Int 2011;31:1081–1089. Available at: http://www.ncbi.nlm.nih.gov/pubmed/22008644.

294. Xing M, Sakaria S, Dhanasekaran R, et al. Bridging locoregional therapy prolongs survival in patients listed for liver transplant with hepatocellular carcinoma. Cardiovasc Intervent Radiol 2017;40:410–420. Available at: https://www.ncbi.nlm.nih.gov/pubmed/27900445.

295. Llovet JM, Di Bisceglie AM, Bruix J, et al. Design and endpoints of clinical trials in hepatocellular carcinoma. J Natl Cancer Inst 2008;100:698–711. Available at: http://www.ncbi.nlm.nih.gov/pubmed/18477802.

296. Majno P, Giostra E, Mentha G. Management of hepatocellular carcinoma on the waiting list before liver transplantation: time for controlled trials? Liver Transpl 2007;13:S27–35. Available at: http://www.ncbi.nlm.nih.gov/pubmed/17969086.

297. Pompili M, Mirante VG, Rondinara G, et al. Percutaneous ablation procedures in cirrhotic patients with hepatocellular carcinoma submitted to liver transplantation: Assessment of efficacy at explant analysis and of safety for tumor recurrence. Liver Transpl 2005;11:1117–1126. Available at: http://www.ncbi.nlm.nih.gov/pubmed/16123960.

298. Mazzaferro V, Battiston C, Perrone S, et al. Radiofrequency ablation of small hepatocellular carcinoma in cirrhotic patients awaiting liver transplantation: a prospective study. Ann Surg 2004;240:900–909. Available at: http://www.ncbi.nlm.nih.gov/pubmed/15492574.

299. Yao FY, Bass NM, Nikolai B, et al. A follow-up analysis of the pattern and predictors of dropout from the waiting list for liver transplantation in patients with hepatocellular carcinoma: implications for the current organ allocation policy. Liver Transpl 2003;9:684–692. Available at: http://www.ncbi.nlm.nih.gov/pubmed/12827553.

300. DuBay DA, Sandroussi C, Kachura JR, et al. Radiofrequency ablation of hepatocellular carcinoma as a bridge to liver transplantation. HPB (Oxford) 2011;13:24–32. Available at: http://www.ncbi.nlm.nih.gov/pubmed/21159100.

301. Tsochatzis E, Garcovich M, Marelli L, et al. Transarterial embolization as neo-adjuvant therapy pretransplantation in patients with hepatocellular carcinoma. Liver Int 2013;33:944–949. Available at: http://www.ncbi.nlm.nih.gov/pubmed/23530918.

302. Llovet JM, Bruix J. Systematic review of randomized trials for unresectable hepatocellular carcinoma: Chemoembolization improves survival. Hepatology 2003;37:429–442. Available at: https://www.ncbi.nlm.nih.gov/pubmed/12540794.

303. Richard HM, Silberzweig JE, Mitty HA, et al. Hepatic arterial complications in liver transplant recipients treated with pretransplantation chemoembolization for hepatocellular carcinoma. Radiology 2000;214:775–779. Available at: http://www.ncbi.nlm.nih.gov/pubmed/10715045.

304. Graziadei IW, Sandmueller H, Waldenberger P, et al. Chemoembolization followed by liver transplantation for hepatocellular carcinoma impedes tumor progression while on the waiting list and leads to excellent outcome. Liver Transpl 2003;9:557–563. Available at: http://www.ncbi.nlm.nih.gov/pubmed/12783395.

305. Hayashi PH, Ludkowski M, Forman LM, et al. Hepatic artery chemoembolization for hepatocellular carcinoma in patients listed for liver

Version 2.2025 © 2025 National Comprehensive Cancer Network© (NCCN©), All rights reserved. NCCN Guidelines® and this illustration may not be reproduced in any form without the express written permission of NCCN.

PLEASE NOTE that use of this NCCN Content is governed by the End-User License Agreement, and you MAY NOT distribute this Content or use it with any artificial intelligence model or tool.
Printed by Galya Basol Kochav on 1/5/2026 10:54:24 AM. Copyright © 2026 National Comprehensive Cancer Network, Inc. All Rights Reserved.

transplantation. Am J Transplant 2004;4:782–787. Available at: http://www.ncbi.nlm.nih.gov/pubmed/15084175.

306. Nicolini D, Svegliati-Baroni G, Candelari R, et al. Doxorubicin-eluting bead vs conventional transcatheter arterial chemoembolization for hepatocellular carcinoma before liver transplantation. World J Gastroenterol 2013;19:5622–5632. Available at: http://www.ncbi.nlm.nih.gov/pubmed/24039354.

307. Kulik LM, Atassi B, van Holsbeeck L, et al. Yttrium-90 microspheres (TheraSphere) treatment of unresectable hepatocellular carcinoma: downstaging to resection, RFA and bridge to transplantation. J Surg Oncol 2006;94:572–586. Available at: http://www.ncbi.nlm.nih.gov/pubmed/17048240.

308. Sandroussi C, Dawson LA, Lee M, et al. Radiotherapy as a bridge to liver transplantation for hepatocellular carcinoma. Transpl Int 2010;23:299–306. Available at: http://www.ncbi.nlm.nih.gov/pubmed/19843294.

309. Lu L, Zeng J, Wen Z, et al. Transcatheter arterial chemoembolisation followed by three-dimensional conformal radiotherapy versus transcatheter arterial chemoembolisation alone for primary hepatocellular carcinoma in adults. Cochrane Database Syst Rev 2019;2:CD012244. Available at: https://www.ncbi.nlm.nih.gov/pubmed/30776082.

310. Kulik L, Heimbach JK, Zaiem F, et al. Therapies for patients with hepatocellular carcinoma awaiting liver transplantation: A systematic review and meta-analysis. Hepatology 2018;67:381–400. Available at: https://www.ncbi.nlm.nih.gov/pubmed/28859222.

311. Freeman RB, Steffick DE, Guidinger MK, et al. Liver and intestine transplantation in the United States, 1997-2006. Am J Transplant 2008;8:958–976. Available at: http://www.ncbi.nlm.nih.gov/pubmed/18336699.

312. Campos BD, Botha JF. Transplantation for hepatocellular carcinoma and cholangiocarcinoma. J Natl Compr Canc Netw 2009;7:409–416. Available at: http://www.ncbi.nlm.nih.gov/pubmed/19406041.

313. Toso C, Mentha G, Kneteman NM, Majno P. The place of downstaging for hepatocellular carcinoma. J Hepatol 2010;52:930–936. Available at: http://www.ncbi.nlm.nih.gov/pubmed/20385428.

314. Yao FY, Fidelman N. Reassessing the boundaries of liver transplantation for hepatocellular carcinoma: Where do we stand with tumor down-staging? Hepatology 2016;63:1014–1025. Available at: https://www.ncbi.nlm.nih.gov/pubmed/26560491.

315. Parikh ND, Waljee AK, Singal AG. Downstaging hepatocellular carcinoma: A systematic review and pooled analysis. Liver Transpl 2015;21:1142–1152. Available at: https://www.ncbi.nlm.nih.gov/pubmed/25981135.

316. Kardashian A, Florman SS, Haydel B, et al. Liver transplantation outcomes in a U.S. multicenter cohort of 789 patients with hepatocellular carcinoma presenting beyond Milan criteria. Hepatology 2020;72:2014–2028. Available at: https://www.ncbi.nlm.nih.gov/pubmed/32124453.

317. Ravaioli M, Grazi GL, Piscaglia F, et al. Liver transplantation for hepatocellular carcinoma: results of down-staging in patients initially outside the Milan selection criteria. Am J Transplant 2008;8:2547–2557. Available at: http://www.ncbi.nlm.nih.gov/pubmed/19032223.

318. Yao FY, Kerlan RK, Jr., Hirose R, et al. Excellent outcome following down-staging of hepatocellular carcinoma prior to liver transplantation: an intention-to-treat analysis. Hepatology 2008;48:819–827. Available at: http://www.ncbi.nlm.nih.gov/pubmed/18688876.

319. Chapman WC, Majella Doyle MB, Stuart JE, et al. Outcomes of neoadjuvant transarterial chemoembolization to downstage hepatocellular carcinoma before liver transplantation. Ann Surg 2008;248:617–625. Available at: http://www.ncbi.nlm.nih.gov/pubmed/18936575.

320. Lewandowski RJ, Kulik LM, Riaz A, et al. A comparative analysis of transarterial downstaging for hepatocellular carcinoma: chemoembolization versus radioembolization. Am J Transplant 2009;9:1920–1928. Available at: http://www.ncbi.nlm.nih.gov/pubmed/19552767.

Version 2.2025 © 2025 National Comprehensive Cancer Network© (NCCN©), All rights reserved. NCCN Guidelines® and this illustration may not be reproduced in any form without the express written permission of NCCN.

PLEASE NOTE that use of this NCCN Content is governed by the End-User License Agreement, and you MAY NOT distribute this Content or use it with any artificial intelligence model or tool.
Printed by Galya Basol Kochav on 1/5/2026 10:54:24 AM. Copyright © 2026 National Comprehensive Cancer Network, Inc. All Rights Reserved.

321. Yao FY, Mehta N, Flemming J, et al. Downstaging of hepatocellular cancer before liver transplant: long-term outcome compared to tumors within Milan criteria. Hepatology 2015;61:1968–1977. Available at: https://www.ncbi.nlm.nih.gov/pubmed/25689978.

322. De Luna W, Sze DY, Ahmed A, et al. Transarterial chemoinfusion for hepatocellular carcinoma as downstaging therapy and a bridge toward liver transplantation. Am J Transplant 2009;9:1158–1168. Available at: https://www.ncbi.nlm.nih.gov/pubmed/19344435.

323. Jang JW, You CR, Kim CW, et al. Benefit of downsizing hepatocellular carcinoma in a liver transplant population. Aliment Pharmacol Ther 2010;31:415–423. Available at: http://www.ncbi.nlm.nih.gov/pubmed/19821808.

324. Millonig G, Graziadei IW, Freund MC, et al. Response to preoperative chemoembolization correlates with outcome after liver transplantation in patients with hepatocellular carcinoma. Liver Transpl 2007;13:272–279. Available at: http://www.ncbi.nlm.nih.gov/pubmed/17256758.

325. Otto G, Herber S, Heise M, et al. Response to transarterial chemoembolization as a biological selection criterion for liver transplantation in hepatocellular carcinoma. Liver Transpl 2006;12:1260–1267. Available at: http://www.ncbi.nlm.nih.gov/pubmed/16826556.

326. Mazzaferro V, Citterio D, Bhoori S, et al. Liver transplantation in hepatocellular carcinoma after tumour downstaging (XXL): a randomised, controlled, phase 2b/3 trial. Lancet Oncol 2020;21:947–956. Available at: https://www.ncbi.nlm.nih.gov/pubmed/32615109.

327. Tabrizian P, Holzner ML, Mehta N, et al. Ten-year outcomes of liver transplant and downstaging for hepatocellular carcinoma. JAMA Surg 2022;157:779–788. Available at: https://www.ncbi.nlm.nih.gov/pubmed/35857294.

328. Eisenhauer EA, Therasse P, Bogaerts J, et al. New response evaluation criteria in solid tumours: revised RECIST guideline (version 1.1). Eur J Cancer 2009;45:228–247. Available at: http://www.ncbi.nlm.nih.gov/pubmed/19097774.

329. Duke E, Deng J, Ibrahim SM, et al. Agreement between competing imaging measures of response of hepatocellular carcinoma to yttrium-90 radioembolization. J Vasc Interv Radiol 2010;21:515–521. Available at: http://www.ncbi.nlm.nih.gov/pubmed/20172741.

330. Lencioni R, Llovet JM. Modified RECIST (mRECIST) assessment for hepatocellular carcinoma. Semin Liver Dis 2010;30:52–60. Available at: http://www.ncbi.nlm.nih.gov/pubmed/20175033.

331. Riaz A, Miller FH, Kulik LM, et al. Imaging response in the primary index lesion and clinical outcomes following transarterial locoregional therapy for hepatocellular carcinoma. JAMA 2010;303:1062–1069. Available at: http://www.ncbi.nlm.nih.gov/pubmed/20233824.

332. Sato Y, Watanabe H, Sone M, et al. Tumor response evaluation criteria for HCC (hepatocellular carcinoma) treated using TACE (transcatheter arterial chemoembolization): RECIST (response evaluation criteria in solid tumors) version 1.1 and mRECIST (modified RECIST): JIVROSG-0602. Ups J Med Sci 2013;118:16–22. Available at: https://www.ncbi.nlm.nih.gov/pubmed/23167460.

333. Takada J, Hidaka H, Nakazawa T, et al. Modified response evaluation criteria in solid tumors is superior to response evaluation criteria in solid tumors for assessment of responses to sorafenib in patients with advanced hepatocellular carcinoma. BMC Res Notes 2015;8:609. Available at: https://www.ncbi.nlm.nih.gov/pubmed/26502722.

334. Riaz A, Ryu RK, Kulik LM, et al. Alpha-fetoprotein response after locoregional therapy for hepatocellular carcinoma: oncologic marker of radiologic response, progression, and survival. J Clin Oncol 2009;27:5734–5742. Available at: http://www.ncbi.nlm.nih.gov/pubmed/19805671.

335. Livraghi T, Goldberg SN, Lazzaroni S, et al. Small hepatocellular carcinoma: treatment with radio-frequency ablation versus ethanol injection. Radiology 1999;210:655–661. Available at: http://www.ncbi.nlm.nih.gov/pubmed/10207464.

Version 2.2025 © 2025 National Comprehensive Cancer Network© (NCCN©), All rights reserved. NCCN Guidelines® and this illustration may not be reproduced in any form without the express written permission of NCCN.

PLEASE NOTE that use of this NCCN Content is governed by the End-User License Agreement, and you MAY NOT distribute this Content or use it with any artificial intelligence model or tool.
Printed by Galya Basol Kochav on 1/5/2026 10:54:24 AM. Copyright © 2026 National Comprehensive Cancer Network, Inc. All Rights Reserved.

336. Lencioni RA, Allgaier HP, Cioni D, et al. Small hepatocellular carcinoma in cirrhosis: randomized comparison of radio-frequency thermal ablation versus percutaneous ethanol injection. Radiology 2003;228:235–240. Available at: http://www.ncbi.nlm.nih.gov/pubmed/12759473.

337. Lin S-M, Lin C-J, Lin C-C, et al. Radiofrequency ablation improves prognosis compared with ethanol injection for hepatocellular carcinoma < or =4 cm. Gastroenterology 2004;127:1714–1723. Available at: http://www.ncbi.nlm.nih.gov/pubmed/15578509.

338. Lin SM, Lin CJ, Lin CC, et al. Randomised controlled trial comparing percutaneous radiofrequency thermal ablation, percutaneous ethanol injection, and percutaneous acetic acid injection to treat hepatocellular carcinoma of 3 cm or less. Gut 2005;54:1151–1156. Available at: http://www.ncbi.nlm.nih.gov/pubmed/16009687.

339. Shiina S, Teratani T, Obi S, et al. A randomized controlled trial of radiofrequency ablation with ethanol injection for small hepatocellular carcinoma. Gastroenterology 2005;129:122–130. Available at: http://www.ncbi.nlm.nih.gov/pubmed/16012942.

340. Brunello F, Veltri A, Carucci P, et al. Radiofrequency ablation versus ethanol injection for early hepatocellular carcinoma: A randomized controlled trial. Scand J Gastroenterol 2008;43:727–735. Available at: http://www.ncbi.nlm.nih.gov/pubmed/18569991.

341. Giorgio A, Di Sarno A, De Stefano G, et al. Percutaneous radiofrequency ablation of hepatocellular carcinoma compared to percutaneous ethanol injection in treatment of cirrhotic patients: an Italian randomized controlled trial. Anticancer Res 2011;31:2291–2295. Available at: http://www.ncbi.nlm.nih.gov/pubmed/21737654.

342. Weis S, Franke A, Mossner J, et al. Radiofrequency (thermal) ablation versus no intervention or other interventions for hepatocellular carcinoma. Cochrane Database Syst Rev 2013;12:CD003046. Available at: http://www.ncbi.nlm.nih.gov/pubmed/24357457.

343. Cho YK, Kim JK, Kim MY, et al. Systematic review of randomized trials for hepatocellular carcinoma treated with percutaneous ablation therapies. Hepatology 2009;49:453–459. Available at: http://www.ncbi.nlm.nih.gov/pubmed/19065676.

344. Orlando A, Leandro G, Olivo M, et al. Radiofrequency thermal ablation vs. percutaneous ethanol injection for small hepatocellular carcinoma in cirrhosis: meta-analysis of randomized controlled trials. Am J Gastroenterol 2009;104:514–524. Available at: http://www.ncbi.nlm.nih.gov/pubmed/19174803.

345. Germani G, Pleguezuelo M, Gurusamy K, et al. Clinical outcomes of radiofrequency ablation, percutaneous alcohol and acetic acid injection for hepatocelullar carcinoma: a meta-analysis. J Hepatol 2010;52:380–388. Available at: http://www.ncbi.nlm.nih.gov/pubmed/20149473.

346. Peng ZW, Zhang YJ, Chen MS, et al. Radiofrequency ablation as first-line treatment for small solitary hepatocellular carcinoma: long-term results. Eur J Surg Oncol 2010;36:1054–1060. Available at: http://www.ncbi.nlm.nih.gov/pubmed/20846819.

347. Shiina S, Tateishi R, Arano T, et al. Radiofrequency ablation for hepatocellular carcinoma: 10-year outcome and prognostic factors. Am J Gastroenterol 2012;107:569–577. Available at: http://www.ncbi.nlm.nih.gov/pubmed/22158026.

348. Brunello F, Cantamessa A, Gaia S, et al. Radiofrequency ablation: technical and clinical long-term outcomes for single hepatocellular carcinoma up to 30 mm. Eur J Gastroenterol Hepatol 2013;25:842–849. Available at: http://www.ncbi.nlm.nih.gov/pubmed/23442417.

349. Francica G, Saviano A, De Sio I, et al. Long-term effectiveness of radiofrequency ablation for solitary small hepatocellular carcinoma: a retrospective analysis of 363 patients. Dig Liver Dis 2013;45:336–341. Available at: http://www.ncbi.nlm.nih.gov/pubmed/23245589.

350. Huang G-T, Lee P-H, Tsang Y-M, et al. Percutaneous ethanol injection versus surgical resection for the treatment of small hepatocellular carcinoma: a prospective study. Ann Surg 2005;242:36–42. Available at: http://www.ncbi.nlm.nih.gov/pubmed/15973099.

Version 2.2025 © 2025 National Comprehensive Cancer Network© (NCCN©), All rights reserved. NCCN Guidelines® and this illustration may not be reproduced in any form without the express written permission of NCCN.

PLEASE NOTE that use of this NCCN Content is governed by the End-User License Agreement, and you MAY NOT distribute this Content or use it with any artificial intelligence model or tool.
Printed by Galya Basol Kochav on 1/5/2026 10:54:24 AM. Copyright © 2026 National Comprehensive Cancer Network, Inc. All Rights Reserved.

351. Chen M-S, Li J-Q, Zheng Y, et al. A prospective randomized trial comparing percutaneous local ablative therapy and partial hepatectomy for small hepatocellular carcinoma. Ann Surg 2006;243:321–328. Available at: http://www.ncbi.nlm.nih.gov/pubmed/16495695.

352. Huang J, Yan L, Cheng Z, et al. A randomized trial comparing radiofrequency ablation and surgical resection for HCC conforming to the Milan criteria. Ann Surg 2010;252:903–912. Available at: http://www.ncbi.nlm.nih.gov/pubmed/21107100.

353. Feng K, Yan J, Li X, et al. A randomized controlled trial of radiofrequency ablation and surgical resection in the treatment of small hepatocellular carcinoma. J Hepatol 2012;57:794–802. Available at: http://www.ncbi.nlm.nih.gov/pubmed/22634125.

354. Fang Y, Chen W, Liang X, et al. Comparison of long-term effectiveness and complications of radiofrequency ablation with hepatectomy for small hepatocellular carcinoma. J Gastroenterol Hepatol 2014;29:193–200. Available at: https://www.ncbi.nlm.nih.gov/pubmed/24224779.

355. Ng KKC, Chok KSH, Chan ACY, et al. Randomized clinical trial of hepatic resection versus radiofrequency ablation for early-stage hepatocellular carcinoma. Br J Surg 2017;104:1775–1784. Available at: https://www.ncbi.nlm.nih.gov/pubmed/29091283.

356. Feng Q, Chi Y, Liu Y, et al. Efficacy and safety of percutaneous radiofrequency ablation versus surgical resection for small hepatocellular carcinoma: a meta-analysis of 23 studies. J Cancer Res Clin Oncol 2015;141:1–9. Available at: http://www.ncbi.nlm.nih.gov/pubmed/24889505.

357. Jia JB, Zhang D, Ludwig JM, Kim HS. Radiofrequency ablation versus resection for hepatocellular carcinoma in patients with Child-Pugh A liver cirrhosis: a meta-analysis. Clin Radiol 2017;72:1066–1075. Available at: https://www.ncbi.nlm.nih.gov/pubmed/28851491.

358. Xu G, Qi F-Z, Zhang J-H, et al. Meta-analysis of surgical resection and radiofrequency ablation for early hepatocellular carcinoma. World J Surg Oncol 2012;10:163–163. Available at: http://www.ncbi.nlm.nih.gov/pubmed/22897815.

359. Xuan D, Wen W, Xu D, Jin T. Survival comparison between radiofrequency ablation and surgical resection for patients with small hepatocellular carcinoma: A systematic review and meta-analysis. Medicine (Baltimore) 2021;100:e24585. Available at: https://www.ncbi.nlm.nih.gov/pubmed/33607788.

360. Shin SW, Ahn KS, Kim SW, et al. Liver resection versus local ablation therapies for hepatocellular carcinoma within the Milan Criteria: A systematic review and meta-analysis. Ann Surg 2021;273:656–666. Available at: https://www.ncbi.nlm.nih.gov/pubmed/33074898.

361. Jia Z, Zhang H, Li N. Evaluation of clinical outcomes of radiofrequency ablation and surgical resection for hepatocellular carcinoma conforming to the Milan criteria: A systematic review and meta-analysis of recent randomized controlled trials. J Gastroenterol Hepatol 2021;36:1769–1777. Available at: https://www.ncbi.nlm.nih.gov/pubmed/33569810.

362. Cai H, Kong W, Zhou T, Qiu Y. Radiofrequency ablation versus reresection in treating recurrent hepatocellular carcinoma: a meta-analysis. Medicine (Baltimore) 2014;93:e122. Available at: https://www.ncbi.nlm.nih.gov/pubmed/25396332.

363. Yang Y, Yu H, Tan X, et al. Liver resection versus radiofrequency ablation for recurrent hepatocellular carcinoma: A systematic review and meta-analysis. Int J Hyperthermia 2021;38:875–886. Available at: https://www.ncbi.nlm.nih.gov/pubmed/34078221.

364. Livraghi T, Goldberg SN, Lazzaroni S, et al. Hepatocellular carcinoma: radio-frequency ablation of medium and large lesions. Radiology 2000;214:761–768. Available at: http://www.ncbi.nlm.nih.gov/pubmed/10715043.

365. Vivarelli M, Guglielmi A, Ruzzenente A, et al. Surgical resection versus percutaneous radiofrequency ablation in the treatment of

Version 2.2025 © 2025 National Comprehensive Cancer Network© (NCCN©), All rights reserved. NCCN Guidelines® and this illustration may not be reproduced in any form without the express written permission of NCCN.

PLEASE NOTE that use of this NCCN Content is governed by the End-User License Agreement, and you MAY NOT distribute this Content or use it with any artificial intelligence model or tool.
Printed by Galya Basol Kochav on 1/5/2026 10:54:24 AM. Copyright © 2026 National Comprehensive Cancer Network, Inc. All Rights Reserved.

hepatocellular carcinoma on cirrhotic liver. Ann Surg 2004;240:102–107. Available at: http://www.ncbi.nlm.nih.gov/pubmed/15213625.

366. Ruzzenente A, Guglielmi A, Sandri M, et al. Surgical resection versus local ablation for HCC on cirrhosis: results from a propensity case-matched study. J Gastrointest Surg 2012;16:301–311; discussion 311. Available at: http://www.ncbi.nlm.nih.gov/pubmed/22095524.

367. Yang D, Zhuang B, Wang Y, et al. Radiofrequency ablation versus hepatic resection for recurrent hepatocellular carcinoma: An updated meta-analysis. BMC Gastroenterol 2020;20:402. Available at: https://www.ncbi.nlm.nih.gov/pubmed/33246417.

368. Livraghi T, Meloni F, Di Stasi M, et al. Sustained complete response and complications rates after radiofrequency ablation of very early hepatocellular carcinoma in cirrhosis: Is resection still the treatment of choice? Hepatology 2008;47:82–89. Available at: http://www.ncbi.nlm.nih.gov/pubmed/18008357.

369. Peng ZW, Lin XJ, Zhang YJ, et al. Radiofrequency ablation versus hepatic resection for the treatment of hepatocellular carcinomas 2 cm or smaller: a retrospective comparative study. Radiology 2012;262:1022–1033. Available at: http://www.ncbi.nlm.nih.gov/pubmed/22357902.

370. Shibata T, Iimuro Y, Yamamoto Y, et al. Small hepatocellular carcinoma: comparison of radio-frequency ablation and percutaneous microwave coagulation therapy. Radiology 2002;223:331–337. Available at: http://www.ncbi.nlm.nih.gov/pubmed/11997534.

371. Ding J, Jing X, Liu J, et al. Comparison of two different thermal techniques for the treatment of hepatocellular carcinoma. Eur J Radiol 2013;82:1379–1384. Available at: http://www.ncbi.nlm.nih.gov/pubmed/23726122.

372. Groeschl RT, Pilgrim CHC, Hanna EM, et al. Microwave ablation for hepatic malignancies: a multiinstitutional analysis. Ann Surg 2013;259:1195–1200. Available at: http://www.ncbi.nlm.nih.gov/pubmed/24096760.

373. Zhang L, Wang N, Shen Q, et al. Therapeutic efficacy of percutaneous radiofrequency ablation versus microwave ablation for hepatocellular carcinoma. PLoS One 2013;8:e76119. Available at: http://www.ncbi.nlm.nih.gov/pubmed/24146824.

374. Shi J, Sun Q, Wang Y, et al. Comparison of microwave ablation and surgical resection for treatment of hepatocellular carcinomas conforming to Milan Criteria. J Gastroenterol Hepatol 2014;29:1500–1507. Available at: http://www.ncbi.nlm.nih.gov/pubmed/24628534.

375. Hsiao CY, Huang KW. Irreversible electroporation: a novel ultrasound-guided modality for non-thermal tumor ablation. J Med Ultrasound 2017;25:195–200. Available at: https://www.ncbi.nlm.nih.gov/pubmed/30065492.

376. Narayanan G, Froud T, Suthar R, Barbery K. Irreversible electroporation of hepatic malignancy. Semin Intervent Radiol 2013;30:67–73. Available at: https://www.ncbi.nlm.nih.gov/pubmed/24436519.

377. Lencioni R, Crocetti L, Narayanan G. Irreversible electroporation in the treatment of hepatocellular carcinoma. Tech Vasc Interv Radiol 2015;18:135–139. Available at: https://www.ncbi.nlm.nih.gov/pubmed/26365542.

378. Scheffer HJ, Nielsen K, de Jong MC, et al. Irreversible electroporation for nonthermal tumor ablation in the clinical setting: a systematic review of safety and efficacy. J Vasc Interv Radiol 2014;25:997–1011; quiz 1011. Available at: https://www.ncbi.nlm.nih.gov/pubmed/24656178.

379. Cheung W, Kavnoudias H, Roberts S, et al. Irreversible electroporation for unresectable hepatocellular carcinoma: initial experience and review of safety and outcomes. Technol Cancer Res Treat 2013;12:233–241. Available at: https://www.ncbi.nlm.nih.gov/pubmed/23369152.

380. Cannon R, Ellis S, Hayes D, et al. Safety and early efficacy of irreversible electroporation for hepatic tumors in proximity to vital

Version 2.2025 © 2025 National Comprehensive Cancer Network© (NCCN©), All rights reserved. NCCN Guidelines® and this illustration may not be reproduced in any form without the express written permission of NCCN.

PLEASE NOTE that use of this NCCN Content is governed by the End-User License Agreement, and you MAY NOT distribute this Content or use it with any artificial intelligence model or tool.
Printed by Galya Basol Kochav on 1/5/2026 10:54:24 AM. Copyright © 2026 National Comprehensive Cancer Network, Inc. All Rights Reserved.

structures. J Surg Oncol 2013;107:544–549. Available at: https://www.ncbi.nlm.nih.gov/pubmed/23090720.

381. Fruhling P, Nilsson A, Duraj F, et al. Single-center nonrandomized clinical trial to assess the safety and efficacy of irreversible electroporation (IRE) ablation of liver tumors in humans: Short to mid-term results. Eur J Surg Oncol 2017;43:751–757. Available at: https://www.ncbi.nlm.nih.gov/pubmed/28109674.

382. Liapi E, Geschwind J-FH. Intra-arterial therapies for hepatocellular carcinoma: where do we stand? Ann Surg Oncol 2010;17:1234–1246. Available at: http://www.ncbi.nlm.nih.gov/pubmed/20405328.

383. Rand T, Loewe C, Schoder M, et al. Arterial embolization of unresectable hepatocellular carcinoma with use of microspheres, lipiodol, and cyanoacrylate. Cardiovasc Intervent Radiol 2005;28:313–318. Available at: http://www.ncbi.nlm.nih.gov/pubmed/15886943.

384. Huang YH, Chen CH, Chang TT, et al. The role of transcatheter arterial embolization for patients with unresectable hepatocellular carcinoma: a nationwide, multicentre study evaluated by cancer stage. Aliment Pharmacol Ther 2005;21:687–694. Available at: http://www.ncbi.nlm.nih.gov/pubmed/15771754.

385. Maluccio MA, Covey AM, Porat LB, et al. Transcatheter arterial embolization with only particles for the treatment of unresectable hepatocellular carcinoma. J Vasc Interv Radiol 2008;19:862–869. Available at: http://www.ncbi.nlm.nih.gov/pubmed/18503900.

386. Bonomo G, Pedicini V, Monfardini L, et al. Bland embolization in patients with unresectable hepatocellular carcinoma using precise, tightly size-calibrated, anti-inflammatory microparticles: first clinical experience and one-year follow-up. Cardiovasc Intervent Radiol 2010;33:552–559. Available at: http://www.ncbi.nlm.nih.gov/pubmed/19957182.

387. Ramsey DE, Kernagis LY, Soulen MC, Geschwind J-FH. Chemoembolization of hepatocellular carcinoma. J Vasc Interv Radiol 2002;13:211–221. Available at: http://www.ncbi.nlm.nih.gov/pubmed/12354839.

388. Lo C-M, Ngan H, Tso W-K, et al. Randomized controlled trial of transarterial lipiodol chemoembolization for unresectable hepatocellular carcinoma. Hepatology 2002;35:1164–1171. Available at: http://www.ncbi.nlm.nih.gov/pubmed/11981766.

389. Llovet JM, Real MI, Montana X, et al. Arterial embolisation or chemoembolisation versus symptomatic treatment in patients with unresectable hepatocellular carcinoma: a randomised controlled trial. Lancet 2002;359:1734–1739. Available at: http://www.ncbi.nlm.nih.gov/pubmed/12049862.

390. Kong JY, Li SM, Fan HY, et al. Transarterial chemoembolization extends long-term survival in patients with unresectable hepatocellular carcinoma. Medicine (Baltimore) 2018;97:e11872. Available at: https://www.ncbi.nlm.nih.gov/pubmed/30113483.

391. Brown KT, Do RK, Gonen M, et al. Randomized trial of hepatic artery embolization for hepatocellular carcinoma using doxorubicin-eluting microspheres compared with embolization with microspheres alone. J Clin Oncol 2016;34:2046–2053. Available at: https://www.ncbi.nlm.nih.gov/pubmed/26834067.

392. Morse MA, Hanks BA, Suhocki P, et al. Improved time to progression for transarterial chemoembolization compared with transarterial embolization for patients with unresectable hepatocellular carcinoma. Clin Colorectal Cancer 2012;11:185–190. Available at: http://www.ncbi.nlm.nih.gov/pubmed/22280845.

393. Molinari M, Kachura JR, Dixon E, et al. Transarterial chemoembolisation for advanced hepatocellular carcinoma: results from a North American cancer centre. Clin Oncol (R Coll Radiol) 2006;18:684–692. Available at: http://www.ncbi.nlm.nih.gov/pubmed/17100154.

394. Llado L, Virgili J, Figueras J, et al. A prognostic index of the survival of patients with unresectable hepatocellular carcinoma after transcatheter arterial chemoembolization. Cancer 2000;88:50–57. Available at: http://www.ncbi.nlm.nih.gov/pubmed/10618605.

Version 2.2025 © 2025 National Comprehensive Cancer Network© (NCCN©), All rights reserved. NCCN Guidelines® and this illustration may not be reproduced in any form without the express written permission of NCCN.

PLEASE NOTE that use of this NCCN Content is governed by the End-User License Agreement, and you MAY NOT distribute this Content or use it with any artificial intelligence model or tool.
Printed by Galya Basol Kochav on 1/5/2026 10:54:24 AM. Copyright © 2026 National Comprehensive Cancer Network, Inc. All Rights Reserved.

395. Han K, Kim JH, Ko GY, et al. Treatment of hepatocellular carcinoma with portal venous tumor thrombosis: A comprehensive review. World J Gastroenterol 2016;22:407–416. Available at: https://www.ncbi.nlm.nih.gov/pubmed/26755886.

396. Leng JJ, Xu YZ, Dong JH. Efficacy of transarterial chemoembolization for hepatocellular carcinoma with portal vein thrombosis: a meta-analysis. ANZ J Surg 2016;86:816–820. Available at: https://www.ncbi.nlm.nih.gov/pubmed/25088384.

397. Kim W, Clark TW, Baum RA, Soulen MC. Risk factors for liver abscess formation after hepatic chemoembolization. J Vasc Interv Radiol 2001;12:965–968. Available at: http://www.ncbi.nlm.nih.gov/pubmed/11487677.

398. Mezhir JJ, Fong Y, Fleischer D, et al. Pyogenic abscess after hepatic artery embolization: a rare but potentially lethal complication. J Vasc Interv Radiol 2011;22:177–182. Available at: http://www.ncbi.nlm.nih.gov/pubmed/21195630.

399. Sergio A, Cristofori C, Cardin R, et al. Transcatheter arterial chemoembolization (TACE) in hepatocellular carcinoma (HCC): the role of angiogenesis and invasiveness. Am J Gastroenterol 2008;103:914–921. Available at: http://www.ncbi.nlm.nih.gov/pubmed/18177453.

400. Xiong ZP, Yang SR, Liang ZY, et al. Association between vascular endothelial growth factor and metastasis after transcatheter arterial chemoembolization in patients with hepatocellular carcinoma. Hepatobiliary Pancreat Dis Int 2004;3:386–390. Available at: http://www.ncbi.nlm.nih.gov/pubmed/15313674.

401. Song BC, Chung YH, Kim JA, et al. Association between insulin-like growth factor-2 and metastases after transcatheter arterial chemoembolization in patients with hepatocellular carcinoma: a prospective study. Cancer 2001;91:2386–2393. Available at: http://www.ncbi.nlm.nih.gov/pubmed/11413529.

402. Kudo M, Imanaka K, Chida N, et al. Phase III study of sorafenib after transarterial chemoembolisation in Japanese and Korean patients with unresectable hepatocellular carcinoma. Eur J Cancer 2011;47:2117–2127. Available at: http://www.ncbi.nlm.nih.gov/pubmed/21664811.

403. Erhardt A, Kolligs F, Dollinger M, et al. TACE plus sorafenib for the treatment of hepatocellular carcinoma: results of the multicenter, phase II SOCRATES trial. Cancer Chemother Pharmacol 2014;74:947–954. Available at: https://www.ncbi.nlm.nih.gov/pubmed/25173458.

404. Pawlik TM, Reyes DK, Cosgrove D, et al. Phase II trial of sorafenib combined with concurrent transarterial chemoembolization with drug-eluting beads for hepatocellular carcinoma. J Clin Oncol 2011;29 3960–3967. Available at: http://www.ncbi.nlm.nih.gov/pubmed/21911714.

405. Park J-W, Koh YH, Kim HB, et al. Phase II study of concurrent transarterial chemoembolization and sorafenib in patients with unresectable hepatocellular carcinoma. J Hepatol 2012;56:1336–1342. Available at: http://www.ncbi.nlm.nih.gov/pubmed/22314421.

406. Chung Y-H, Han G, Yoon J-H, et al. Interim analysis of START: study in Asia of the combination of TACE (transcatheter arterial chemoembolization) with sorafenib in patients with hepatocellular carcinoma trial. Int J Cancer 2013;132:2448–2458. Available at: http://www.ncbi.nlm.nih.gov/pubmed/23129123.

407. Zhu K, Chen J, Lai L, et al. Hepatocellular carcinoma with portal vein tumor thrombus: treatment with transarterial chemoembolization combined with sorafenib--a retrospective controlled study. Radiology 2014;272:284–293. Available at: http://www.ncbi.nlm.nih.gov/pubmed/24708192.

408. Zhao Y, Wang WJ, Guan S, et al. Sorafenib combined with transarterial chemoembolization for the treatment of advanced hepatocellular carcinoma: a large-scale multicenter study of 222 patients. Ann Oncol 2013;24:1786–1792. Available at: http://www.ncbi.nlm.nih.gov/pubmed/23508822.

409. Lencioni R, Llovet JM, Han G, et al. Sorafenib or placebo plus TACE with doxorubicin-eluting beads for intermediate stage HCC: the SPACE trial. J Hepatol 2016;64:1090–1098. Available at: https://www.ncbi.nlm.nih.gov/pubmed/26809111.

Version 2.2025 © 2025 National Comprehensive Cancer Network© (NCCN©), All rights reserved. NCCN Guidelines® and this illustration may not be reproduced in any form without the express written permission of NCCN.

PLEASE NOTE that use of this NCCN Content is governed by the End-User License Agreement, and you MAY NOT distribute this Content or use it with any artificial intelligence model or tool.
Printed by Galya Basol Kochav on 1/5/2026 10:54:24 AM. Copyright © 2026 National Comprehensive Cancer Network, Inc. All Rights Reserved.

410. Poon RT, Tso WK, Pang RW, et al. A phase I/II trial of chemoembolization for hepatocellular carcinoma using a novel intra-arterial drug-eluting bead. Clin Gastroenterol Hepatol 2007;5:1100–1108. Available at: http://www.ncbi.nlm.nih.gov/pubmed/17627902.

411. Reyes DK, Vossen JA, Kamel IR, et al. Single-center phase II trial of transarterial chemoembolization with drug-eluting beads for patients with unresectable hepatocellular carcinoma: initial experience in the United States. Cancer J 2009;15:526–532. Available at: http://www.ncbi.nlm.nih.gov/pubmed/20010173.

412. Lammer J, Malagari K, Vogl T, et al. Prospective randomized study of doxorubicin-eluting-bead embolization in the treatment of hepatocellular carcinoma: results of the PRECISION V study. Cardiovasc Intervent Radiol 2010;33:41–52. Available at: http://www.ncbi.nlm.nih.gov/pubmed/19908093.

413. Malagari K, Pomoni M, Kelekis A, et al. Prospective randomized comparison of chemoembolization with doxorubicin-eluting beads and bland embolization with BeadBlock for hepatocellular carcinoma. Cardiovasc Intervent Radiol 2010;33:541–551. Available at: http://www.ncbi.nlm.nih.gov/pubmed/19937027.

414. Dhanasekaran R, Kooby DA, Staley CA, et al. Comparison of conventional transarterial chemoembolization (TACE) and chemoembolization with doxorubicin drug eluting beads (DEB) for unresectable hepatocelluar carcinoma (HCC). J Surg Oncol 2010;101:476–480. Available at: http://www.ncbi.nlm.nih.gov/pubmed/20213741.

415. Malagari K, Pomoni M, Moschouris H, et al. Chemoembolization with doxorubicin-eluting beads for unresectable hepatocellular carcinoma: five-year survival analysis. Cardiovasc Intervent Radiol 2012;35:1119–1128. Available at: https://www.ncbi.nlm.nih.gov/pubmed/22614031.

416. Song MJ, Chun HJ, Song do S, et al. Comparative study between doxorubicin-eluting beads and conventional transarterial chemoembolization for treatment of hepatocellular carcinoma. J Hepatol 2012;57:1244–1250. Available at: http://www.ncbi.nlm.nih.gov/pubmed/22824821.

417. Golfieri R, Giampalma E, Renzulli M, et al. Randomised controlled trial of doxorubicin-eluting beads vs conventional chemoembolisation for hepatocellular carcinoma. Br J Cancer 2014;111:255–264. Available at: http://www.ncbi.nlm.nih.gov/pubmed/24937669.

418. Yang B, Liang J, Qu Z, et al. Transarterial strategies for the treatment of unresectable hepatocellular carcinoma: A systematic review. PLoS One 2020;15:e0227475. Available at: https://www.ncbi.nlm.nih.gov/pubmed/32074102.

419. Chao Y, Chung YH, Han G, et al. The combination of transcatheter arterial chemoembolization and sorafenib is well tolerated and effective in Asian patients with hepatocellular carcinoma: final results of the START trial. Int J Cancer 2015;136:1458–1467. Available at: https://www.ncbi.nlm.nih.gov/pubmed/25099027.

420. Cai R, Song R, Pang P, et al. Transcatheter arterial chemoembolization plus sorafenib versus transcatheter arterial chemoembolization alone to treat advanced hepatocellular carcinoma: a meta-analysis. BMC Cancer 2017;17:714. Available at: https://www.ncbi.nlm.nih.gov/pubmed/29110700.

421. Jin PP, Shao SY, Wu WT, et al. Combination of transarterial chemoembolization and sorafenib improves outcomes of unresectable hepatocellular carcinoma: an updated systematic review and meta-analysis. Jpn J Clin Oncol 2018;48:1058–1069. Available at: https://www.ncbi.nlm.nih.gov/pubmed/30272196.

422. Li L, Zhao W, Wang M, et al. Transarterial chemoembolization plus sorafenib for the management of unresectable hepatocellular carcinoma: a systematic review and meta-analysis. BMC Gastroenterol 2018;18:138. Available at: https://www.ncbi.nlm.nih.gov/pubmed/30180810.

423. Meyer T, Fox R, Ma YT, et al. Sorafenib in combination with transarterial chemoembolisation in patients with unresectable hepatocellular carcinoma (TACE 2): a randomised placebo-controlled,

Version 2.2025 © 2025 National Comprehensive Cancer Network© (NCCN©), All rights reserved. NCCN Guidelines® and this illustration may not be reproduced in any form without the express written permission of NCCN.

PLEASE NOTE that use of this NCCN Content is governed by the End-User License Agreement, and you MAY NOT distribute this Content or use it with any artificial intelligence model or tool.
Printed by Galya Basol Kochav on 1/5/2026 10:54:24 AM. Copyright © 2026 National Comprehensive Cancer Network, Inc. All Rights Reserved.

double-blind, phase 3 trial. Lancet Gastroenterol Hepatol 2017;2:565–575. Available at: https://www.ncbi.nlm.nih.gov/pubmed/28648803.

424. Sangro B, Kudo M, Erinjeri JP, et al. Durvalumab with or without bevacizumab with transarterial chemoembolisation in hepatocellular carcinoma (EMERALD-1): A multiregional, randomised, double-blind, placebo-controlled, phase 3 study. Lancet 2025;405:216–232. Available at: https://www.ncbi.nlm.nih.gov/pubmed/39798579.

425. Fan W, Zhu B, Chen S, et al. Survival in patients with recurrent intermediate-stage hepatocellular carcinoma: sorafenib plus TACE vs TACE alone randomized clinical trial. JAMA Oncol 2024;10:1047–1054. Available at: https://www.ncbi.nlm.nih.gov/pubmed/38900435.

426. Peng Z, Fan W, Zhu B, et al. Lenvatinib combined with transarterial chemoembolization as first-Line treatment for advanced hepatocellular carcinoma: A phase III, randomized clinical trial (LAUNCH). J Clin Oncol 2023;41:117–127. Available at: https://www.ncbi.nlm.nih.gov/pubmed/35921605.

427. Ding X, Sun W, Li W, et al. Transarterial chemoembolization plus lenvatinib versus transarterial chemoembolization plus sorafenib as first-line treatment for hepatocellular carcinoma with portal vein tumor thrombus: A prospective randomized study. Cancer 2021;127:3782–3793. Available at: https://www.ncbi.nlm.nih.gov/pubmed/34237154.

428. Ibrahim SM, Lewandowski RJ, Sato KT, et al. Radioembolization for the treatment of unresectable hepatocellular carcinoma: a clinical review. World J Gastroenterol 2008;14:1664–1669. Available at: http://www.ncbi.nlm.nih.gov/pubmed/18350597.

429. Salem R, Johnson GE, Kim E, et al. Yttrium-90 radioembolization for the treatment of solitary, unresectable HCC: The LEGACY study. Hepatology 2021;74:2342–2352. Available at: https://www.ncbi.nlm.nih.gov/pubmed/33739462.

430. Kulik LM, Carr BI, Mulcahy MF, et al. Safety and efficacy of 90Y radiotherapy for hepatocellular carcinoma with and without portal vein thrombosis. Hepatology 2008;47:71–81. Available at: http://www.ncbi.nlm.nih.gov/pubmed/18027884.

431. Woodall CE, Scoggins CR, Ellis SF, et al. Is selective internal radioembolization safe and effective for patients with inoperable hepatocellular carcinoma and venous thrombosis? J Am Coll Surg 2009;208:375–382. Available at: http://www.ncbi.nlm.nih.gov/pubmed/19317999.

432. Salem R, Lewandowski RJ, Mulcahy MF, et al. Radioembolization for hepatocellular carcinoma using Yttrium-90 microspheres: a comprehensive report of long-term outcomes. Gastroenterology 2010;138:52–64. Available at: http://www.ncbi.nlm.nih.gov/pubmed/19766639.

433. Sangro B, Carpanese L, Cianni R, et al. Survival after yttrium-90 resin microsphere radioembolization of hepatocellular carcinoma across Barcelona clinic liver cancer stages: a European evaluation. Hepatology 2011;54:868–878. Available at: http://www.ncbi.nlm.nih.gov/pubmed/21618574.

434. Mazzaferro V, Sposito C, Bhoori S, et al. Yttrium-90 radioembolization for intermediate-advanced hepatocellular carcinoma: a phase 2 study. Hepatology 2013;57:1826–1837. Available at: http://www.ncbi.nlm.nih.gov/pubmed/22911442.

435. Vouche M, Habib A, Ward TJ, et al. Unresectable solitary hepatocellular carcinoma not amenable to radiofrequency ablation: multicenter radiology-pathology correlation and survival of radiation segmentectomy. Hepatology 2014;60:192–201. Available at: http://www.ncbi.nlm.nih.gov/pubmed/24691943.

436. Abdel-Rahman OM, Elsayed Z. Yttrium-90 microsphere radioembolisation for unresectable hepatocellular carcinoma. Cochrane Database Syst Rev 2016;2:CD011313. Available at: https://www.ncbi.nlm.nih.gov/pubmed/26905230.

437. Garin E, Tselikas L, Guiu B, et al. Personalised versus standard dosimetry approach of selective internal radiation therapy in patients with

Version 2.2025 © 2025 National Comprehensive Cancer Network© (NCCN©), All rights reserved. NCCN Guidelines® and this illustration may not be reproduced in any form without the express written permission of NCCN.

PLEASE NOTE that use of this NCCN Content is governed by the End-User License Agreement, and you MAY NOT distribute this Content or use it with any artificial intelligence model or tool.
Printed by Galya Basol Kochav on 1/5/2026 10:54:24 AM. Copyright © 2026 National Comprehensive Cancer Network, Inc. All Rights Reserved.

locally advanced hepatocellular carcinoma (DOSISPHERE-01): a randomised, multicentre, open-label phase 2 trial. Lancet Gastroenterol Hepatol 2021;6:17–29. Available at: https://www.ncbi.nlm.nih.gov/pubmed/33166497.

438. Gabr A, Riaz A, Johnson GE, et al. Correlation of Y90-absorbed radiation dose to pathological necrosis in hepatocellular carcinoma: Confirmatory multicenter analysis in 45 explants. Eur J Nucl Med Mol Imaging 2021;48:580–583. Available at: https://www.ncbi.nlm.nih.gov/pubmed/32749512.

439. De la Garza-Ramos C, Overfield CJ, Montazeri SA, et al. Biochemical safety of ablative yttrium-90 radioembolization for hepatocellular carcinoma as a function of percent liver treated. J Hepatocell Carcinoma 2021;8:861–870. Available at: https://www.ncbi.nlm.nih.gov/pubmed/34368021.

440. Serhal M, Dadrass F, Kim E, Lewandowski RJ. Radiation segmentectomy for hepatocellular carcinoma. Curr Oncol 2024;31:617–628. Available at: https://www.ncbi.nlm.nih.gov/pubmed/38392039.

441. Kim E, Sher A, Abboud G, et al. Radiation segmentectomy for curative intent of unresectable very early to early stage hepatocellular carcinoma (RASER): A single-centre, single-arm study. Lancet Gastroenterol Hepatol 2022;7:843–850. Available at: https://www.ncbi.nlm.nih.gov/pubmed/35617978.

442. Lewandowski RJ, Gabr A, Abouchaleh N, et al. Radiation segmentectomy: Potential curative therapy for early hepatocellular carcinoma. Radiology 2018;287:1050–1058. Available at: https://www.ncbi.nlm.nih.gov/pubmed/29688155.

443. Vilgrain V, Pereira H, Assenat E, et al. Efficacy and safety of selective internal radiotherapy with yttrium-90 resin microspheres compared with sorafenib in locally advanced and inoperable hepatocellular carcinoma (SARAH): an open-label randomised controlled phase 3 trial. Lancet Oncol 2017;18:1624–1636. Available at: https://www.ncbi.nlm.nih.gov/pubmed/29107679.

444. Chow PKH, Gandhi M, Tan SB, et al. SIRveNIB: Selective internal radiation therapy versus sorafenib in Asia-Pacific patients with hepatocellular carcinoma. J Clin Oncol 2018;36:1913–1921. Available at: https://www.ncbi.nlm.nih.gov/pubmed/29498924.

445. Atassi B, Bangash AK, Bahrani A, et al. Multimodality imaging following 90Y radioembolization: a comprehensive review and pictorial essay. Radiographics 2008;28:81–99. Available at: http://www.ncbi.nlm.nih.gov/pubmed/18203932.

446. Jia Z, Jiang G, Tian F, et al. A systematic review on the safety and effectiveness of yttrium-90 radioembolization for hepatocellular carcinoma with portal vein tumor thrombosis. Saudi J Gastroenterol 2016;22:353–359. Available at: https://www.ncbi.nlm.nih.gov/pubmed/27748320.

447. Lobo L, Yakoub D, Picado O, et al. Unresectable hepatocellular carcinoma: radioembolization versus chemoembolization: a systematic review and meta-analysis. Cardiovasc Intervent Radiol 2016;39:1580–1588. Available at: https://www.ncbi.nlm.nih.gov/pubmed/27586657.

448. Salem R, Gordon AC, Mouli S, et al. Y90 radioembolization significantly prolongs time to progression compared with chemoembolization in patients with hepatocellular carcinoma. Gastroenterology 2016;151:1155–1163.e1152. Available at: https://www.ncbi.nlm.nih.gov/pubmed/27575820.

449. Ludwig JM, Zhang D, Xing M, Kim HS. Meta-analysis: adjusted indirect comparison of drug-eluting bead transarterial chemoembolization versus (90)Y-radioembolization for hepatocellular carcinoma. Eur Radiol 2017;27:2031–2041. Available at: https://www.ncbi.nlm.nih.gov/pubmed/27562480.

450. Dhondt E, Lambert B, Hermie L, et al. (90)Y radioembolization versus drug-eluting bead chemoembolization for unresectable hepatocellular carcinoma: Results from the TRACE phase II randomized controlled trial. Radiology 2022;303:699–710. Available at: https://www.ncbi.nlm.nih.gov/pubmed/35258371.

Version 2.2025 © 2025 National Comprehensive Cancer Network© (NCCN©), All rights reserved. NCCN Guidelines® and this illustration may not be reproduced in any form without the express written permission of NCCN.

PLEASE NOTE that use of this NCCN Content is governed by the End-User License Agreement, and you MAY NOT distribute this Content or use it with any artificial intelligence model or tool.
Printed by Galya Basol Kochav on 1/5/2026 10:54:24 AM. Copyright © 2026 National Comprehensive Cancer Network, Inc. All Rights Reserved.

451. Hawkins MA, Dawson LA. Radiation therapy for hepatocellular carcinoma: from palliation to cure. Cancer 2006;106:1653–1663. Available at: http://www.ncbi.nlm.nih.gov/pubmed/16541431.

452. Hoffe SE, Finkelstein SE, Russell MS, Shridhar R. Nonsurgical options for hepatocellular carcinoma: evolving role of external beam radiotherapy. Cancer Control 2010;17:100–110. Available at: http://www.ncbi.nlm.nih.gov/pubmed/20404793.

453. Kwon JH, Bae SH, Kim JY, et al. Long-term effect of stereotactic body radiation therapy for primary hepatocellular carcinoma ineligible for local ablation therapy or surgical resection. Stereotactic radiotherapy for liver cancer. BMC Cancer 2010;10:475–475. Available at: http://www.ncbi.nlm.nih.gov/pubmed/20813065.

454. Andolino DL, Johnson CS, Maluccio M, et al. Stereotactic body radiotherapy for primary hepatocellular carcinoma. Int J Radiat Oncol Biol Phys 2011;81:e447–453. Available at: http://www.ncbi.nlm.nih.gov/pubmed/21645977.

455. Huang W-Y, Jen Y-M, Lee M-S, et al. Stereotactic body radiation therapy in recurrent hepatocellular carcinoma. Int J Radiat Oncol Biol Phys 2012;84:355–361. Available at: http://www.ncbi.nlm.nih.gov/pubmed/22342300.

456. Kang J-K, Kim M-S, Cho CK, et al. Stereotactic body radiation therapy for inoperable hepatocellular carcinoma as a local salvage treatment after incomplete transarterial chemoembolization. Cancer 2012;118:5424–5431. Available at: http://www.ncbi.nlm.nih.gov/pubmed/22570179.

457. Bujold A, Massey CA, Kim JJ, et al. Sequential phase I and II trials of stereotactic body radiotherapy for locally advanced hepatocellular carcinoma. J Clin Oncol 2013;31:1631–1639. Available at: http://www.ncbi.nlm.nih.gov/pubmed/23547075.

458. Wahl DR, Stenmark MH, Tao Y, et al. Outcomes after stereotactic body radiotherapy or radiofrequency ablation for hepatocellular carcinoma. J Clin Oncol 2016;34:452–459. Available at: https://www.ncbi.nlm.nih.gov/pubmed/26628466.

459. Rajyaguru DJ, Borgert AJ, Smith AL, et al. Radiofrequency ablation versus stereotactic body radiotherapy for localized hepatocellular carcinoma in nonsurgically managed patients: analysis of the National Cancer Database. J Clin Oncol 2018;36:600–608. Available at: https://www.ncbi.nlm.nih.gov/pubmed/29328861.

460. Facciuto ME, Singh MK, Rochon C, et al. Stereotactic body radiation therapy in hepatocellular carcinoma and cirrhosis: evaluation of radiological and pathological response. J Surg Oncol 2012;105:692–698. Available at: http://www.ncbi.nlm.nih.gov/pubmed/21960321.

461. Katz AW, Chawla S, Qu Z, et al. Stereotactic hypofractionated radiation therapy as a bridge to transplantation for hepatocellular carcinoma: clinical outcome and pathologic correlation. Int J Radiat Oncol Biol Phys 2012;83:895–900. Available at: http://www.ncbi.nlm.nih.gov/pubmed/22172906.

462. O'Connor JK, Trotter J, Davis GL, et al. Long-term outcomes of stereotactic body radiation therapy in the treatment of hepatocellular cancer as a bridge to transplantation. Liver Transpl 2012;18:949–954. Available at: http://www.ncbi.nlm.nih.gov/pubmed/22467602.

463. Apisarnthanarax S, Barry A, Cao M, et al. External beam radiation therapy for primary liver cancers: An ASTRO Clinical Practice Guideline. Pract Radiat Oncol 2022;12:28–51. Available at: https://www.ncbi.nlm.nih.gov/pubmed/34688956.

464. Hong TS, Wo JY, Yeap BY, et al. Multi-institutional phase II study of high-dose hypofractionated proton beam therapy in patients with localized, unresectable hepatocellular carcinoma and intrahepatic cholangiocarcinoma. J Clin Oncol 2016;34:460–468. Available at: https://www.ncbi.nlm.nih.gov/pubmed/26668346.

465. Seong J, Lee IJ, Shim SJ, et al. A multicenter retrospective cohort study of practice patterns and clinical outcome on radiotherapy for

Version 2.2025 © 2025 National Comprehensive Cancer Network© (NCCN©), All rights reserved. NCCN Guidelines® and this illustration may not be reproduced in any form without the express written permission of NCCN.

PLEASE NOTE that use of this NCCN Content is governed by the End-User License Agreement, and you MAY NOT distribute this Content or use it with any artificial intelligence model or tool.
Printed by Galya Basol Kochav on 1/5/2026 10:54:24 AM. Copyright © 2026 National Comprehensive Cancer Network, Inc. All Rights Reserved.

hepatocellular carcinoma in Korea. Liver Int 2009;29:147–152. Available at: https://www.ncbi.nlm.nih.gov/pubmed/18795897.

466. Ben-Josef E, Lawrence TS. Radiotherapy for unresectable hepatic malignancies. Semin Radiat Oncol 2005;15:273–278. Available at: https://www.ncbi.nlm.nih.gov/pubmed/16183481.

467. Tse RV, Hawkins M, Lockwood G, et al. Phase I study of individualized stereotactic body radiotherapy for hepatocellular carcinoma and intrahepatic cholangiocarcinoma. J Clin Oncol 2008;26:657–664. Available at: http://www.ncbi.nlm.nih.gov/pubmed/18172187.

468. Cardenes HR, Price TR, Perkins SM, et al. Phase I feasibility trial of stereotactic body radiation therapy for primary hepatocellular carcinoma. Clin Transl Oncol 2010;12:218–225. Available at: http://www.ncbi.nlm.nih.gov/pubmed/20231127.

469. Tanguturi SK, Wo JY, Zhu AX, et al. Radiation therapy for liver tumors: ready for inclusion in guidelines? Oncologist 2014;19:868–879. Available at: https://www.ncbi.nlm.nih.gov/pubmed/25001265.

470. Bush DA, Volk M, Smith JC, et al. Proton beam radiotherapy versus transarterial chemoembolization for hepatocellular carcinoma: Results of a randomized clinical trial. Cancer 2023;129:3554–3563. Available at: https://www.ncbi.nlm.nih.gov/pubmed/37503907.

471. Parzen JS, Hartsell W, Chang J, et al. Hypofractionated proton beam radiotherapy in patients with unresectable liver tumors: Multi-institutional prospective results from the Proton Collaborative Group. Radiat Oncol 2020;15:255. Available at: https://www.ncbi.nlm.nih.gov/pubmed/33148296.

472. Proton beam therapy model policy. 2023. Available at: https://www.astro.org/ASTRO/media/ASTRO/Daily%20Practice/PDFs/ASTROPBTModelPolicy.pdf. Accessed January 13, 2025.

473. Qi WX, Fu S, Zhang Q, Guo XM. Charged particle therapy versus photon therapy for patients with hepatocellular carcinoma: a systematic review and meta-analysis. Radiother Oncol 2015;114:289–295. Available at: https://www.ncbi.nlm.nih.gov/pubmed/25497556.

474. Sanford NN, Pursley J, Noe B, et al. Protons versus photons for unresectable hepatocellular carcinoma: Liver decompensation and overall survival. Int J Radiat Oncol Biol Phys 2019;105:64–72. Available at: https://www.ncbi.nlm.nih.gov/pubmed/30684667.

475. Yu JI, Yoo GS, Cho S, et al. Initial clinical outcomes of proton beam radiotherapy for hepatocellular carcinoma. Radiat Oncol J 2018;36:25–34. Available at: https://www.ncbi.nlm.nih.gov/pubmed/29580046.

476. Kim TH, Park JW, Kim BH, et al. Phase II study of hypofractionated proton beam therapy for hepatocellular carcinoma. Front Oncol 2020;10:542. Available at: https://www.ncbi.nlm.nih.gov/pubmed/32411594.

477. Kim TH, Koh YH, Kim BH, et al. Proton beam radiotherapy vs. radiofrequency ablation for recurrent hepatocellular carcinoma: A randomized phase III trial. J Hepatol 2021;74:603–612. Available at: https://www.ncbi.nlm.nih.gov/pubmed/33031846.

478. Dawson LA, Winter KA, Knox JJ, et al. Stereotactic body radiotherapy vs sorafenib alone in hepatocellular carcinoma: The NRG oncology/RTOG 1112 phase 3 randomized clinical trial. JAMA Oncol 2025;11:136–144. Available at: https://www.ncbi.nlm.nih.gov/pubmed/39699905.

479. Kirikoshi H, Saito S, Yoneda M, et al. Outcome of transarterial chemoembolization monotherapy, and in combination with percutaneous ethanol injection, or radiofrequency ablation therapy for hepatocellular carcinoma. Hepatol Res 2009;39:553–562. Available at: http://www.ncbi.nlm.nih.gov/pubmed/19527484.

480. Maluccio M, Covey AM, Gandhi R, et al. Comparison of survival rates after bland arterial embolization and ablation versus surgical resection for treating solitary hepatocellular carcinoma up to 7 cm. J Vasc Interv Radiol 2005;16:955–961. Available at: http://www.ncbi.nlm.nih.gov/pubmed/16002503.

Version 2.2025 © 2025 National Comprehensive Cancer Network© (NCCN©), All rights reserved. NCCN Guidelines® and this illustration may not be reproduced in any form without the express written permission of NCCN.

PLEASE NOTE that use of this NCCN Content is governed by the End-User License Agreement, and you MAY NOT distribute this Content or use it with any artificial intelligence model or tool.
Printed by Galya Basol Kochav on 1/5/2026 10:54:24 AM. Copyright © 2026 National Comprehensive Cancer Network, Inc. All Rights Reserved.

481. Elnekave E, Erinjeri JP, Brown KT, et al. Long-term outcomes comparing surgery to embolization-ablation for treatment of solitary HCC <7 cm. Ann Surg Oncol 2013;20:2881–2886. Available at: http://www.ncbi.nlm.nih.gov/pubmed/23563960.

482. Koda M, Murawaki Y, Mitsuda A, et al. Combination therapy with transcatheter arterial chemoembolization and percutaneous ethanol injection compared with percutaneous ethanol injection alone for patients with small hepatocellular carcinoma: a randomized control study. Cancer 2001;92:1516–1524. Available at: http://www.ncbi.nlm.nih.gov/pubmed/11745230.

483. Becker G, Soezgen T, Olschewski M, et al. Combined TACE and PEI for palliative treatment of unresectable hepatocellular carcinoma. World J Gastroenterol 2005;11:6104–6109. Available at: http://www.ncbi.nlm.nih.gov/pubmed/16273634.

484. Peng Z-W, Zhang Y-J, Chen M-S, et al. Radiofrequency ablation with or without transcatheter arterial chemoembolization in the treatment of hepatocellular carcinoma: a prospective randomized trial. J Clin Oncol 2013;31:426–432. Available at: http://www.ncbi.nlm.nih.gov/pubmed/23269991.

485. Shibata T, Isoda H, Hirokawa Y, et al. Small hepatocellular carcinoma: is radiofrequency ablation combined with transcatheter arterial chemoembolization more effective than radiofrequency ablation alone for treatment? Radiology 2009;252:905–913. Available at: http://radiology.rsna.org/content/252/3/905.full.pdf.

486. Kim JH, Won HJ, Shin YM, et al. Medium-sized (3.1-5.0 cm) hepatocellular carcinoma: transarterial chemoembolization plus radiofrequency ablation versus radiofrequency ablation alone. Ann Surg Oncol 2011;18:1624–1629. Available at: http://www.ncbi.nlm.nih.gov/pubmed/21445671.

487. Peng ZW, Zhang YJ, Liang HH, et al. Recurrent hepatocellular carcinoma treated with sequential transcatheter arterial chemoembolization and RF ablation versus RF ablation alone: a prospective randomized trial. Radiology 2012;262:689–700. Available at: http://www.ncbi.nlm.nih.gov/pubmed/22157201.

488. Sheta E, El-Kalla F, El-Gharib M, et al. Comparison of single-session transarterial chemoembolization combined with microwave ablation or radiofrequency ablation in the treatment of hepatocellular carcinoma: a randomized-controlled study. Eur J Gastroenterol Hepatol 2016;28:1198–1203. Available at: https://www.ncbi.nlm.nih.gov/pubmed/27362551.

489. Zaitoun MMA, Elsayed SB, Zaitoun NA, et al. Combined therapy with conventional trans-arterial chemoembolization (cTACE) and microwave ablation (MWA) for hepatocellular carcinoma >3-<5 cm. Int J Hyperthermia 2021;38:248–256. Available at: https://www.ncbi.nlm.nih.gov/pubmed/33615957.

490. Wang W, Shi J, Xie WF. Transarterial chemoembolization in combination with percutaneous ablation therapy in unresectable hepatocellular carcinoma: a meta-analysis. Liver Int 2010;30:741–749. Available at: http://www.ncbi.nlm.nih.gov/pubmed/20331507.

491. Huo YR, Eslick GD. Transcatheter arterial chemoembolization plus radiotherapy compared with chemoembolization alone for hepatocellular carcinoma: a systematic review and meta-analysis. JAMA Oncol 2015;1:756–765. Available at: https://www.ncbi.nlm.nih.gov/pubmed/26182200.

492. Abdel-Rahman O, Elsayed Z. External beam radiotherapy for unresectable hepatocellular carcinoma. Cochrane Database Syst Rev 2017;3:CD011314. Available at: https://www.ncbi.nlm.nih.gov/pubmed/28267205.

493. Yoon SM, Ryoo BY, Lee SJ, et al. Efficacy and safety of transarterial chemoembolization plus external beam radiotherapy vs sorafenib in hepatocellular carcinoma with macroscopic vascular invasion: a randomized clinical trial. JAMA Oncol 2018;4:661–669. Available at: https://www.ncbi.nlm.nih.gov/pubmed/29543938.

494. Llovet JM, Vilana R, Bru C, et al. Increased risk of tumor seeding after percutaneous radiofrequency ablation for single hepatocellular

Version 2.2025 © 2025 National Comprehensive Cancer Network© (NCCN©), All rights reserved. NCCN Guidelines® and this illustration may not be reproduced in any form without the express written permission of NCCN.

PLEASE NOTE that use of this NCCN Content is governed by the End-User License Agreement, and you MAY NOT distribute this Content or use it with any artificial intelligence model or tool.
Printed by Galya Basol Kochav on 1/5/2026 10:54:24 AM. Copyright © 2026 National Comprehensive Cancer Network, Inc. All Rights Reserved.

carcinoma. Hepatology 2001;33:1124–1129. Available at: http://www.ncbi.nlm.nih.gov/pubmed/11343240.

495. Livraghi T, Solbiati L, Meloni MF, et al. Treatment of focal liver tumors with percutaneous radio-frequency ablation: complications encountered in a multicenter study. Radiology 2003;226:441–451. Available at: http://www.ncbi.nlm.nih.gov/pubmed/12563138.

496. Lencioni R, Cioni D, Crocetti L, et al. Early-stage hepatocellular carcinoma in patients with cirrhosis: long-term results of percutaneous image-guided radiofrequency ablation. Radiology 2005;234:961–967. Available at: http://www.ncbi.nlm.nih.gov/pubmed/15665226.

497. Zhang Y-J, Liang H-H, Chen M-S, et al. Hepatocellular carcinoma treated with radiofrequency ablation with or without ethanol injection: a prospective randomized trial. Radiology 2007;244:599–607. Available at: http://www.ncbi.nlm.nih.gov/pubmed/17641378.

498. Soliman H, Ringash J, Jiang H, et al. Phase II trial of palliative radiotherapy for hepatocellular carcinoma and liver metastases. J Clin Oncol 2013;31:3980–3986. Available at: http://www.ncbi.nlm.nih.gov/pubmed/24062394.

499. Zhu AX, Blaszkowsky LS, Ryan DP, et al. Phase II study of gemcitabine and oxaliplatin in combination with bevacizumab in patients with advanced hepatocellular carcinoma. J Clin Oncol 2006;24:1898–1903. Available at: http://www.ncbi.nlm.nih.gov/pubmed/16622265.

500. Siegel AB, Cohen EI, Ocean A, et al. Phase II trial evaluating the clinical and biologic effects of bevacizumab in unresectable hepatocellular carcinoma. J Clin Oncol 2008;26:2992–2998. Available at: http://www.ncbi.nlm.nih.gov/pubmed/18565886.

501. Thomas MB, Morris JS, Chadha R, et al. Phase II trial of the combination of bevacizumab and erlotinib in patients who have advanced hepatocellular carcinoma. J Clin Oncol 2009;27:843–850. Available at: http://www.ncbi.nlm.nih.gov/pubmed/19139433.

502. Hsu CH, Yang TS, Hsu C, et al. Efficacy and tolerability of bevacizumab plus capecitabine as first-line therapy in patients with advanced hepatocellular carcinoma. Br J Cancer 2010;102:981–986. Available at: http://www.ncbi.nlm.nih.gov/pubmed/20160718.

503. Sun W, Sohal D, Haller DG, et al. Phase 2 trial of bevacizumab, capecitabine, and oxaliplatin in treatment of advanced hepatocellular carcinoma. Cancer 2011;117:3187–3192. Available at: http://www.ncbi.nlm.nih.gov/pubmed/21264839.

504. Fang P, Hu JH, Cheng ZG, et al. Efficacy and safety of bevacizumab for the treatment of advanced hepatocellular carcinoma: a systematic review of phase II trials. PLoS One 2012;7:e49717. Available at: https://www.ncbi.nlm.nih.gov/pubmed/23284624.

505. Finn RS, Qin S, Ikeda M, et al. Atezolizumab plus bevacizumab in unresectable hepatocellular carcinoma. N Engl J Med 2020;382:1894–1905. Available at: https://www.ncbi.nlm.nih.gov/pubmed/32402160.

506. Cheng AL, Qin S, Ikeda M, et al. Updated efficacy and safety data from IMbrave150: Atezolizumab plus bevacizumab vs. sorafenib for unresectable hepatocellular carcinoma. J Hepatol 2022;76:862–873. Available at: https://www.ncbi.nlm.nih.gov/pubmed/34902530.

507. D'Alessio A, Fulgenzi CAM, Nishida N, et al. Preliminary evidence of safety and tolerability of atezolizumab plus bevacizumab in patients with hepatocellular carcinoma and Child-Pugh A and B cirrhosis: A real-world study. Hepatology 2022;76:1000–1012. Available at: https://www.ncbi.nlm.nih.gov/pubmed/35313048.

508. Fulgenzi CAM, Scheiner B, D'Alessio A, et al. Immunotherapy vs best supportive care for patients with hepatocellular cancer with Child-Pugh B dysfunction. JAMA Oncol 2024;10:1253–1258. Available at: https://www.ncbi.nlm.nih.gov/pubmed/39023864.

509. Rimassa L, Chan SL, Sangro B, et al. Five-year overall survival update from the HIMALAYA study of tremelimumab plus durvalumab in unresectable HCC. J Hepatol 2025. Available at: https://www.ncbi.nlm.nih.gov/pubmed/40222621.

Version 2.2025 © 2025 National Comprehensive Cancer Network© (NCCN©), All rights reserved. NCCN Guidelines® and this illustration may not be reproduced in any form without the express written permission of NCCN.

PLEASE NOTE that use of this NCCN Content is governed by the End-User License Agreement, and you MAY NOT distribute this Content or use it with any artificial intelligence model or tool.
Printed by Galya Basol Kochav on 1/5/2026 10:54:24 AM. Copyright © 2026 National Comprehensive Cancer Network, Inc. All Rights Reserved.

510. Kudo M, Finn RS, Qin S, et al. Lenvatinib versus sorafenib in first-line treatment of patients with unresectable hepatocellular carcinoma: a randomised phase 3 non-inferiority trial. Lancet 2018;391:1163–1173. Available at: https://www.ncbi.nlm.nih.gov/pubmed/29433850.

511. Llovet JM, Ricci S, Mazzaferro V, et al. Sorafenib in advanced hepatocellular carcinoma. N Engl J Med 2008;359:378–390. Available at: http://www.ncbi.nlm.nih.gov/pubmed/18650514.

512. Cheng AL, Kang YK, Chen Z, et al. Efficacy and safety of sorafenib in patients in the Asia-Pacific region with advanced hepatocellular carcinoma: a phase III randomised, double-blind, placebo-controlled trial. Lancet Oncol 2009;10:25–34. Available at: http://www.ncbi.nlm.nih.gov/pubmed/19095497.

513. Abou-Alfa GK. Selection of patients with hepatocellular carcinoma for sorafenib. J Natl Compr Canc Netw 2009;7:397–403. Available at: http://www.ncbi.nlm.nih.gov/pubmed/19406040.

514. Finn RS, Zhu AX, Farah W, et al. Therapies for advanced stage hepatocellular carcinoma with macrovascular invasion or metastatic disease: A systematic review and meta-analysis. Hepatology 2018;67:422–435. Available at: https://www.ncbi.nlm.nih.gov/pubmed/28881497.

515. Abou-Alfa GK, Schwartz L, Ricci S, et al. Phase II study of sorafenib in patients with advanced hepatocellular carcinoma. J Clin Oncol 2006;24:4293–4300. Available at: http://www.ncbi.nlm.nih.gov/pubmed/16908937.

516. Abou-Alfa GK, Amadori D, Santoro A, et al. Safety and efficacy of sorafenib in patients with hepatocellular carcinoma (HCC) and Child-Pugh A versus B cirrhosis. Gastrointest Cancer Res 2011;4:40–44. Available at: http://www.ncbi.nlm.nih.gov/pubmed/21673874.

517. Pinter M, Sieghart W, Hucke F, et al. Prognostic factors in patients with advanced hepatocellular carcinoma treated with sorafenib. Aliment Pharmacol Ther 2011;34:949–959. Available at: http://www.ncbi.nlm.nih.gov/pubmed/21883324.

518. Hollebecque A, Cattan S, Romano O, et al. Safety and efficacy of sorafenib in hepatocellular carcinoma: the impact of the Child-Pugh score. Aliment Pharmacol Ther 2011;34:1193–1201. Available at: http://www.ncbi.nlm.nih.gov/pubmed/21958438.

519. Kim JE, Ryoo BY, Ryu MH, et al. Sorafenib for hepatocellular carcinoma according to Child-Pugh class of liver function. Cancer Chemother Pharmacol 2011;68:1285–1290. Available at: http://www.ncbi.nlm.nih.gov/pubmed/21445543.

520. Lencioni R, Kudo M, Ye SL, et al. First interim analysis of the GIDEON (Global Investigation of therapeutic decisions in hepatocellular carcinoma and of its treatment with sorafeNib) non-interventional study. Int J Clin Pract 2012;66:675–683. Available at: http://www.ncbi.nlm.nih.gov/pubmed/22698419.

521. Chiu J, Tang YF, Yao T-J, et al. The use of single-agent sorafenib in the treatment of advanced hepatocellular carcinoma patients with underlying Child-Pugh B liver cirrhosis: a retrospective analysis of efficacy, safety, and survival benefits. Cancer 2012;118:5293–5301. Available at: http://www.ncbi.nlm.nih.gov/pubmed/22517493.

522. Marrero JA, Kudo M, Venook AP, et al. Observational registry of sorafenib use in clinical practice across Child-Pugh subgroups: The GIDEON study. J Hepatol 2016;65:1140–1147. Available at: https://www.ncbi.nlm.nih.gov/pubmed/27469901.

523. Miller AA, Murry DJ, Owzar K, et al. Phase I and pharmacokinetic study of sorafenib in patients with hepatic or renal dysfunction: CALGB 60301. J Clin Oncol 2009;27:1800–1805. Available at: http://www.ncbi.nlm.nih.gov/pubmed/19255312.

524. Zhu AX, Rosmorduc O, Evans TR, et al. SEARCH: a phase III, randomized, double-blind, placebo-controlled trial of sorafenib plus erlotinib in patients with advanced hepatocellular carcinoma. J Clin Oncol 2015;33:559–566. Available at: http://www.ncbi.nlm.nih.gov/pubmed/25547503.

Version 2.2025 © 2025 National Comprehensive Cancer Network© (NCCN©), All rights reserved. NCCN Guidelines® and this illustration may not be reproduced in any form without the express written permission of NCCN.

PLEASE NOTE that use of this NCCN Content is governed by the End-User License Agreement, and you MAY NOT distribute this Content or use it with any artificial intelligence model or tool.
Printed by Galya Basol Kochav on 1/5/2026 10:54:24 AM. Copyright © 2026 National Comprehensive Cancer Network, Inc. All Rights Reserved.

525. Qin S, Kudo M, Meyer T, et al. Tislelizumab vs sorafenib as first-line treatment for unresectable hepatocellular carcinoma: A phase 3 randomized clinical trial. JAMA Oncol 2023;9:1651–1659. Available at: https://www.ncbi.nlm.nih.gov/pubmed/37796513.

526. Yau T, Galle PR, Decaens T, et al. Nivolumab plus ipilimumab versus lenvatinib or sorafenib as first-line treatment for unresectable hepatocellular carcinoma (CheckMate 9DW): An open-label, randomised, phase 3 trial. Lancet 2025;405:1851–1864. Available at: https://www.ncbi.nlm.nih.gov/pubmed/40349714.

527. Verset G, Borbath I, Karwal M, et al. Pembrolizumab monotherapy for previously untreated advanced hepatocellular carcinoma: Data from the open-label, phase II KEYNOTE-224 trial. Clin Cancer Res 2022;28:2547–2554. Available at: https://www.ncbi.nlm.nih.gov/pubmed/35421228.

528. Abou-Alfa GK, Meyer T, Cheng AL, et al. Cabozantinib in patients with advanced and progressing hepatocellular carcinoma. N Engl J Med 2018;379:54–63. Available at: https://www.ncbi.nlm.nih.gov/pubmed/29972759.

529. Kelley RK, Meyer T, Rimassa L, et al. Serum alpha-fetoprotein levels and clinical outcomes in the phase III CELESTIAL study of cabozantinib versus placebo in patients with advanced hepatocellular carcinoma. Clin Cancer Res 2020;26:4795–4804. Available at: https://www.ncbi.nlm.nih.gov/pubmed/32636319.

530. Kelley RK, Miksad R, Cicin I, et al. Efficacy and safety of cabozantinib for patients with advanced hepatocellular carcinoma based on albumin-bilirubin grade. Br J Cancer 2022;126:569–575. Available at: https://www.ncbi.nlm.nih.gov/pubmed/34621044.

531. Melero I, Yau T, Kang YK, et al. Nivolumab plus ipilimumab combination therapy in patients with advanced hepatocellular carcinoma previously treated with sorafenib: 5-year results from CheckMate 040. Ann Oncol 2024;35:537–548. Available at: https://www.ncbi.nlm.nih.gov/pubmed/38844309.

532. Alden SL, Lim M, Kao C, et al. Salvage ipilimumab plus nivolumab after anti-PD-1/PD-L1 therapy in advanced hepatocellular carcinoma. Cancer Res Commun 2023;3:1312–1317. Available at: https://www.ncbi.nlm.nih.gov/pubmed/37484200.

533. Kudo M, Finn RS, Edeline J, et al. Updated efficacy and safety of KEYNOTE-224: A phase II study of pembrolizumab in patients with advanced hepatocellular carcinoma previously treated with sorafenib. Eur J Cancer 2022;167:1–12. Available at: https://www.ncbi.nlm.nih.gov/pubmed/35364421.

534. Merle P, Kudo M, Edeline J, et al. Pembrolizumab as second-line therapy for advanced hepatocellular carcinoma: Longer term follow-up from the phase 3 KEYNOTE-240 trial. Liver Cancer 2023:1–12. Available at: https://doi.org/10.1159/000529636.

535. Zhu AX, Park JO, Ryoo BY, et al. Ramucirumab versus placebo as second-line treatment in patients with advanced hepatocellular carcinoma following first-line therapy with sorafenib (REACH): a randomised, double-blind, multicentre, phase 3 trial. Lancet Oncol 2015;16:859–870. Available at: http://www.ncbi.nlm.nih.gov/pubmed/26095784.

536. Chau I, Peck-Radosavljevic M, Borg C, et al. Ramucirumab as second-line treatment in patients with advanced hepatocellular carcinoma following first-line therapy with sorafenib: Patient-focused outcome results from the randomised phase III REACH study. Eur J Cancer 2017;81:17–25. Available at: https://www.ncbi.nlm.nih.gov/pubmed/28591675.

537. Zhu AX, Kang YK, Yen CJ, et al. Ramucirumab after sorafenib in patients with advanced hepatocellular carcinoma and increased alpha-fetoprotein concentrations (REACH-2): a randomised, double-blind, placebo-controlled, phase 3 trial. Lancet Oncol 2019;20:282–296. Available at: https://www.ncbi.nlm.nih.gov/pubmed/30665869.

538. Zhu AX, Finn RS, Kang YK, et al. Serum alpha-fetoprotein and clinical outcomes in patients with advanced hepatocellular carcinoma treated with ramucirumab. Br J Cancer 2021;124:1388–1397. Available at: https://www.ncbi.nlm.nih.gov/pubmed/33531690.

Version 2.2025 © 2025 National Comprehensive Cancer Network© (NCCN©), All rights reserved. NCCN Guidelines® and this illustration may not be reproduced in any form without the express written permission of NCCN.

PLEASE NOTE that use of this NCCN Content is governed by the End-User License Agreement, and you MAY NOT distribute this Content or use it with any artificial intelligence model or tool.
Printed by Galya Basol Kochav on 1/5/2026 10:54:24 AM. Copyright © 2026 National Comprehensive Cancer Network, Inc. All Rights Reserved.

539. Maesaka K, Sakamori R, Yamada R, et al. Efficacy of ramucirumab versus sorafenib as subsequent treatment for hepatocellular carcinoma. Anticancer Res 2021;41:2187–2192. Available at: https://www.ncbi.nlm.nih.gov/pubmed/33813432.

540. FDA grants accelerated approval to nivolumab for HCC previously treated with sorafenib. 2017. Available at: https://www.fda.gov/drugs/resources-information-approved-drugs/fda-grants-accelerated-approval-nivolumab-hcc-previously-treated-sorafenib. Accessed July 30, 2021.

541. Nivolumab press release. 2021. Available at: https://tinyurl.com/35r6jc35. Accessed July 30, 2021.

542. Kudo M, Matilla A, Santoro A, et al. CheckMate 040 cohort 5: A phase I/II study of nivolumab in patients with advanced hepatocellular carcinoma and Child-Pugh B cirrhosis. J Hepatol 2021;75:600–609. Available at: https://www.ncbi.nlm.nih.gov/pubmed/34051329.

543. Andre T, Berton D, Curigliano G, et al. Antitumor activity and safety of dostarlimab monotherapy in patients with mismatch repair deficient solid tumors: A nonrandomized controlled trial. JAMA Netw Open 2023;6:e2341165. Available at: https://www.ncbi.nlm.nih.gov/pubmed/37917058.

544. Subbiah V, Wolf J, Konda B, et al. Tumour-agnostic efficacy and safety of selpercatinib in patients with RET fusion-positive solid tumours other than lung or thyroid tumours (LIBRETTO-001): A phase 1/2, open-label, basket trial. Lancet Oncol 2022;23:1261–1273. Available at: https://www.ncbi.nlm.nih.gov/pubmed/36108661.

545. Drilon A, Laetsch TW, Kummar S, et al. Efficacy of larotrectinib in TRK fusion-positive cancers in adults and children. N Engl J Med 2018;378:731–739. Available at: https://www.ncbi.nlm.nih.gov/pubmed/29466156.

546. Doebele RC, Drilon A, Paz-Ares L, et al. Entrectinib in patients with advanced or metastatic NTRK fusion-positive solid tumours: integrated analysis of three phase 1-2 trials. Lancet Oncol 2020;21:271–282. Available at: https://www.ncbi.nlm.nih.gov/pubmed/31838007.

547. Solomon BJ, Drilon A, Lin JJ, et al. Repotrectinib in patients (pts) with NTRK fusion-positive (NTRK+) advanced solid tumors, including NSCLC: Update from the phase I/II TRIDENT-1 trial [abstract]. Ann Oncol 2023;34:Abstract 1372P. Available at: https://www.annalsofoncology.org/article/S0923-7534(23)03242-8/fulltext.

548. Xie E, Yeo YH, Scheiner B, et al. Immune checkpoint inhibitors for Child-Pugh class B advanced hepatocellular carcinoma: A systematic review and meta-analysis. JAMA Oncol 2023;9:1423–1431. Available at: https://www.ncbi.nlm.nih.gov/pubmed/37615958.

549. Llovet JM, Kudo M, Merle P, et al. Lenvatinib plus pembrolizumab versus lenvatinib plus placebo for advanced hepatocellular carcinoma (LEAP-002): A randomised, double-blind, phase 3 trial. Lancet Oncol 2023;24:1399–1410. Available at: https://www.ncbi.nlm.nih.gov/pubmed/38039993.

550. Finn RS, Kudo M, Merle P, et al. LEAP-002 long-term follow-up: Lenvatinib plus pembrolizumab versus lenvatinib plus placebo for advanced hepatocellular carcinoma [abstract]. J Clin Oncol 2025;43:Abstract 4095. Available at: https://ascopubs.org/doi/10.1200/JCO.2025.43.16_suppl.4095.

551. Cainap C, Qin S, Huang WT, et al. Linifanib versus Sorafenib in patients with advanced hepatocellular carcinoma: results of a randomized phase III trial. J Clin Oncol 2015;33:172–179. Available at: http://www.ncbi.nlm.nih.gov/pubmed/25488963.

552. Rimassa L, Assenat E, Peck-Radosavljevic M, et al. Tivantinib for second-line treatment of MET-high, advanced hepatocellular carcinoma (METIV-HCC): a final analysis of a phase 3, randomised, placebo-controlled study. Lancet Oncol 2018;19:682–693. Available at: https://www.ncbi.nlm.nih.gov/pubmed/29625879.

553. Santoro A, Rimassa L, Borbath I, et al. Tivantinib for second-line treatment of advanced hepatocellular carcinoma: a randomised, placebo-

Version 2.2025 © 2025 National Comprehensive Cancer Network© (NCCN©), All rights reserved. NCCN Guidelines® and this illustration may not be reproduced in any form without the express written permission of NCCN.

PLEASE NOTE that use of this NCCN Content is governed by the End-User License Agreement, and you MAY NOT distribute this Content or use it with any artificial intelligence model or tool.
Printed by Galya Basol Kochav on 1/5/2026 10:54:24 AM. Copyright © 2026 National Comprehensive Cancer Network, Inc. All Rights Reserved.

controlled phase 2 study. Lancet Oncol 2013;14:55–63. Available at: https://www.ncbi.nlm.nih.gov/pubmed/23182627.

554. Kang YK, Yau T, Park JW, et al. Randomized phase II study of axitinib versus placebo plus best supportive care in second-line treatment of advanced hepatocellular carcinoma. Ann Oncol 2015;26:2457–2463. Available at: https://www.ncbi.nlm.nih.gov/pubmed/26386123.

555. Qin S, Li Q, Gu S, et al. Apatinib as second-line or later therapy in patients with advanced hepatocellular carcinoma (AHELP): A multicentre, double-blind, randomised, placebo-controlled, phase 3 trial. Lancet Gastroenterol Hepatol 2021;6:559–568. Available at: https://www.ncbi.nlm.nih.gov/pubmed/33971141.

556. Yau T, Zagonel V, Santoro A, et al. Nivolumab plus cabozantinib with or without ipilimumab for advanced hepatocellular carcinoma: Results from cohort 6 of the CheckMate 040 trial. J Clin Oncol 2023;41:1747–1757. Available at: https://www.ncbi.nlm.nih.gov/pubmed/36512738.

557. Lee JH, Shin DH, Park WY, et al. IDH1 R132C mutation is detected in clear cell hepatocellular carcinoma by pyrosequencing. World J Surg Oncol 2017;15:82. Available at: https://www.ncbi.nlm.nih.gov/pubmed/28403884.

558. El-Khoueiry AB, Sangro B, Yau T, et al. Nivolumab in patients with advanced hepatocellular carcinoma (CheckMate 040): an open-label, non-comparative, phase 1/2 dose escalation and expansion trial. Lancet 2017;389:2492–2502. Available at: https://www.ncbi.nlm.nih.gov/pubmed/28434648.

559. Lee MS, Ryoo BY, Hsu CH, et al. Atezolizumab with or without bevacizumab in unresectable hepatocellular carcinoma (GO30140): An open-label, multicentre, phase 1b study. Lancet Oncol 2020;21:808–820. Available at: https://www.ncbi.nlm.nih.gov/pubmed/32502443.

560. Liu H, Wang ZG, Fu SY, et al. Randomized clinical trial of chemoembolization plus radiofrequency ablation versus partial hepatectomy for hepatocellular carcinoma within the Milan criteria. Br J Surg 2016;103:348–356. Available at: https://www.ncbi.nlm.nih.gov/pubmed/26780107.

561. Hyun MH, Lee YS, Kim JH, et al. Hepatic resection compared to chemoembolization in intermediate- to advanced-stage hepatocellular carcinoma: A meta-analysis of high-quality studies. Hepatology 2018;68:977–993. Available at: https://www.ncbi.nlm.nih.gov/pubmed/29543988.

562. Volk ML, Hernandez JC, Lok AS, Marrero JA. Modified Charlson comorbidity index for predicting survival after liver transplantation. Liver Transpl 2007;13:1515–1520. Available at: http://www.ncbi.nlm.nih.gov/pubmed/17969207.

563. Utsunomiya T, Shimada M, Kudo M, et al. Nationwide study of 4741 patients with non-B non-C hepatocellular carcinoma with special reference to the therapeutic impact. Ann Surg 2014;259:336–345. Available at: http://www.ncbi.nlm.nih.gov/pubmed/23673768.

564. Heimbach JK. Evolution of liver transplant selection criteria and U.S. allocation policy for patients with hepatocellular carcinoma. Semin Liver Dis 2020;40:358–364. Available at: https://www.ncbi.nlm.nih.gov/pubmed/32942324.

565. Rudnick SR, Russo MW. Liver transplantation beyond or downstaging within the Milan criteria for hepatocellular carcinoma. Expert Rev Gastroenterol Hepatol 2018;12:265–275. Available at: https://www.ncbi.nlm.nih.gov/pubmed/29231769.

566. EASL-EORTC clinical practice guidelines: management of hepatocellular carcinoma. J Hepatol 2012;56:908–943. Available at: https://www.ncbi.nlm.nih.gov/pubmed/22424438.

567. Roayaie S, Blume IN, Thung SN, et al. A system of classifying microvascular invasion to predict outcome after resection in patients with hepatocellular carcinoma. Gastroenterology 2009;137:850–855. Available at: https://www.ncbi.nlm.nih.gov/pubmed/19524573.

Version 2.2025 © 2025 National Comprehensive Cancer Network© (NCCN©), All rights reserved. NCCN Guidelines® and this illustration may not be reproduced in any form without the express written permission of NCCN.

PLEASE NOTE that use of this NCCN Content is governed by the End-User License Agreement, and you MAY NOT distribute this Content or use it with any artificial intelligence model or tool.
Printed by Galya Basol Kochav on 1/5/2026 10:54:24 AM. Copyright © 2026 National Comprehensive Cancer Network, Inc. All Rights Reserved.

568. Sumie S, Nakashima O, Okuda K, et al. The significance of classifying microvascular invasion in patients with hepatocellular carcinoma. Ann Surg Oncol 2014;21:1002–1009. Available at: https://www.ncbi.nlm.nih.gov/pubmed/24254204.

569. Park H, Park JY. Clinical significance of AFP and PIVKA-II responses for monitoring treatment outcomes and predicting prognosis in patients with hepatocellular carcinoma. Biomed Res Int 2013;2013:310427. Available at: https://www.ncbi.nlm.nih.gov/pubmed/24455683.

570. Figueras J, Ibanez L, Ramos E, et al. Selection criteria for liver transplantation in early-stage hepatocellular carcinoma with cirrhosis: results of a multicenter study. Liver Transpl 2001;7:877–883. Available at: https://www.ncbi.nlm.nih.gov/pubmed/11679986.

571. Kudo M, Okusaka T, Motomura K, et al. Ramucirumab after prior sorafenib in patients with advanced hepatocellular carcinoma and elevated alpha-fetoprotein: Japanese subgroup analysis of the REACH-2 trial. J Gastroenterol 2020;55:627–639. Available at: https://www.ncbi.nlm.nih.gov/pubmed/32107609.

Version 2.2025 © 2025 National Comprehensive Cancer Network© (NCCN©), All rights reserved. NCCN Guidelines® and this illustration may not be reproduced in any form without the express written permission of NCCN.